INSIGHTS-JOURNAL OF
HEALTH AND REHABILITATION

INSIGHTS-JHR
INSIGHTS-JOURNAL OF HEALTH AND REHABILITATION

COMPARISON OF EYE AXIAL LENGTH AMONG YOUNG AND OLD HEALTHY VOLUNTEERS MEASURED ON TRANSORBITAL ULTRASOUND

Original Research

Maria Yaseen[1]*, Shaista Bibi[2], Aiman Naeem[2], Khadija Irshad[2], Ayesha Shahid[2], Aks-E-Qamar[2], Muqadas Tufail[2], Saba Ajmal[1]*, Ahmad Bilal[1]

[1]Lecturer, Institute of Health Sciences, Khwaja Fareed University of Engineering and Information Technology, Rahim Yar Khan , Pakistan.

[2]Bachelor of Science in Radiography and Imaging Technology, Institute of Health Sciences, Khwaja Fareed University of Engineering and Information Technology, Pakistan.

Corresponding Author: Maria Yaseen, Lecturer, Institute of Health Sciences, Khwaja Fareed University of Engineering and Information Technology, Rahim Yar Khan, Pakistan, mariayaseen666@gmail.com

Saba Ajmal, Lecturer, Institute of Health Sciences, Khwaja Fareed University of Engineering and Information Technology, Rahim Yar Khan, Pakistan, sabaajmal8@gmail.com

Acknowledgement: The authors gratefully acknowledge the cooperation of all study participants and the technical support provided by Fatima Medical Lab, Rahim Yar Khan.

Conflict of Interest: None

Grant Support & Financial Support: None

ABSTRACT

Background: Transorbital ultrasonography is a non-invasive, accessible, and effective imaging modality for ocular biometry, particularly valuable for measuring axial length—the distance from the anterior corneal surface to the inner retinal layer. Accurate axial length measurement is crucial for calculating intraocular lens (IOL) power, especially in cataract surgery. Establishing normative values across age groups is essential for both diagnostic accuracy and surgical outcomes in ophthalmic care.

Objective: To compare the axial length of the eye between young and older healthy adult volunteers using transorbital ultrasonography.

Methods: This comparative cross-sectional study was conducted from January to April 2025 at Fatima Medical Lab, Rahim Yar Khan. A total of 50 healthy participants (100 eyes), including 27 males (54%) and 23 females (46%), were recruited and divided into two age groups: Group 1 (20–40 years) and Group 2 (41–60 years), with 25 participants in each group. Eye axial length was measured using a 9–12 MHz linear transducer on a GE S6 ultrasound system. Each eye was scanned three times, and the average value was recorded. Data were analyzed using SPSS version 2025. Independent sample t-tests were applied, and p-values <0.05 were considered statistically significant.

Results: The participants had a mean age of 38.92 ± 11.22 years. The overall mean right eye axial length was 23.05 ± 1.4 mm, and the left eye axial length was 23.06 ± 1.6 mm. In Group 1, the right eye axial length averaged 23.40 ± 1.2 mm compared to 22.80 ± 1.3 mm in Group 2 ($p = 0.121$). The left eye measurements were 24.09 ± 1.0 mm and 23.90 ± 1.2 mm for Groups 1 and 2, respectively ($p = 0.558$), indicating no statistically significant difference.

Conclusion: This study demonstrates that axial length, as measured by transorbital ultrasonography, shows no significant variation between young and older healthy adults, suggesting it remains relatively stable across adulthood in the absence of ocular or systemic pathology.

Keywords: Adult, Eye Axial Length, Healthy Volunteers, Intraocular Biometry, Transorbital Sonography, Ultrasonography, Visual Acuity Measurements.

© 2025 et al. Open access under CC BY License (Creative Commons). Freely distributable with appropriate citation.



INTRODUCTION

Vision loss and age-related eye diseases represent a significant global public health concern, particularly affecting the aging population (1). The most frequent causes of vision impairment include age-related ocular conditions and uncorrected refractive errors. Among these, cataract, age-related macular degeneration (AMD), open-angle glaucoma, and diabetic retinopathy (DR) are highly prevalent, especially among individuals over 75 years of age, as demonstrated in multiple epidemiological studies (2). These conditions not only impair vision but also contribute substantially to the psychological burden experienced by older adults, particularly those aged 65 and above, by diminishing their independence and overall quality of life (3). The psychosocial effects of vision loss can include depression, anxiety, and reduced social participation, underscoring the importance of early detection and appropriate management. As people age, physiological changes within the eye compound the effects of disease. Older adults often experience difficulty in focusing at varying distances due to reduced elasticity of the lens, a change that typically begins around the age of 50. This leads to slower accommodation and increased visual blurring, particularly for nearby objects (4,5). In the context of cataract surgery, precise intraocular lens (IOL) power estimation is vital for optimal postoperative visual outcomes and patient satisfaction (6). To achieve such precision, ocular imaging plays a central role. Owing to the superficial anatomical position and cystic nature of the eye, high-frequency ultrasonography is ideally suited for ocular imaging, offering a rapid, non-invasive, and cost-effective diagnostic option with minimal contraindications compared to magnetic resonance imaging (MRI), particularly in patients with implanted electronic devices like pacemakers (7,8).

Sonographic assessment of the eye has become a standard practice, especially in cases where direct visualization through funduscopy or slit-lamp examination is limited. Traditional ultrasound devices can provide detailed cross-sectional images of the globe, while specialized ultrasound biomicroscopy is necessary to visualize anterior segment structures (8–10). Furthermore, A-mode and color Doppler sonography are valuable tools in the evaluation of intraocular masses and vascular features (11). Optical axial length, defined as the distance from the corneal surface to the internal limiting membrane of the retina, is a critical parameter in ocular biometry. This length increases from approximately 16.5 mm at birth to about 23.75 mm in early adulthood, after which it is generally believed to remain stable unless influenced by pathological myopic progression (12–14). However, emerging evidence suggests that axial length may gradually decline with age, a phenomenon that has not been thoroughly investigated and may have implications for presbyopia and other age-related refractive changes (15,16). Given the diagnostic utility and safety profile of sonographic techniques, evaluating axial length using transorbital ultrasonography offers a promising approach to studying ocular changes associated with aging. Despite its clinical relevance, there is a lack of comprehensive normative data comparing axial length between young and older individuals using this modality. Therefore, the present study aims to assess age-related differences in ocular axial length by comparing sonographic measurements in young and elderly participants. Additionally, the research seeks to establish a reference range for normal eye axial length across age groups, providing a foundation for future clinical applications and research.

METHODS

This comparative cross-sectional study was conducted over a period of three months, from January 2025 to April 2025, following formal approval from the institutional ethical review committee. A total of fifty healthy adult volunteers were enrolled through convenience sampling and stratified into two age groups: 20–40 years and 41–60 years. All participants provided written informed consent prior to inclusion in the study. Inclusion criteria required subjects to be healthy individuals without any known ocular pathology, prior eye surgery, or systemic conditions that might affect ocular morphology. Individuals with a history of refractive surgeries, ocular trauma, or active eye infections were excluded to minimize confounding variables. Data collection was carried out at Fatima Medical Lab, Rahim Yar Khan. Each participant was positioned in the supine position with 20–30° elevation of the head and neck to minimize pressure on the orbit and to ensure relaxation of the extraocular muscles. Participants were instructed to keep their eyes gently closed and steady in the neutral position, avoiding any ocular movements during the procedure. Ocular ultrasonography was performed using a 9–12 MHz linear transducer attached to a GE S6 ultrasound system. After application of coupling gel on the closed upper eyelid, the transducer was gently placed on the eyelid, directed towards the temporal side, allowing optimal visualization of the globe in transverse section. The image was frozen when the maximum transverse diameter of the eyeball was displayed, ensuring alignment of the scan with the visual axis.

© 2025 et al. Open access under CC BY License (Creative Commons). Freely distributable with appropriate citation.

INSIGHTS-JHR
INSIGHTS-JOURNAL OF HEALTH AND REHABILITATION

Axial length measurements were obtained in B-mode, defined as the distance from the peak of the anterior corneal surface to the peak of the macular retinal surface. The built-in electronic caliper system was used for these measurements. For accuracy, three independent readings were taken per eye, and the mean value was recorded as the final axial length. Data were entered and analyzed using SPSS version 2025. Quantitative variables such as age and axial length were expressed as mean ± standard deviation (SD), while categorical variables such as gender were summarized using frequencies and percentages. An independent sample t-test was applied to compare the mean axial length between the two age groups, with a p-value of less than 0.05 considered statistically significant.

RESULTS

The study included 50 healthy adult participants, comprising 27 males (54.0%) and 23 females (46.0%). Participants were categorized into two age groups: Group 1 (young adults, 20–40 years) and Group 2 (older adults, 41–60 years), with 25 individuals in each group. The mean age of participants was 38.92 ± 11.22 years, with the minimum age being 20 years and the maximum 60 years. The axial length of the right eye (REAL) in the young group had a mean of 23.41 ± 1.22 mm, whereas the older group had a slightly lower mean of 22.83 ± 1.36 mm. Despite this difference, the independent sample t-test revealed no statistically significant difference between the two groups ($t = 1.578$, $p = 0.121$), and Levene's test confirmed the assumption of equal variances ($F = 0.979$, $p = 0.328$). For the left eye axial length (LEAL), the young group exhibited a mean of 24.10 ± 1.01 mm, while the older group had a mean of 23.91 ± 1.22 mm. Again, no statistically significant difference was observed between the two age groups ($t = 0.590$, $p = 0.558$), with equality of variances validated by Levene's test ($F = 1.093$, $p = 0.301$). The findings indicate that while axial length values were marginally higher in the younger group for both eyes, the differences did not reach statistical significance. Overall, axial length remained relatively stable across the age span of 20 to 60 years. To support the study's objective of establishing normative axial length values, the combined mean of both eyes was calculated for each age group and the overall sample. In the young group (20–40 years), the average axial length across both eyes was 23.75 ± 0.49 mm, while in the older group (41–60 years), it was 23.37 ± 0.76 mm. When considering all participants collectively, the mean axial length across both eyes was 23.56 ± 0.57 mm. These values provide a practical reference for normal ocular axial length in adults aged 20 to 60 years, with minimal inter-eye variability observed within each group.

© 2025 et al. Open access under CC BY License (Creative Commons). Freely distributable with appropriate citation.

Table 1: Descriptive Statistics of Participants' Age

N	**Valid**	**50**
		0
Missing		
Mean		38.9200
Std. Deviation		11.21923
Minimum		20.00
Maximum		60.00

Table 2: Gender Distribution of Study Participants

Male	**27**	**54.0%**
Female	23	46.0%

Table 3: Comparison of Right Eye Axial Length Between Age Groups

Group	N			Mean	Std. Deviation	Std. Error Mean
REAL		Young	25	23.4068	1.21948	.24390
		old	25	22.8300	1.36152	.27230

Table 4: Independent Samples t-Test for Right Eye Axial Length Between Age Groups

		Levene's Test for Equality of Variances		t-test for Equality of Means						
		F	Sig.	t	df	Sig. (2-tailed)	Mean Difference	Std. Error Difference	95% Confidence Interval of the Difference	
									Lower	Upper
REAL	Equal variances assumed	.979	.328	1.578	48	.121	.57680	.36556	-.15821	1.3118
	Equal variances not assumed			1.578	47.429	.121	.57680	.36556	-.15844	1.3120

Table 5: Comparison of Left Eye Axial Length Between Age Groups

Group	N			Mean	Std.Deviation	Std.ErrorMean
LEAL		Young	25	24.0956	1.01292	.20258
		old	25	23.9084	1.22206	.24441

© 2025 et al. Open access under CC BY License (Creative Commons). Freely distributable with appropriate citation.

Table 6: Independent Samples t-Test for Left Eye Axial Length Between Age Groups

		Levene's Test for Equality of Variances		t-test for Equality of Means						
		F	Sig.	t	df	Sig. (2-tailed)	Mean Difference	Std. Error Difference	95% Confidence Interval of the Difference	
									Lower	Upper
LEAL	Equal variances assumed	1.093	.301	.590	48	.558	.18720	.31745	-.45108	.82548
	Equal variances not assumed			.590	46.40	.558	.18720	.31745	-.45165	.82606

Table 7: The Combined Mean and Standard Deviation of Axial Length (Both Eyes) Across Each Age Group and The Total Sample

Group	Mean Axial Length (Both Eyes)	SD Axial Length (Both Eyes)
Young	23.75 mm	0.49 mm
Old	23.37 mm	0.76 mm
Combined	23.56 mm	0.57 mm

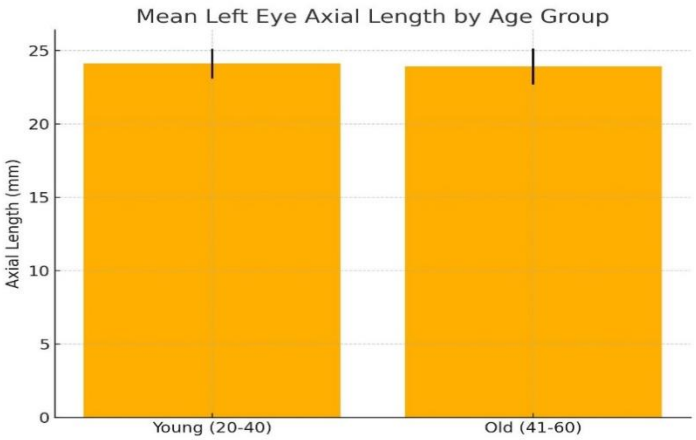

Figure 1 Mean Left Eye Axial Length by Age Group

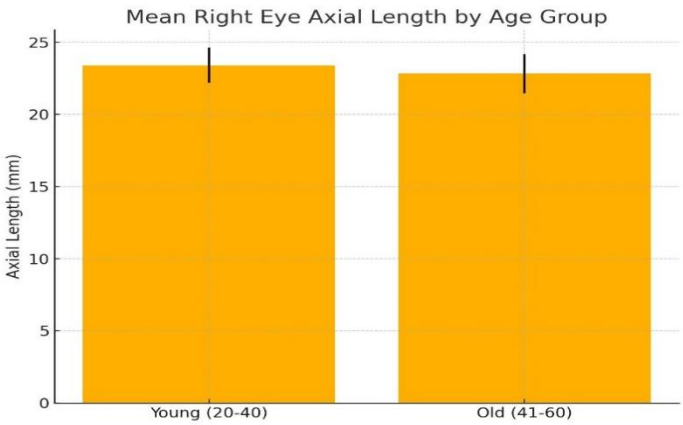

Figure 2 Mean Right Eye Axial Length by Age Group

DISCUSSION

The current study explored age-related differences in ocular axial length among healthy adults using transorbital ultrasonography, focusing on establishing normative reference values and assessing the significance of variation across age groups. The imaging of the eye through ultrasound proved to be a valuable, cost-effective, and readily accessible method for repeated assessments, especially in bedside or outpatient settings. Ultrasound's ability to detect subtle structural variations in the eye offers great potential for early detection of ocular or systemic disease impacts, even in asymptomatic individuals. Participants were categorized into two age groups (20–40 and 41–60 years), and no statistically significant difference in the axial length of the right or left eye was observed between these groups. The mean axial length for the right and left eyes across all participants was relatively consistent, indicating that age within the studied range may not significantly influence axial elongation or shortening in the absence of systemic or ocular disease. The findings support the notion that axial length remains stable during mid-adulthood in a healthy population, aligning with certain previous literature that reported minor or no significant changes in axial length within this age bracket (16,17). However, conflicting evidence from prior

© 2025 et al. Open access under CC BY License (Creative Commons). Freely distributable with appropriate citation.

INSIGHTS-JHR
INSIGHTS-JOURNAL OF HEALTH AND REHABILITATION

research has shown varied outcomes. One study reported a consistent increase in axial length with age, estimating a change of approximately 0.011 mm per year in older populations (18). Other population-based studies have documented not only a gradual decline in axial length but also reductions in anterior chamber depth and vitreous chamber depth, accompanied by an increase in lens thickness and corneal flattening with age (19,20). These variations may be attributed to differences in population demographics, imaging techniques (MRI vs. ultrasound vs. optical biometry), or broader age ranges, particularly including individuals beyond the age of 60, where age-related ocular remodeling becomes more pronounced.

The strength of the present study lies in its use of non-invasive and portable ultrasonographic imaging, which is suitable for diverse clinical settings. Furthermore, the study contributes valuable baseline data on axial length among adults in a South Asian context, where region-specific biometric data remain limited. However, some limitations must be acknowledged. The sample size was relatively modest, and the study did not extend to participants over 60 years of age, a group in which age-related ocular changes are typically more evident. Additionally, the exclusion of biometric parameters such as lens thickness, anterior chamber depth, and corneal curvature limits the scope of anatomical interpretation. Future studies are encouraged to employ multimodal imaging approaches, including A-scan ultrasonography and optical coherence biometry, and to include wider age ranges, particularly elderly populations. Longitudinal designs would further strengthen the understanding of how axial length and related ocular parameters evolve over time. Including systemic health variables, such as hypertension or diabetes, could also provide insight into their subclinical impact on ocular structure. Expanding such research would not only aid in refining intraocular lens power calculations but also enhance the early detection of age-related ocular pathologies.

CONCLUSION

This comparative study concludes that axial length, as measured through transorbital ultrasonography, remains relatively stable across adulthood in healthy individuals. The absence of significant variation between younger and older age groups suggests that age alone may not substantially influence axial elongation in the absence of ocular or systemic pathology. These findings contribute valuable baseline data for clinical reference and may enhance the precision of biometric assessments in optometry and ophthalmology. The study lays a foundation for future research aimed at understanding ocular structural changes and improving diagnostic and surgical planning in adult eye care.

AUTHOR CONTRIBUTION

Author	Contribution
Maria Yaseen*	Substantial Contribution to study design, analysis, acquisition of Data Manuscript Writing Has given Final Approval of the version to be published
Shaista Bibi	Substantial Contribution to study design, acquisition and interpretation of Data Critical Review and Manuscript Writing Has given Final Approval of the version to be published
Aiman Naeem	Substantial Contribution to acquisition and interpretation of Data Has given Final Approval of the version to be published
Khadija Irshad	Contributed to Data Collection and Analysis Has given Final Approval of the version to be published
Ayesha Shahid	Contributed to Data Collection and Analysis Has given Final Approval of the version to be published
Aks-E-Qamar	Substantial Contribution to study design and Data Analysis Has given Final Approval of the version to be published
Muqadas Tufail	Contributed to study concept and Data collection Has given Final Approval of the version to be published
Saba Ajmal	Writing - Review & Editing, Assistance with Data Curation
Ahmad Bilal	Writing - Review & Editing, Assistance with Data Curation

© 2025 et al. Open access under CC BY License (Creative Commons). Freely distributable with appropriate citation.

INSIGHTS-JHR
INSIGHTS-JOURNAL OF HEALTH AND REHABILITATION

REFERENCES

1. Nguyen JH, Nguyen-Cuu J, Mamou J, Routledge B, Yee KMP, Sebag J. Vitreous Structure and Visual Function in Myopic Vitreopathy Causing Vision-Degrading Myodesopsia. Am J Ophthalmol. 2021;224:246-53.
2. Berrones D, Rivera-Cortes M, Monroy-Esquivel L, Becerra-Revollo C, Mayorquin-Ruiz M, Velez-Montoya R. Ultrasound-Guided Pars Plana Vitrectomy. Retina. 2023;43(12):2153-6.
3. Chee SP, Weikert MP, Wallace R, De Francesco T, Ahmed I, Fram N, et al. Traumatic cataract with iridodialysis. J Cataract Refract Surg. 2024;50(11):1191-6.
4. Zhu Z, Zou H, Li H, Wu X, Wang Y, Li Z, et al. Repeatability and reproducibility of anterior lens zonule length measurement using ArcScan insight 100 very high-frequency ultrasound. Expert Rev Med Devices. 2023;20(8):703-10.
5. Sayin N, Kocak I, Pehlivanoğlu S, Pekel G, Er A, Bayramoğlu SE, et al. A quantitative sonoelastography evaluation of ocular and periocular elasticity after intravitreal ranibizumab injection. J Fr Ophtalmol. 2023;46(9):1030-8.
6. Kaya P, Özdemir Yalçınsoy K, Özdamar Erol Y. The Presence of Optic Disc Drusen in Eyes with Uveitis. Ocul Immunol Inflamm. 2023;31(8):1700-6.
7. D CP, Dogra A. Posterior microphthalmos with pigmentary retinopathy. BMJ Case Rep. 2020;13(11).
8. Sariyeva Ismayılov A, Aydin Guclu O, Erol HA. Ocular manifestations in hemodialysis patients and short-term changes in ophthalmologic findings. Ther Apher Dial. 2021;25(2):204-10.
9. Xu BY, Friedman DS, Foster PJ, Jiang Y, Porporato N, Pardeshi AA, et al. Ocular Biometric Risk Factors for Progression of Primary Angle Closure Disease: The Zhongshan Angle Closure Prevention Trial. Ophthalmology. 2022;129(3):267-75.
10. Hoerig C, Nguyen JH, Mamou J, Venuat C, Sebag J, Ketterling JA. Machine Independence of Ultrasound-Based Quantification of Vitreous Echodensities. Transl Vis Sci Technol. 2023;12(9):21.
11. Paniagua-Diaz AM, Nguyen JH, Artal P, Gui W, Sebag J. Light Scattering by Vitreous of Humans With Vision Degrading Myodesopsia From Floaters. Invest Ophthalmol Vis Sci. 2024;65(5):20.
12. Yeşiltaş YS, Zhou M, Zabor EC, Oakey Z, Singh N, Sedaghat A, et al. Iris freckle: a distinct entity. Br J Ophthalmol. 2024;108(12):1749-54.
13. Hoerig C, Hoang QV, Mamou J. In-vivo high-frequency quantitative ultrasound-derived parameters of the anterior sclera correlated with level of myopia and presence of staphyloma. Clin Exp Ophthalmol. 2024;52(8):840-52.
14. Sorkin N, Ohri A, Jung H, Haines L, Sorbara L, Mimouni M, et al. Factors affecting central corneal thickness measurement agreement between Scheimpflug imaging and ultrasound pachymetry in keratoconus. Br J Ophthalmol. 2021;105(10):1371-5.
15. Huang Y, Cai Y, Peng MQ, Yi TT. Evaluation of the effect of fluid management on intracranial pressure in patients undergoing laparoscopic gynaecological surgery based on the ratio of the optic nerve sheath diameter to the eyeball transverse diameter as measured by ultrasound: a randomised controlled trial. BMC Anesthesiol. 2024;24(1):319.
16. Drechsler J, Lee A, Maripudi S, Kueny L, Levin MR, Saeedi OJ, et al. Corneal Structural Changes in Congenital Glaucoma. Eye Contact Lens. 2022;48(1):27-32.
17. Tey KY, Wong QY, Dan YS, Tsai ASH, Ting DSW, Ang M, et al. Association of Aberrant Posterior Vitreous Detachment and Pathologic Tractional Forces With Myopic Macular Degeneration. Invest Ophthalmol Vis Sci. 2021;62(7):7.
18. Zhong M, Liu S, Luo J, Zhang Q, Yang Z, Zhang S. Application of lacrimal gland ultrasonography in the evaluation of chronic ocular graft-versus-host-disease. Front Immunol. 2025;16:1490390.
19. Goel R, Shah S, Gupta S, Khullar T, Singh S, Chhabra M, et al. Alterations in retrobulbar haemodynamics in thyroid eye disease. Eye (Lond). 2023;37(17):3682-90.
20. Wiseman SJ, Tatham AJ, Meijboom R, Terrera GM, Hamid C, Doubal FN, Wardlaw JM, Ritchie C, Dhillon B, MacGillivray T. Measuring axial length of the eye from magnetic resonance brain imaging. BMC ophthalmology. 2022 Feb 5;22(1):54.

© 2025 et al. Open access under CC BY License (Creative Commons). Freely distributable with appropriate citation.