INSIGHTS-JOURNAL OF
HEALTH AND REHABILITATION

INSIGHTS-JHR
INSIGHTS-JOURNAL OF HEALTH AND REHABILITATION

FREQUENCY OF DRY SOCKET IN PATIENTS UNDERGOING DENTAL EXTRACTION AT TERTIARY CARE HOSPITAL

Original Research

Gulalai[1], Tahir Ullah Khan[2]*, Adil Yousaf[1], Leuna Haroon[3], Gulfam Ali[1]

[1]Postgraduate Resident, Department of Oral and Maxillofacial Surgery, Lady Reading Hospital, Peshawar, Pakistan.

[2]Associate Professor, Department of Oral and Maxillofacial Surgery, Lady Reading Hospital, Peshawar, Pakistan.

[3]Postgraduate Resident, Department of Oral and Maxillofacial Surgery, Khyber College of Dentistry, Peshawar, Pakistan.

Corresponding Author: Tahir Ullah Khan, Associate Professor, Department of Oral and Maxillofacial Surgery, Lady Reading Hospital, Peshawar, Pakistan, dr.tahir786@hotmail.com

Acknowledgement: The authors express gratitude to the surgical and administrative staff of the Department of Oral & Maxillofacial Surgery, Lady Reading Hospital, for their support in data collection.

Submission: 05-March-2025 Acceptance: 10-May-2025 Publication: 15-May-2025

Conflict of Interest: None Grant Support & Financial Support: None

ABSTRACT

Background: Dry socket, or alveolar osteitis, is a common yet painful postoperative complication following dental extractions, particularly in mandibular molars. It results from the premature disintegration or loss of the blood clot, exposing the underlying bone and delaying healing. Despite advancements in surgical techniques and patient care, its incidence varies widely due to procedural and patient-related factors. Identifying associated factors is crucial to guiding preventive strategies and reducing patient morbidity in routine dental practice.

Objective: To assess the frequency of dry socket and evaluate associated clinical and behavioral factors in patients undergoing dental extractions at a tertiary care hospital.

Methods: A descriptive study was conducted at the Department of Oral & Maxillofacial Surgery, Lady Reading Hospital, Peshawar, from 28 November 2024 to 28 February 2025. A total of 175 patients aged 18–65 years undergoing mandibular or maxillary extractions and presenting with swelling (VAS > 2), pain (VAS > 3), or gingival bleeding were enrolled through consecutive non-probability sampling. Exclusion criteria included pregnancy, lactation, diabetes, hypertension, and craniofacial anomalies. Extractions were performed under local anesthesia. Dry socket was assessed on the third postoperative day based on VAS score > 4, absence of clot, necrotic debris, and reported bad taste. Data were analyzed using SPSS 26; associations were tested using the Chi-square test with $p < 0.05$ as significant.

Results: The mean age of patients was 40.75 ± 13.64 years, with 100 (57.1%) males and 33 (18.9%) smokers. Dry socket was identified in 10 patients (5.7%). Statistically significant associations were found with smoking ($p = 0.001$), postoperative swelling ($p < 0.0001$), and trismus ($p < 0.0001$). No significant associations were observed with age, gender, residence, or tooth type.

Conclusion: Dry socket remains a notable complication of dental extractions. The findings emphasize the importance of addressing modifiable risk factors, particularly smoking, along with vigilant postoperative care to mitigate the risk of its development.

Keywords: Alveolar osteitis, dental extraction, dry socket, postoperative complications, smoking, swelling, trismus.

© 2025 et al. Open access under CC BY License (Creative Commons). Freely distributable with appropriate citation.

INSIGHTS-JHR
INSIGHTS-JOURNAL OF HEALTH AND REHABILITATION

INTRODUCTION

Dental extractions remain one of the most commonly performed procedures in dental practice, undertaken by practitioners with varying levels of surgical expertise across diverse clinical settings. While the modern emphasis in dentistry is to preserve natural dentition for as long as possible, extractions continue to be essential in managing non-restorable, severely decayed, or periodontally compromised teeth. Ensuring the safe and effective execution of these procedures necessitates a firm understanding of fundamental extraction principles, including the mechanical manipulation required to gradually enlarge the bony socket, promote tooth mobility, and achieve its removal without undue trauma (1–3). Despite being routine, dental extractions are not without risk. One of the most frequently encountered postoperative complications is alveolar osteitis, more commonly known as dry socket. This condition typically arises within the first few days following the procedure and is characterized by the dissolution or dislodgement of the blood clot that normally forms in the socket. As a result, the underlying bone becomes exposed, leading to intense pain that is often refractory to conventional analgesics and may radiate to the ear or neck. The socket may appear empty or covered by a necrotic-looking grayish tissue layer, and patients may present with additional symptoms such as halitosis or regional lymphadenopathy (4,5). The incidence of dry socket is generally around 3%, although this figure may exceed 30% following surgical removal of mandibular third molars, which are considered high-risk extractions (6). A recent study reported a frequency of 5.91% among patients undergoing dental extractions, reinforcing the need for heightened clinical vigilance (7).

Current literature suggests that the principal etiological factors contributing to dry socket include improper or premature dissolution of the post-extraction blood clot, though the precise pathogenesis remains incompletely understood (8-10). This knowledge gap continues to pose a significant challenge for clinicians, particularly as dry socket not only results in considerable discomfort but also delays healing, prolongs recovery time, and increases healthcare resource utilization. Given its prevalence and clinical significance, there is a compelling need to explore the underlying risk factors, prevention strategies, and most effective management options for dry socket. This study, therefore, aims to investigate the incidence and associated risk factors of dry socket following dental extractions, in order to support evidence-based strategies that may minimize its occurrence and enhance postoperative outcomes.

METHODS

This descriptive study was conducted in the Department of Oral and Maxillofacial Surgery at Lady Reading Hospital, Peshawar, over a three-month period from 28th November 2024 to 28th February 2025, following ethical clearance from the Institutional Review Board (IRB). A total of 175 patients undergoing dental extractions were enrolled through a consecutive non-probability sampling method. The sample size was determined based on an anticipated dry socket frequency of 5.91% (10), with a 3.5% margin of error and a 95% confidence interval. The inclusion criteria comprised male and female patients aged 18 to 65 years who presented with jaw pain (Visual Analog Scale [VAS] score > 3), gingival bleeding visible on inspection, and swelling (VAS score > 2), and were undergoing either mandibular or maxillary tooth extractions. Patients were excluded if they were pregnant or lactating, had systemic comorbidities such as hypertension or diabetes, or presented with craniofacial anomalies, to minimize confounding factors that could independently affect postoperative healing. Informed written consent was obtained from all participants prior to their inclusion. All extractions were performed under local anesthesia using lidocaine with adrenaline. When necessary, crown and root sectioning was performed with a straight fissure bur under continuous saline irrigation. Post-extraction care included smoothing of rough bony margins with a bone file, irrigation of the socket with 40 mL of saline, and closure of the wound using vicryl 3/0 sutures. Sterile gauze was applied to the surgical site, and patients were instructed to apply pressure by biting for 30 minutes to encourage clot formation.

Assessment for dry socket was performed on the third postoperative day. A diagnosis of dry socket was established if the patient reported pain with a VAS score > 4, visible absence of a blood clot within the socket, the presence of necrotic debris (identified as discolored tissue in shades of gray, yellow, or black), and a complaint of bad taste. Swelling was reassessed using VAS, with scores > 2 regarded as positive. Trismus was defined by an interincisal distance ≤ 35 mm, measured using a vernier-calibrated sliding caliper. A history of smoking was recorded, defined as any form of tobacco use within the past 30 days. Data analysis was carried out using SPSS version 26. Age was analyzed using means and standard deviations, while categorical variables including gender, dry socket occurrence, tooth

© 2025 et al. Open access under CC BY License (Creative Commons). Freely distributable with appropriate citation.

INSIGHTS-JHR
INSIGHTS-JOURNAL OF HEALTH AND REHABILITATION

type, VAS scores, presence of clot or necrotic debris, swelling, trismus, smoking status, and area of residence were described in terms of frequencies and percentages. To evaluate associations between the occurrence of dry socket and other variables, the Chi-square test was employed, with a p-value < 0.05 considered statistically significant.

RESULTS

The mean age of the 175 patients included in the study was 40.75 ± 13.64 years. Males represented the majority of the sample, accounting for 57.1% (n=100), while females comprised 42.9% (n=75). Slightly more than half of the patients (53.7%) resided in urban areas, with the remaining 46.3% from rural settings. A history of smoking within the past 30 days was reported by 18.9% (n=33) of patients. Clinical evaluation revealed that mandibular tooth extractions were more common, observed in 60.6% (n=106) of cases, compared to maxillary extractions which accounted for 39.4% (n=69). Swelling was present in 20.0% (n=35) of patients, while trismus was identified in 14.9% (n=26). Based on the Visual Analog Scale (VAS), 57.1% (n=100) of patients reported a pain score ≤ 4, whereas 42.9% (n=75) experienced pain with scores > 4. The presence of a visible blood clot within the socket on postoperative assessment was recorded in 5.7% (n=10), and the same proportion exhibited necrotic debris. Dry socket was diagnosed in 5.7% (n=10) of the total study population. Statistical analysis demonstrated that smoking was significantly associated with the occurrence of dry socket, with 60.0% (n=6) of affected individuals reporting a history of tobacco use (P = 0.001). Swelling and trismus were both strongly correlated with dry socket; 90.0% (n=9) of patients with dry socket had swelling, and the same number exhibited trismus, both with P values < 0.0001. A VAS score ≤ 4 was significantly linked to dry socket occurrence (P < 0.0001). No statistically significant associations were found between dry socket and age group, gender, residence area, or tooth location.

Table 1: Demographics

Demographics		N	%
Gender	Male	100	57.1%
	Female	75	42.9%
Residence	Urban	94	53.7%
	Rural	81	46.3%
Smoking	Yes	33	18.9%
	No	142	81.1%

Table 2: Clinical presentation

Clinical presentation		N	%
Tooth type	Mandibular	106	60.6%
	Maxillary	69	39.4%
Swelling	Yes	35	20.0%
	No	140	80.0%
Trismus	Yes	26	14.9%
	No	149	85.1%
VAS score	< = 4	100	57.1%
	> 4	75	42.9%
Clot	Yes	10	5.7%
	No	165	94.3%
Necrotic derris	Yes	10	5.7%
	No	165	94.3%

© 2025 et al. Open access under CC BY License (Creative Commons). Freely distributable with appropriate citation.

INSIGHTS-JHR
INSIGHTS-JOURNAL OF HEALTH AND REHABILITATION

Table 3: Frequency of dry socket

Dry socket	Frequency	Percent
Yes	10	5.7
No	165	94.3
Total	175	100.0

Table 4: Association of dry socket with various parameters

Parameters		Dry socket				P value
		Yes		No		
		N	%	N	%	
Age distribution (Years)	18 to 35	5	50.0%	57	34.5%	0.18
	36 to 50	1	10.0%	64	38.8%	
	51 to 65	4	40.0%	44	26.7%	
Gender	Male	6	60.0%	94	57.0%	0.85
	Female	4	40.0%	71	43.0%	
Residence	Urban	6	60.0%	88	53.3%	0.68
	Rural	4	40.0%	77	46.7%	
Smoking	Yes	6	60.0%	27	16.4%	0.001
	No	4	40.0%	138	83.6%	
Tooth type	Mandibular	8	80.0%	98	59.4%	0.19
	Maxillary	2	20.0%	67	40.6%	
Swelling	Yes	9	90.0%	26	15.8%	0.0001
	No	1	10.0%	139	84.2%	
Trismus	Yes	9	90.0%	17	10.3%	0.0001
	No	1	10.0%	148	89.7%	
VAS score	< = 4	10	100.0%	90	54.5%	0.0001
	> 4	0	0.0%	75	45.5%	

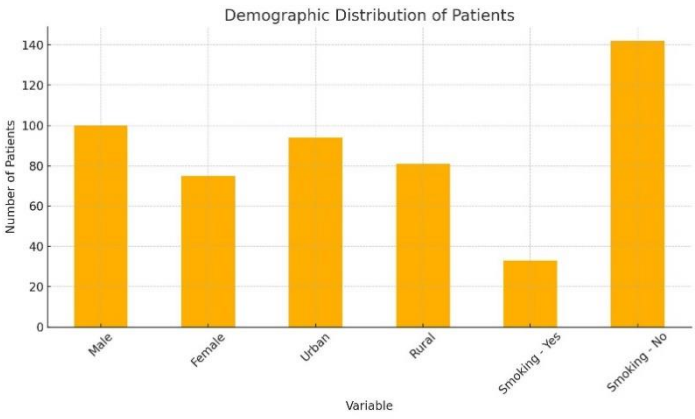

Figure 1 Demographic Distribution of Patients

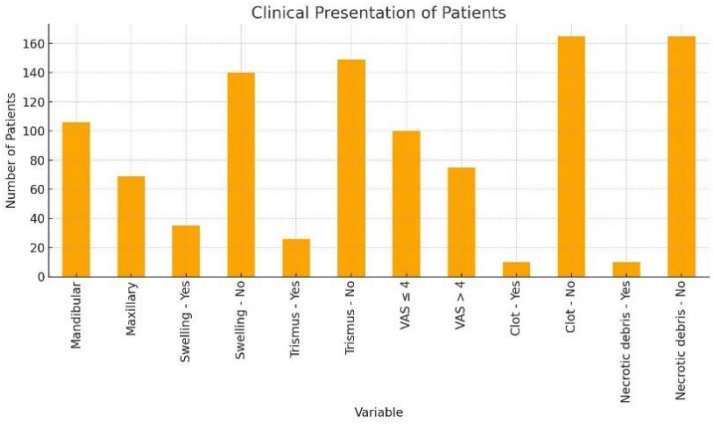

Figure 2 Clinical Presentation of Patients

DISCUSSION

The present study reported a dry socket incidence of 5.7%, which closely aligns with findings from previous local studies that identified similar frequencies, notably around 5.91% (11). However, the incidence of dry socket demonstrates considerable variability across

© 2025 et al. Open access under CC BY License (Creative Commons). Freely distributable with appropriate citation.

different populations and clinical settings, with some studies reporting much higher rates, particularly in cases involving the surgical extraction of mandibular third molars where the prevalence reached up to 41.2% (12). This discrepancy may be attributed to differences in surgical complexity, evaluation timelines, and patient-related factors such as oral hygiene and adherence to postoperative instructions. Notably, in the present study, dry socket was assessed on the third postoperative day, whereas other investigations employed multiple follow-up intervals, potentially influencing detection rates (13). Demographic analysis revealed a mean patient age of 40.75 ± 13.64 years with a slight male predominance, consistent with several regional findings. However, contrasting reports from other institutions observed a higher frequency of dry socket among female patients, reflecting the potential influence of social, cultural, or behavioral factors on healthcare-seeking patterns. Despite the gender imbalance in sample composition, no significant difference in dry socket occurrence was observed between males and females, supporting evidence that gender may not be an independent risk factor (14,15).

Smoking emerged as a significant predictor for the development of dry socket in this study, with a substantially higher incidence among smokers. This finding reinforces previous evidence highlighting tobacco use as a modifiable risk factor due to its vasoconstrictive properties and negative impact on clot stability and wound healing (16,17). The role of alternative forms of tobacco consumption such as snuff dipping, prevalent in some regions, further exacerbates the risk and warrants focused public health interventions. Although some previous studies have not demonstrated a statistically significant relationship between smoking and dry socket, the present data provide robust support for its contributory role (18). Clinical indicators such as swelling, trismus, and elevated pain scores were strongly associated with dry socket, emphasizing their diagnostic relevance in early postoperative assessment. These symptoms may reflect underlying inflammation or infection, which can compromise clot retention and socket healing. Conversely, anatomical factors such as tooth type and the patient's residence did not show significant associations with dry socket incidence in this cohort. While other investigations have reported higher prevalence in mandibular sites or variation across urban and rural populations, the uniformity in surgical protocols and postoperative care in the present study may have minimized the influence of these variables (19,20). This supports the view that procedural factors and patient behaviors may outweigh anatomical or geographical considerations.

Although systemic comorbidities like diabetes were excluded from the study, their potential impact on post-extraction healing and complication rates remains well-documented. Future studies could benefit from exploring these systemic factors through a broader inclusion criterion and multivariate analysis to adjust for potential confounders. One of the key strengths of this study lies in its focus on early clinical assessment using standardized criteria, as well as its emphasis on identifying modifiable risk factors. The use of consistent surgical protocols across patients enhanced the internal validity of findings related to smoking and symptomatology. However, the study also faced limitations, particularly the use of a non-probability sampling technique and the exclusion of systemic comorbidities, which may limit generalizability. The absence of regression analysis to control for confounding factors restricts the interpretability of independent associations. In light of the findings, prioritizing patient counseling regarding smoking cessation before dental extractions appears crucial in reducing the risk of dry socket. Awareness campaigns targeting tobacco use and postoperative oral hygiene should be reinforced through community-based programs and digital health platforms. Future research should incorporate longitudinal follow-ups, broader patient profiles, and advanced statistical modeling to build a comprehensive risk prediction framework for dry socket and to guide preventive strategies.

CONCLUSION

This study highlights that the development of dry socket following dental extractions is notably associated with modifiable risk factors such as smoking, along with postoperative clinical indicators including swelling and trismus. These findings underscore the critical importance of proactive patient education and preoperative counseling, particularly regarding tobacco use, to reduce the risk of complications and improve recovery outcomes. Emphasizing preventive strategies in routine dental practice can significantly enhance patient care and minimize postoperative morbidity linked to dry socket.

© 2025 et al. Open access under CC BY License (Creative Commons). Freely distributable with appropriate citation.

INSIGHTS-JHR
INSIGHTS-JOURNAL OF HEALTH AND REHABILITATION

AUTHOR CONTRIBUTION

Author	Contribution
Gulalai	Data entry & Analysis, Manuscript Writing, Conception of Study Design
Tahir Ullah Khan*	Critical Input, Conception of Study Design, Final Approval of Draft
Adil Yousaf	Critical Input, and Literature review
Leuna Haroon	Critical Input, and Literature review
Gulfam Ali	Critical Input, and Literature review

REFERENCES

1. AlSheef M, Gray J, AlShammari A. Risk of postoperative bleeding following dental extractions in patients on antithrombotic treatment. Saudi Dent J. 2021;33(7):511-7.
2. Huang J, Liu J, Shi H, Wu J, Liu J, Pan J. Risk factors for bleeding after dental extractions in patients receiving antithrombotic drugs-A case control study. J Dent Sci. 2022;17(2):780-6.
3. Arya R, Jadun S, Shah A. An evaluation of patient informed consent for dental extractions. Prim Dent J. 2022;11(3):98-103.
4. Hutor NS. Current diagnosis, prevention and treatment of dry socket:(literature review). Int J Med Res. 2021;7(2):58-65.
5. Kamal A, Omar M, Samsudin AR. Management of Dry Socket: New regenerative techniques emerge while old treatment prevails. Dent Rev. 2022;2(1):100035.
6. Taberner-Vallverdú M, Camps-Font O, Gay-Escoda C, Sánchez-Garcés MA. Previous dry socket as a risk factor for alveolar osteitis: A nested case-control study in primary healthcare services. J Clin Exp Dent. 2022;14(6): e479.
7. Saeed MS, Khan A, Sohail S, Jamal M, Javed A, Murtaza M. Frequency of dry socket among patients undergoing dental extraction presenting to Ayub Teaching Hospital. J Univ Med Dent Coll. 2022;13(2):387-90.
8. Khan NB, Arsalan A, Yasir A, Azhar M, Ali M, Nawadat K. Frequency of dry socket among patients undergoing dental extractions presenting to a teaching hospital, Rawalpindi. PJHS. 2024;5(9):76-80.
9. Tandon P, Sahoo SK, Mohanty L, Jain N, Hittalamani V, Kamble SS, Singh R. Dry socket prevalence and risk factors in third molar extractions: a prospective observational study. Cureus. 2024;16(3): e56721.
10. Khan M, Ali S, Zeb U, Ijaz I. Frequency of dry socket in patients coming to dental outpatients' department, Saidusharif Hospital, Swat. Bulletin of Environment, Pharmacology and Life Sciences. 2020;9(8):94-9.
11. Kim JY, Han MD, Lee H, Ko JH, Park YL, Huh JK. Are There Differences in the Causes and Complications of Mandibular Third Molar Extraction in Older Patients Compared to Younger Patients? J Oral Maxillofac Surg. 2024;82(11):1416-24.
12. Gazal G, Al-Samadani KH, Alsaidalani HM, Karbouji GA, Alharbi AM. A Comparison of Pre-Emptive Co-Amoxiclav, Postoperative Amoxicillin, and Metronidazole for Prevention of Postoperative Complications in Dentoalveolar Surgery: A Randomized Controlled Trial. Int J Environ Res Public Health. 2022;19(7).
13. Gumrukcu Z, Karabag M, Guven SE. The effects of chlorhexidine gel and tranexamic acid application after tooth extraction on the risk of alveolar osteitis formation: a double blind clinical study. Clin Oral Investig. 2024;28(9):494.
14. Bataineh ABA, Alkadi ST. Incidence and risk factors affecting fibrinolytic alveolitis after permanent tooth extractions. Clin Oral Investig. 2025;29(3):175.
15. Chugh A, P GG, Kumar P, Kaur A. Localised 0.2% chlorhexidine irrigation delivery system versus oral antibiotics in reducing postoperative complications in the surgical extraction of impacted mandibular third molar (IMTM). - a randomised controlled trial. Med Oral Patol Oral Cir Bucal. 2024;29(5):e690-e7.
16. Otake H, Sato Y, Nakatani E, Hawke P, Takei S, Ogino A, et al. Oxytetracycline-hydrocortisone ointment reduces the occurrence of both dry socket and post-extraction pain after third molar extraction: An observational study. PLoS One. 2021;16(7):e0254221.
17. Cardoso RB, Soto VC, Gonçalves RC, Pedroso AM, Jabur RD, Bortoluzzi MC. Prevalence and factors associated with dry socket following routine dental extractions. Med Oral Patol Oral Cir Bucal. 2024;29(3):e408-e15.

© 2025 et al. Open access under CC BY License (Creative Commons). Freely distributable with appropriate citation.

18. Boyer TL, Solanki P, McGregor JC, Wilson GM, Gibson G, Jurasic MM, et al. Risk factors for oral infection and dry socket post-tooth extraction in medically complex patients in the absence of antibiotic prophylaxis: A case-control study. Spec Care Dentist. 2024;44(4):1171-81.
19. Nakagawa Y, Shimada Y, Kawasaki Y, Honda H, Aoki T, Takanabe Y, et al. Risk Factors for Post-Tooth Extraction Complications in HIV-Infected Patients: a Retrospective Study. Jpn J Infect Dis. 2021;74(5):392-8.
20. Bailey E, Kashbour W, Shah N, Worthington HV, Renton TF, Coulthard P. Surgical techniques for the removal of mandibular wisdom teeth. Cochrane Database Syst Rev. 2020;7(7):Cd004345.

© 2025 et al. Open access under CC BY License (Creative Commons). Freely distributable with appropriate citation.