INSIGHTS-JOURNAL OF HEALTH AND REHABILITATION

COMPARATIVE STUDY OF DWI VS DYNAMIC CONTRAST ENHANCED MRI IN DIAGNOSIS OF BREAST TUMORS KEEPING HISTOPATHOLOGY AS GOLD STANDARD

Original Research

Sarah Nathaniel[1]*, Muhammad Zeeshan Ali[1], Sania Nathaniel[2], Adnan Yousaf[3], Rabia Haq[1], Mahnoor Naeem[1]

[1]Armed Forces Institute of Radiology and Imaging (AFIRI), Rawalpindi, Pakistan.

[2]Fauji Foundation Hospital, Pakistan.

[3]Bolan Medical Complex Hospital, Quetta, Pakistan.

Corresponding Author: Sarah Nathaniel, Armed Forces Institute of Radiology and Imaging (AFIRI), Rawalpindi, Pakistan, sarahnathaniel17@gmail.com

Acknowledgement: The authors gratefully acknowledge the support of AFIRI for providing technical and institutional assistance throughout this study.

Conflict of Interest: None

Grant Support & Financial Support: None

ABSTRACT

Background: Breast cancer remains a leading cause of morbidity and mortality among women worldwide. Early and accurate detection plays a crucial role in improving treatment outcomes and survival rates. Imaging modalities such as Diffusion-Weighted Imaging (DWI) and Dynamic Contrast-Enhanced Magnetic Resonance Imaging (DCE-MRI) offer promising non-invasive diagnostic approaches. These methods provide valuable anatomical and functional information, particularly in cases where biopsy is limited by lesion size or location.

Objective: To assess and compare the diagnostic accuracy of DWI and DCE-MRI in differentiating between benign and malignant breast tumors, using histopathology as the gold standard.

Methods: This cross-sectional study was conducted at the Armed Forces Institute of Radiology and Imaging (AFIRI), Rawalpindi, from September 2022 to August 2024. A total of 100 female patients aged 18–75 years were enrolled through purposive sampling after obtaining informed consent. All participants underwent breast MRI using a 1.5 Tesla machine, incorporating both DWI with b-values of 0 and 750 s/mm² and DCE-MRI. Time-Intensity Curves (TIC) were generated, and tumor classification was performed according to ACR BI-RADS. Imaging findings were compared with histopathological outcomes to calculate sensitivity, specificity, positive predictive value (PPV), negative predictive value (NPV), and diagnostic accuracy (DA).

Results: The mean age of patients with benign tumors was 39.76 ± 12.30 years, while for malignant tumors it was 44.62 ± 11.68 years. Histopathological evaluation confirmed 29% benign and 71% malignant tumors. DWI showed a sensitivity of 97.18%, specificity of 89.66%, PPV of 95.83%, NPV of 92.86%, and diagnostic accuracy of 95%. DCE-MRI demonstrated sensitivity of 97.18%, specificity of 86.21%, PPV of 94.52%, NPV of 92.59%, and diagnostic accuracy of 94%. Combining both modalities improved diagnostic accuracy to 97%.

Conclusion: DWI and DCE-MRI demonstrated high diagnostic performance in distinguishing breast tumor types. Combined use further enhances accuracy and may reduce the need for invasive procedures, especially in diagnostically challenging cases.

Keywords: Apparent Diffusion Coefficient, Breast Neoplasms, DCE-MRI, Diagnostic Imaging, DWI, Magnetic Resonance Imaging, Tumor Detection.

© 2025 et al. Open access under CC BY License (Creative Commons). Freely distributable with appropriate citation.

INTRODUCTION

Breast cancer remains one of the most prevalent and life-threatening malignancies affecting women worldwide. Its early detection and timely intervention significantly improve patient survival and quality of life. Over the years, advances in awareness, regular clinical evaluations, and the integration of imaging technologies have played a critical role in the prompt identification and effective management of breast cancer (1–3). These developments have led to earlier diagnoses, enabling the adoption of less invasive treatment strategies with improved prognoses (4). Among the diagnostic protocols, the "triple assessment" approach—comprising physical examination, radiological imaging, and histopathological analysis—has become a cornerstone for evaluating palpable breast lesions and guiding clinical decision-making (5). Mammography and breast ultrasound are widely used imaging techniques for the detection and initial evaluation of breast abnormalities. Their accessibility and cost-effectiveness make them suitable as frontline tools in breast cancer screening, especially in resource-constrained settings (6,7). However, while effective, these modalities may have limitations in characterizing lesion types, particularly in dense breast tissue or ambiguous cases. In recent years, dynamic contrast-enhanced magnetic resonance imaging (DCE-MRI) has emerged as a highly sensitive modality for identifying and characterizing breast tumors, offering detailed visualization of vascular patterns associated with malignancy (6).

Diffusion-weighted imaging (DWI), which does not require contrast administration, has also shown promise in distinguishing between benign and malignant lesions based on cellular density and water molecule diffusion properties. Apparent diffusion coefficient (ADC) values derived from DWI provide quantitative insight, adding diagnostic confidence, particularly for patients with contraindications to contrast agents, such as impaired renal function or previous allergic reactions (8). Magnetic resonance imaging further demonstrates superiority in preoperative planning by offering detailed anatomical delineation of posterior breast tissues, axillary lymph node involvement, and the presence of multifocal or bilateral tumors. Its capacity to assess tumor extent more precisely than conventional methods is of particular value in surgical decision-making and treatment planning for invasive carcinomas (9–11). Given the evolving landscape of breast imaging, there is a growing need to establish which modality provides greater diagnostic accuracy in differentiating benign from malignant breast lesions. Therefore, the objective of this study is to assess and compare the diagnostic performance of DWI and DCE-MRI, using histopathological findings as the gold standard, to determine their respective roles in accurate tumor characterization and breast cancer diagnosis.

METHODS

This cross-sectional study was conducted at the Armed Forces Institute of Radiology and Imaging (AFIRI), Rawalpindi, from September 29, 2022, to August 29, 2024, following approval from the institutional ethical review committee (ERC Letter No: Afiri-Rwp-Erc-Appv:08). Written informed consent was obtained from all participants prior to study enrollment. The study included female patients aged 18 to 75 years who underwent diffusion-weighted imaging (DWI) in combination with dynamic contrast-enhanced magnetic resonance imaging (DCE-MRI) for the evaluation of breast tumors. Eligibility criteria included women with either a palpable breast mass or an ultrasound-detected tumor, referred for core needle biopsy by their consulting physician. Patients were excluded if they had undergone surgery within the previous three months, had contraindications to MRI, reported adverse reactions to contrast agents, or were unable or unwilling to comply with study procedures, including biopsy. A non-probability purposive sampling technique was employed. The required sample size was calculated to be 100 using the WHO sample size calculator, with a 95% confidence interval, an estimated disease prevalence of 45%, and assumed sensitivity and specificity of 82% and 86%, respectively, for DWI in differentiating malignant from benign tumors. All MRI scans were conducted using a 1.5 Tesla machine equipped with a dedicated breast coil. Imaging was performed by a female radiologist to maintain patient comfort and compliance. Prior to imaging, metallic objects were removed, and intravenous access was secured for gadolinium-based contrast (GC) administration. Patients were positioned prone with breasts placed centrally in the coil and nipples directed downward, and were instructed to remain motionless throughout the scan.

The imaging protocol consisted of axial T1- and T2-weighted spin echo sequences, axial STIR (Short Tau Inversion Recovery) sequences for fat suppression, and axial DWI echo planar sequences with b-values of 0 and 750 s/mm². Post-contrast images were acquired and subtracted from pre-contrast images to generate subtraction maps. Maximum intensity projection images were created, and kinetic curves

© 2025 et al. Open access under CC BY License (Creative Commons). Freely distributable with appropriate citation.

INSIGHTS-JHR
INSIGHTS-JOURNAL OF HEALTH AND REHABILITATION

(KC) were plotted to assess tumor enhancement. These curves were categorized into three types: Type I (progressive enhancement), typically suggestive of benign pathology; Type II (plateau), indicating suspicion for malignancy; and Type III (washout pattern), strongly associated with malignant tumors. Initial tumor detection was achieved via STIR imaging, while T1-weighted and STIR sequences were used to assess tumor morphology, including margins and shape. DCE-MRI provided enhancement features that were evaluated based on late-phase KC classification. DWI signal intensity and apparent diffusion coefficient (ADC) values were recorded, using the tumor region with the highest signal as the region of interest. An ADC cut-off value of 1100×10^{-6} mm²/s was applied to distinguish malignant from benign lesions, based on existing literature.

All lesions detected by imaging were further classified using the American College of Radiology Breast Imaging Reporting and Data System (ACR BI-RADS). Tumors categorized as BI-RADS 2 and 3 were considered benign, while those in categories 4 and 5 were classified as malignant. Final confirmation of tumor type was established via histopathology, following ultrasound-guided percutaneous core needle biopsy, which was performed within 30 days of the MRI in accordance with protocol. Two board-certified radiologists, each with a minimum of three years of experience in breast MRI interpretation, independently evaluated the imaging findings. In case of discrepancy, consensus was reached through discussion. Data were analyzed using IBM SPSS software (version 25.0). Frequencies and percentages were calculated for tumor types, anatomical location, and imaging features. Descriptive statistics were applied based on the data type. A 2×2 contingency table was constructed to compute sensitivity, specificity, positive predictive value (PPV), negative predictive value (NPV), and diagnostic accuracy (DA) of DWI and DCE-MRI, using histopathological diagnosis as the gold standard.

RESULTS

The mean age of all participants was 43.21 ± 12.0 years. Tumor location was most frequently observed in the upper quadrant in 59% of cases, followed by the lower quadrant in 36%, the retroareolar region in 4%, and the subareolar region in 1%. According to the BI-RADS categorization, 9% of tumors were classified as category 2 or 3, 34% as category 4, and 48% as category 5. The mean apparent diffusion coefficient (ADC) value for all cases was $904.19 \pm 576.79 \times 10^{-6}$ mm²/s. A total of 72% of tumors showed restricted diffusion, while 28% demonstrated facilitated diffusion on DWI. DWI identified 28% of tumors as benign, whereas DCE-MRI detected 27%, and their combination diagnosed 26% as benign. Histopathology confirmed 29% of tumors as benign and 71% as malignant. Patients with benign tumors had a mean age of 39.76 ± 12.30 years, compared to 44.62 ± 11.68 years among those with malignant tumors. The most common tumor location was the upper outer quadrant (41%), followed by the lower outer quadrant (22%), upper inner quadrant (18%), and lower inner quadrant (14%). Retroareolar and subareolar regions accounted for 4% and 1%, respectively. Histopathological analysis revealed that among the malignant tumors, 71.83% were invasive ductal carcinoma, 22.54% were invasive lobular carcinoma, and 2.82% each were ductal carcinoma in situ and invasive medullary carcinoma. Benign tumors included fibroadenomas (65.52%), followed by abscesses, chronic granulomatous mastitis, fibrocystic disease, and inflammation (each 6.90%), while duct ectasia and papilloma accounted for 3.45% each. Based on DCE-MRI findings, 19 benign tumors (62%) were categorized as BI-RADS 2 or 3, while 11 benign tumors were assigned BI-RADS 4. All malignant tumors were categorized as BI-RADS 4 or 5, with 32.4% falling into category 4 and 67.6% into category 5. The association between BI-RADS category and tumor type was statistically significant ($p < 0.001$).

Out of 100 tumors, 72 showed restricted diffusion on DWI, suggesting malignancy, while 28 had facilitated diffusion indicating benign pathology. The mean ADC value of malignant tumors was $682.69 \pm 507.18 \times 10^{-6}$ mm²/s, significantly lower than that of benign tumors, which was $1446.48 \pm 322.82 \times 10^{-6}$ mm²/s ($p < 0.001$). Evaluation of time-intensity curves (TIC) after contrast administration showed that Type I curves, suggestive of benign pathology, were observed in 18 benign tumors (55.2%) and in none of the malignant ones. Type II curves were seen in 13 benign (44.8%) and 38 malignant tumors (53.5%), while Type III curves, indicating malignancy, were observed in 33 malignant tumors (46.5%) and none of the benign cases ($p < 0.001$). Diagnostic accuracy analysis revealed that DWI alone had a sensitivity of 97.18%, specificity of 89.66%, PPV of 95.83%, NPV of 92.86%, and overall accuracy of 95%. DCE-MRI demonstrated similar sensitivity (97.18%) but slightly lower specificity (86.21%), with a PPV of 94.52%, NPV of 92.59%, and diagnostic accuracy of 94%. When DWI and DCE-MRI were combined, diagnostic performance improved further, yielding a sensitivity of 100%, specificity of 89.66%, PPV of 95.95%, NPV of 100%, and diagnostic accuracy of 97%.

The comparative accuracy of DWI and DCE-MRI in identifying specific malignant tumor subtypes revealed important differences in performance across histopathological categories. Among the 51 cases of invasive ductal carcinoma, DWI correctly identified 50 (98.04%) and DCE-MRI identified 49 (96.08%). For invasive lobular carcinoma (n=16), DWI detected 14 (87.5%) cases accurately, while DCE-MRI correctly identified 13 (81.25%). Both DWI and DCE-MRI achieved 100% detection rates in the smaller subgroups of

© 2025 et al. Open access under CC BY License (Creative Commons). Freely distributable with appropriate citation.

INSIGHTS-JHR
INSIGHTS-JOURNAL OF HEALTH AND REHABILITATION

ductal carcinoma in situ and invasive medullary carcinoma (2 cases each). These findings suggest that both imaging modalities perform exceptionally well in detecting common subtypes such as invasive ductal carcinoma, but their accuracy may be somewhat reduced in less prevalent forms like invasive lobular carcinoma. This subtype-specific analysis adds depth to the diagnostic utility of DWI and DCE-MRI and underscores the value of their combined application in comprehensive breast cancer assessment.

Table 1: Classification of Tumor Types on the basis of histopathology(n=100)

Histopathological Diagnosis		**Patient Count (n, %)**	
Tumor Type	Subtype	N	Percentage (%)
Malignant		71	71.0%
	Ductal Carcinoma In Situ	2	2.82%
	Invasive Medullary carcinoma	2	2.82%
	Invasive Ductal Carcinoma	51	71.83%
	Invasive Lobular Carcinoma	16	22.54%
Benign		29	29.00%
	Abscess	2	6.90%
	Chronic Granulomatous Mastitis	2	6.90%
	Duct Ectasia	1	3.45%
	Fibroadenomas	19	65.52%
	Fibrocystic Disease	2	6.90%
	Inflammation	2	6.90%
	Papilloma	1	3.45%

Table 2: Discriminating power of DWI, DCE-MRI and combination of both DWI+DCE-MRI, to distinguish between malignant ad benign breast tumors by keeping histopathology as gold standard. (n=100)

		Histopathology			
		Malignant	Benign	Total	
DWI	Malignant	69(95%)	3(5%)	72	Sensitivity= 97.18%, Specificity = 89.66%, PPV = 95.83%, NPV = 92.86%, DA = 95%
	Benign	2(7.14%)	26(92.86%)	28	
DCE-MRI	Malignant	69(94.5%)	4(5.5%)	73	Sensitivity= 97.18%, Specificity = 86.21%, PPV = 94.52%, NPV = 92.59%, DA = 94%
	Benign	2(7.4%)	25(92.6%)	27	
DWI + DCE-MRI	Malignant	71(95.9%)	3(4.1%)	74	Sensitivity= 100%, Specificity = 89.66%, PPV = 95.95%, NPV = 100%, DA = 97%
	Benign	0(0%)	26(100%)	26	

© 2025 et al. Open access under CC BY License (Creative Commons). Freely distributable with appropriate citation.

INSIGHTS-JHR
INSIGHTS-JOURNAL OF HEALTH AND REHABILITATION

Table 3: Comparative Accuracy of DWI and DCE-MRI by Tumor Subtype

Histopathological Subtype	Total Cases (n)	Correctly Identified by DWI (n)	Accuracy DWI (%)	Correctly Identified by DCE-MRI (n)	Accuracy DCE-MRI (%)
Invasive Ductal Carcinoma	51	50	98.04%	49	96.08%
Invasive Lobular Carcinoma	16	14	87.50%	13	81.25%
Ductal Carcinoma In Situ	2	2	100.00%	2	100.00%
Invasive Medullary Carcinoma	2	2	100.00%	2	100.00%

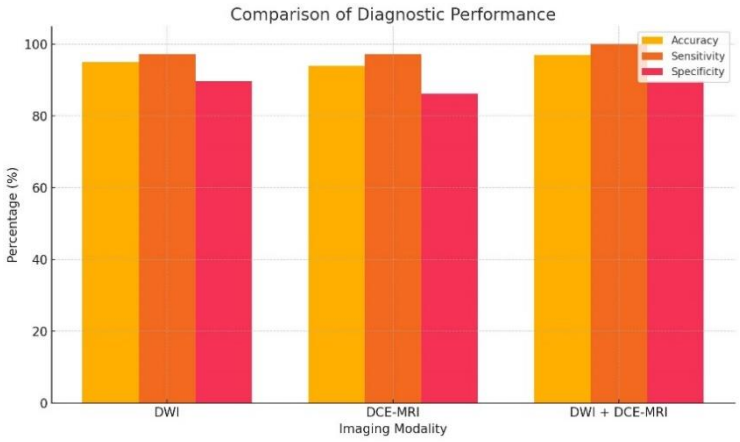

Figure 1 Comparison of Diagnostic Performance

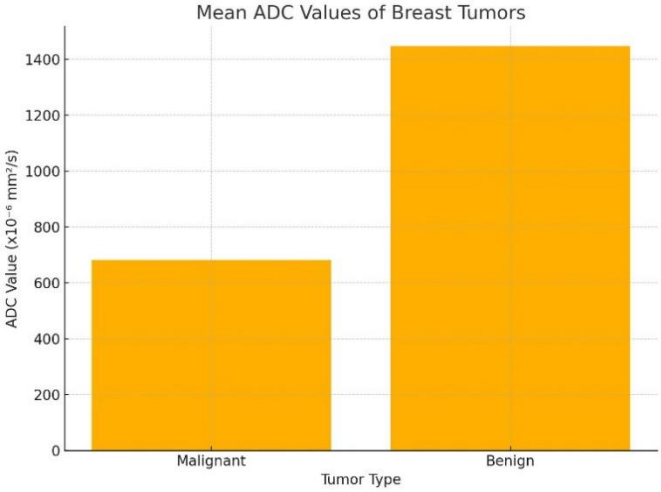

Figure 2Mean ADC Values of Breast Tumors

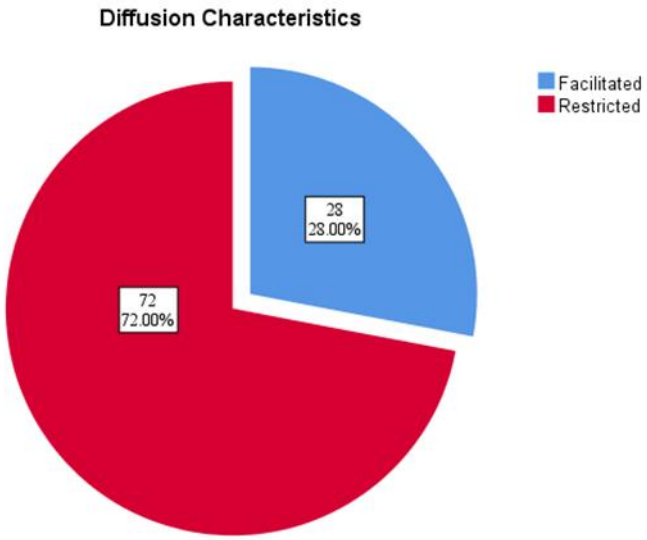

© 2025 et al. Open access under CC BY License (Creative Commons). Freely distributable with appropriate citation.

INSIGHTS-JHR
INSIGHTS-JOURNAL OF HEALTH AND REHABILITATION

DISCUSSION

MRI continues to be regarded as a highly reliable imaging modality for breast tumor detection and characterization due to its superior resolution and capacity to assess both anatomical and functional features of lesions. However, its use is often limited by high cost, contraindications in certain patients, and the potential for adverse reactions to intravenous contrast agents. In the present study, MRI was employed using both diffusion-weighted imaging (DWI) and dynamic contrast-enhanced MRI (DCE-MRI), either alone or in combination, to evaluate their diagnostic performance in differentiating between malignant and benign breast tumors. A higher frequency of breast tumors was observed in the upper outer quadrant, a finding that mirrors previous reports which attributed this distribution to a greater volume of breast tissue in this region or possibly to external exposures such as cosmetic product use (12). The current study also reinforced earlier findings that malignant lesions tend to demonstrate significantly lower apparent diffusion coefficient (ADC) values compared to benign ones, a diagnostic hallmark supported by several previous investigations (13–15). The study utilized a b-value combination of 0 and 750 mm^2/s for optimal DWI resolution, minimizing image artifacts while preserving diagnostic clarity. Higher b-values, such as 1000 mm^2/s, though commonly used, were avoided due to their tendency to introduce susceptibility artifacts and compromise image quality (16).

Enhancement patterns from time-intensity curves (TIC) on DCE-MRI provided valuable insight into tumor vascularity and behavior. In this cohort, benign tumors predominantly exhibited Type I and II kinetic curves, while malignant lesions showed a strong tendency toward Type II and III curves. These observations are in alignment with prior studies that emphasized the clinical relevance of TIC patterns in tumor differentiation (17–19). Specifically, washout-type (Type III) curves were predominantly associated with malignancy, reinforcing the functional value of contrast dynamics in diagnostic imaging. The study demonstrated that DWI and DCE-MRI independently had a sensitivity of 97.18%, with DWI showing marginally higher specificity (89.66%) than DCE-MRI (86.21%). Notably, the combined application of both modalities improved the overall diagnostic accuracy, achieving a sensitivity of 100% and specificity of 89.66%. This synergistic improvement echoes the results from earlier studies, which similarly concluded that a multi-parametric MRI approach outperforms individual techniques when used alone (13,20). Moreover, the combined modality mitigates the limitations of each technique—DWI's lower spatial resolution and DCE-MRI's dependency on contrast administration—resulting in a more robust diagnostic pathway.

This study also provided a stratified evaluation of DWI and DCE-MRI across specific malignant subtypes. While both modalities exhibited excellent accuracy in identifying common tumors such as invasive ductal carcinoma, a slight decline in accuracy was noted for less common subtypes like invasive lobular carcinoma. This differential performance underscores the need for nuanced application of imaging techniques, especially in histologically diverse tumor populations. The study's key strengths included the use of histopathology as a gold standard, the employment of standardized imaging protocols, and the incorporation of dual radiologist evaluation to reduce interpretative bias. The structured use of b-values in DWI and the analysis of kinetic enhancement curves in DCE-MRI contributed to comprehensive tumor characterization. Nevertheless, the study was limited by its relatively small sample size and short study duration. The financial burden of MRI procedures, limited awareness of its benefits, and patient reluctance due to contrast concerns contributed to the restricted participant pool. These factors constrained the generalizability of findings, especially across underrepresented tumor subtypes. Future studies should aim for larger, multicenter cohorts with cost-effective MRI access and broader inclusion criteria. Inclusion of contrast-free imaging techniques such as synthetic MRI or advanced DWI protocols could also be explored to address contrast-related limitations. In conclusion, while both DWI and DCE-MRI proved highly effective in identifying breast tumor types, their combined application significantly enhanced diagnostic performance. These findings support the clinical utility of integrating both techniques in routine diagnostic workflows, particularly in complex or ambiguous cases where standalone imaging may fall short.

CONCLUSION

This study concluded that both diffusion-weighted imaging (DWI) and dynamic contrast-enhanced MRI (DCE-MRI) are highly valuable, non-invasive imaging modalities for distinguishing between benign and malignant breast tumors. Their ability to provide detailed anatomical and functional insights significantly supports early and accurate diagnosis, particularly in cases where biopsy is not feasible due to lesion location or size. When used in combination, DWI and DCE-MRI demonstrated enhanced diagnostic performance, reinforcing the clinical value of multiparametric MRI in breast cancer evaluation. These findings highlight the potential of integrated imaging strategies to reduce unnecessary biopsies and guide more precise, patient-centered management of breast tumors.

© 2025 et al. Open access under CC BY License (Creative Commons). Freely distributable with appropriate citation.

INSIGHTS-JHR
INSIGHTS-JOURNAL OF HEALTH AND REHABILITATION

AUTHOR CONTRIBUTION

Author	Contribution
Sarah Nathaniel*	Substantial Contribution to study design, analysis, acquisition of Data Manuscript Writing Has given Final Approval of the version to be published
Muhammad Zeeshan Ali	Substantial Contribution to study design, acquisition and interpretation of Data Critical Review and Manuscript Writing Has given Final Approval of the version to be published
Sania Nathaniel	Substantial Contribution to acquisition and interpretation of Data Has given Final Approval of the version to be published
Adnan Yousaf	Contributed to Data Collection and Analysis Has given Final Approval of the version to be published
Rabia Haq	Contributed to Data Collection and Analysis Has given Final Approval of the version to be published
Mahnoor Naeem	Substantial Contribution to study design and Data Analysis Has given Final Approval of the version to be published

REFERENCES

1. Ginsburg O, Yip CH, Brooks A, Cabanes A, Caleffi M, Dunstan Yataco JA, et al. Breast cancer early detection: A phased approach to implementation. Cancer. 2020;126:2379-93.
2. Bicchierai G, Di Naro F, De Benedetto D, Cozzi D, Pradella S, Miele V, et al. A review of breast imaging for timely diagnosis of disease. International journal of environmental research and public health. 2021;18(11):5509.
3. Slanetz PJ. MRI of the breast and emerging technologies. UpToDate. 2020.
4. Shreyamsa M, Singh D, Ramakant P, Anand A, Singh KR, Mouli S, et al. Barriers to timely diagnosis and management of breast cancer: observations from a tertiary referral center in resource poor setting. Indian Journal of Surgical Oncology. 2020;11:287-93.
5. Bhesdadiya R, Kalola J, Jethva M. Mammographic and ultrasonographic evaluation of breast lesions with pathological correlation. Int J Contemp Med Surg Radiol. 2020;5(1):A158-A61.
6. Khan MD, Banerjee S, Tarafdar S, Kundu D. Role of sonomammography and its diagnostic accuracy for evaluating benign and malignant breast lesions. Int J Res Med Sci. 2021;9(5):1448-53.
7. Ahluwalia KS, Narula H, Jain A, Arora A, Vohra A, Bansal T, et al. Role of MRI in Differentiating Benign from Malignant Breast Lesions Using Dynamic Contrast Enhanced MRI and Diffusion Weighted MRI. J Evolution of Med and Dent Sci. 2021;10(19):1422-9.
8. Thompson JL, Wright GP. The role of breast MRI in newly diagnosed breast cancer: an evidence-based review. Am J Surg. 2021;221(3):525-8.
9. Marino MA, Avendano D, Zapata P, Riedl CC, Pinker K. Lymph node imaging in patients with primary breast cancer: concurrent diagnostic tools. The oncologist. 2020;25(2):231-42.
10. Rotili A, Trimboli RM, Penco S, Pesapane F, Tantrige P, Cassano E, et al. Double reading of diffusion-weighted magnetic resonance imaging for breast cancer detection. Breast cancer research and treatment. 2020;180:111-20.
11. Azzam H, Kamal R, El-Assaly H, Omer L. The value of dynamic contrast-enhanced MRI in the diagnosis and management of triple-negative breast cancer. Egyptian J Radiol and Nuclear Med. 2020;51:1-6.

© 2025 et al. Open access under CC BY License (Creative Commons). Freely distributable with appropriate citation.

12. Singh A, Purewal J, Gupta K, Singh G. Breast lesion characterisation with diffusion-weighted imaging versus dynamic contrast-enhanced-MRI: a prospective observational study in a tertiary care hospital. EMJ. 2021;2(1):75-82.
13. Wang H, van der Velden BHM, Ragusi MAA, Veldhuis WB, Viergever MA, Verburg E, et al. Toward Computer-Assisted Triaging of Magnetic Resonance Imaging-Guided Biopsy in Preoperative Breast Cancer Patients. Invest Radiol. 2021;56(7):442-9.
14. Miyake T, Shimazu K. Third-look contrast-enhanced ultrasonography plus needle biopsy for differential diagnosis of magnetic resonance imaging-only detected breast lesions. J Med Ultrason (2001). 2024;51(4):599-604.
15. Zheng S, Qi L, Guang-Qiang Z, Ming-Ming S, Chun-Hong X. Role of Magnetic Resonance Imaging in Predicting Residual Breast Cancer After Vacuum-Assisted Breast Biopsy. Am Surg. 2021;87(6):885-91.
16. Coskun Bilge A, Esen Bostanci I. Predictive value of dynamic contrast-enhanced breast magnetic resonance imaging and diffusion-weighted imaging findings for sentinel lymph node metastasis in early-stage invasive breast cancer. Br J Radiol. 2025;98(1167):475-82.
17. Montemezzi S, Cardano G, Storer S, Cardobi N, Cavedon C, Camera L. MRI-guided breast biopsy based on diffusion-weighted imaging: a feasibility study. Eur Radiol. 2021;31(5):2645-56.
18. Mun HS, Kang BJ, Kim SH, Park GE. Enhanced Detection of Residual Breast Cancer Post-Excisional Biopsy: Comparative Analysis of Contrast-Enhanced MRI with and Without Diffusion-Weighted Imaging. Tomography. 2025;11(1).
19. James J. Contrast-enhanced spectral mammography (CESM)-guided breast biopsy as an alternative to MRI-guided biopsy. Br J Radiol. 2022;95(1132):20211287.
20. Fueger BJ, Clauser P, Kapetas P, Pötsch N, Helbich TH, Baltzer PAT. Can supplementary contrast-enhanced MRI of the breast avoid needle biopsies in suspicious microcalcifications seen on mammography? A systematic review and meta-analysis. Breast. 2021;56:53-60.

© 2025 et al. Open access under CC BY License (Creative Commons). Freely distributable with appropriate citation.