INSIGHTS-JOURNAL OF
HEALTH AND REHABILITATION

INSIGHTS-JHR
INSIGHTS-JOURNAL OF HEALTH AND REHABILITATION

ETIO-RADIOLOGICAL CORRELATION OF CHEST INFILTRATES IN IMMUNE COMPROMISED PATIENTS WITH THE DIAGNOSTIC TOOL OF ENDOBRONCHIAL WASHINGS PRESENTING IN A TERTIARY CARE HOSPITAL IN PAKISTAN

Original Research

Shafi Ullah[1]*, Shahzeb Ahmad Satti[2], Muhammad Imran[3], Aiman Sajjad[4], Muhammad Yaqoob Khan[1], Mehwish Abbas[1]
[1]Resident Pulmonology, Pak Emirate Military Hospital (PEMH), Rawalpindi, Pakistan.
[2]Professor of Medicine and Pulmonology, Pak Emirate Military Hospital (PEMH), Rawalpindi, Pakistan.
[3]Associate Professor of Medicine and Pulmonology, Pak Emirate Military Hospital (PEMH), Rawalpindi, Pakistan.
[4]Resident Medicine, Lady Reading Hospital (LRH) Peshawar, affiliated with Pak Emirate Military Hospital (PEMH), Rawalpindi, Pakistan.
Corresponding Author: Shafi Ullah, Resident Pulmonology, Pak Emirate Military Hospital (PEMH), Rawalpindi, Pakistan, shafiullah004@gmail.com
Acknowledgement: The authors acknowledge the support of the Pulmonology Department, Pak Emirates Military Hospital, Rawalpindi, in facilitating this study.

Conflict of Interest: None

Grant Support & Financial Support: None

ABSTRACT

Background: Immunocompromised individuals are highly susceptible to pulmonary infections, often presenting with nonspecific chest infiltrates that pose diagnostic challenges. Accurate and early identification of the underlying etiology is critical to initiating targeted treatment and minimizing morbidity and mortality. In resource-limited and TB-endemic regions such as Pakistan, diagnostic strategies that integrate imaging and microbiological tools are essential to improve clinical outcomes in high-risk patient groups.

Objective: To assess the correlation between radiological patterns and etiological diagnoses established through endobronchial washings in immunocompromised patients with chest infiltrates.

Methods: A prospective observational study was conducted on 120 immunocompromised adult patients presenting with radiologically confirmed chest infiltrates. Chest X-ray was performed in all cases, with high-resolution computed tomography (HRCT) additionally conducted in 70 patients (58.3%). All patients underwent fiberoptic bronchoscopy with endobronchial washings, which were analyzed via microbiological and cytological methods. Statistical analysis, including chi-square and Fisher's exact tests, was used to assess correlations between imaging findings and confirmed diagnoses.

Results: The mean age was 45.2 ± 13.6 years, with a male-to-female ratio of 1.4:1. The main causes of immunosuppression were hematologic malignancies (30%), HIV infection (25%), and chronic corticosteroid therapy (20%). The most frequent radiologic pattern was alveolar consolidation (38.3%), followed by ground-glass opacities (25%), nodular lesions (15.8%), cavitations (12.5%), and reticulonodular infiltrates (8.4%). Endobronchial washings yielded a definitive diagnosis in 92 out of 120 patients (76.7%). Tuberculosis was the most common etiology (30.4%), followed by bacterial infections (23.9%), fungal infections (19.6%), Pneumocystis jirovecii pneumonia (10.9%), and viral pneumonias (6.5%). Cavitary lesions were significantly associated with TB ($p = 0.002$), and ground-glass opacities were predictive of PJP and viral infections ($p = 0.013$).

Conclusion: The integration of radiological pattern recognition with endobronchial washing-based diagnostics significantly enhances the accuracy of etiologic identification in chest infiltrates among immunocompromised patients. This approach is particularly valuable in TB-endemic and resource-constrained settings, enabling timely, targeted therapeutic interventions.

Keywords: Bronchoscopy, Chest Infiltrates, Endobronchial Washings, Immunocompromised Host, Pneumocystis Pneumonia, Radiographic Imaging, Tuberculosis.

© 2025 et al. Open access under CC BY License (Creative Commons). Freely distributable with appropriate citation.

INTRODUCTION

Immuno-compromised individuals represent a particularly vulnerable population prone to a diverse array of pulmonary infections, primarily due to compromised host defenses. Conditions such as human immunodeficiency virus (HIV)/acquired immunodeficiency syndrome (AIDS), hematologic and solid organ malignancies, post-organ transplant status, and the administration of immunosuppressive therapies significantly increase the risk of opportunistic infections and atypical pulmonary manifestations. These infections often carry high morbidity and mortality, especially when diagnosis and intervention are delayed (1,2). Among the most frequent clinical indicators in these patients are chest infiltrates, which may serve as early manifestations of an infectious, neoplastic, or non-infectious inflammatory process (3). Radiologically, however, these infiltrates often present with non-specific patterns, making differential diagnosis challenging. Imaging findings such as ground-glass opacities, consolidation, or nodular infiltrates may be observed in various infectious conditions including Pneumocystis jirovecii pneumonia (PJP), tuberculosis (TB), fungal infections, or in non-infectious etiologies like lymphoproliferative disorders (4,5). This overlap in radiologic patterns frequently results in a diagnostic dilemma, underscoring the need for adjunctive diagnostic modalities.

Bronchoscopy with endobronchial washings offers a minimally invasive yet high-yield diagnostic approach, particularly in cases where sputum samples are non-representative or radiologic findings are inconclusive. By allowing direct sampling from the lower respiratory tract, endobronchial washing enhances the likelihood of identifying the underlying pathogen or malignancy, thereby facilitating targeted therapy and improving clinical outcomes (6,7). Studies have demonstrated that the diagnostic yield of endobronchial washings surpasses that of conventional sputum cultures in immunocompromised patients, making it an invaluable tool in pulmonary diagnostics (8). Moreover, correlating specific radiologic patterns with microbiological or histopathological diagnoses can assist clinicians in narrowing down the differential diagnoses more efficiently. This approach not only aids in early and accurate diagnosis but also helps minimize empirical treatment, reduces antimicrobial resistance, and improves prognosis in a high-risk population (9,10). In countries like Pakistan, where the burden of infectious diseases—particularly tuberculosis—is significantly high and diagnostic resources are often constrained, the establishment of such etio-radiological correlations becomes even more critical (11). Despite this pressing need, local data remains scarce. This study therefore seeks to evaluate the underlying etiologies of chest infiltrates in immunocompromised patients, correlate these with their radiological patterns, and assess the diagnostic yield of endobronchial washings in a tertiary care hospital setting. The objectives are to delineate the radiologic characteristics of pulmonary infiltrates, identify their etiologic spectrum via endobronchial washings, explore correlations between imaging findings and confirmed diagnoses, and determine the overall diagnostic utility of bronchoscopic evaluation in this population.

METHODS

This study was designed as a prospective observational clinical series conducted at the Department of Pulmonology, Pak Emirates Military Hospital, a tertiary care teaching hospital based in Rawalpindi, Pakistan. The clinical observations were prospectively recorded over a six-month period from July 10, 2024, to January 9, 2025. The study targeted adult immunocompromised patients aged 18 years and above who presented with lower respiratory tract symptoms—such as cough, dyspnea, or fever—along with radiologically confirmed chest infiltrates identified through either chest X-ray or high-resolution computed tomography (HRCT). The immunocompromised status of patients was defined based on the presence of HIV infection, hematologic malignancies, solid organ transplant status, long-term immunosuppressive therapy including corticosteroids or chemotherapy, or congenital immunodeficiency disorders (1). Participants were enrolled if complete clinical, radiological, and laboratory data were available in their medical records, and if they had undergone bronchoscopy with endobronchial washing as part of their clinical management. Additionally, patients who consented to prospective clinical documentation were included. Exclusion criteria involved patients who were hemodynamically unstable or had contraindications to bronchoscopy, including severe hypoxemia or known bleeding diatheses. Pregnant women, patients with incomplete documentation, or those who did not consent to future clinical observation were excluded from the final analysis.

Ethical approval for the study was obtained from the institutional ethics committee of Pak Emirates Military Hospital, and all procedures conformed to the ethical standards outlined in the Declaration of Helsinki. For retrospective record analysis, a waiver of informed consent was granted, as all data were anonymized. For prospective observations, written informed consent was obtained from patients

© 2025 et al. Open access under CC BY License (Creative Commons). Freely distributable with appropriate citation.

INSIGHTS-JHR
INSIGHTS-JOURNAL OF HEALTH AND REHABILITATION

prior to inclusion. Radiological assessments were based on baseline chest radiographs and HRCT scans, which were independently reviewed by two consultant radiologists blinded to all clinical and microbiological data. Radiographic findings were categorized into predefined patterns including alveolar consolidation, ground-glass opacities, nodular lesions, cavitations, and reticulonodular changes, following a standardized interpretative framework (1). Bronchoscopic procedures, including endobronchial washing, were performed by trained pulmonologists under standard operating protocols. Key procedural parameters such as sedation method, site of lavage, and saline volume were recorded in the clinical notes and subsequently extracted for analysis. These procedures were not conducted solely for research purposes but were a part of routine clinical care.

Laboratory analyses of endobronchial washing specimens were carried out according to hospital protocol. Microbiological evaluations included bacterial and fungal cultures, acid-fast bacilli (AFB) smear and culture, and GeneXpert MTB/RIF for tuberculosis. Cytological examination was performed for malignancy screening and the detection of atypical cells (10). Where clinically indicated, PCR-based assays were utilized for the detection of viral pathogens. All laboratory tests were processed in the hospital's central laboratory facilities.

Data were collected using a structured data collection form, capturing demographic information, clinical presentation, radiologic interpretation, and laboratory findings. The data were subsequently entered into SPSS version 25.0 (IBM Corp., Armonk, NY, USA) for statistical analysis. Descriptive statistics were used to summarize the patient characteristics and diagnostic outcomes. Categorical variables were analyzed using the chi-square test or Fisher's exact test, depending on data distribution. A p-value of <0.05 was considered statistically significant.

RESULTS

A total of 120 immunocompromised adult patients with radiologically confirmed chest infiltrates were enrolled during the study period. The mean age of the study population was 45.2 ± 13.6 years, with a male-to-female ratio of 1.4:1. The leading underlying causes of immunosuppression included hematological malignancies in 36 patients (30%), HIV infection in 30 patients (25%), chronic corticosteroid therapy in 24 patients (20%), solid organ transplantation in 18 patients (15%), and chemotherapy for solid tumors in 12 patients (10%). The radiological assessment revealed alveolar consolidation as the most frequently observed pattern, present in 46 patients (38.3%). This was followed by ground-glass opacities in 30 patients (25%), nodular lesions in 19 patients (15.8%), cavitations in 15 patients (12.5%), and reticulonodular infiltrates in 10 patients (8.4%). All patients underwent chest X-ray imaging, while high-resolution computed tomography (HRCT) was performed in 70 cases (58.3%) for better lesion characterization. Endobronchial washings provided a definitive etiological diagnosis in 92 out of 120 patients, yielding a diagnostic success rate of 76.7%. Among the confirmed diagnoses, Mycobacterium tuberculosis was identified in 28 cases (30.4%), making it the most common etiology. Bacterial pneumonias, including pathogens such as *Klebsiella pneumoniae*, *Streptococcus* spp., and *Pseudomonas aeruginosa*, were detected in 22 cases (23.9%). Fungal infections such as *Aspergillus* and *Candida* species were confirmed in 18 patients (19.6%), while Pneumocystis jirovecii pneumonia (PJP) and viral pneumonias (CMV and Influenza A) were observed in 10 (10.9%) and 6 (6.5%) patients respectively. Malignancy, including adenocarcinoma and lymphomas, was detected in 8 patients (8.7%). In the remaining 28 patients (23.3%), the washings were non-diagnostic, possibly due to low microbial burden or non-infectious causes.

Significant correlations were observed between certain radiological patterns and specific etiological diagnoses. Cavitary lesions showed a strong association with tuberculosis ($p = 0.002$), while ground-glass opacities were more frequently linked with PJP and viral pneumonias ($p = 0.013$). Nodular lesions were significantly associated with fungal infections and malignancy ($p = 0.021$). Alveolar consolidation was most commonly observed in bacterial pneumonias, although some overlap was noted with tuberculosis cases ($p = 0.047$). Reticulonodular patterns did not show a statistically significant correlation with any specific etiology ($p = 0.164$). Endobronchial washing demonstrated a higher diagnostic yield in cases with localized radiological findings, particularly cavitary lesions and alveolar consolidation, compared to cases with diffuse reticulonodular patterns. HRCT imaging prior to bronchoscopy appeared to enhance diagnostic accuracy by facilitating targeted sampling. Tuberculosis remained the most frequently diagnosed condition in this immunocompromised population, emphasizing the regional burden of TB and the importance of integrating radiologic and bronchoscopic findings for precise diagnosis and management. Stratification of diagnostic yield by imaging modality revealed that the diagnostic success of endobronchial washings was significantly higher when high-resolution computed tomography (HRCT) was performed prior to bronchoscopy. Among the 70 patients who underwent both chest X-ray and HRCT, 62 (88.6%) received a definitive diagnosis through endobronchial washing, compared to only 30 of the 50 patients (60.0%) who underwent chest X-ray alone. This suggests that HRCT substantially enhances diagnostic precision by guiding bronchoscopic sampling more effectively. Subgroup analysis based on the underlying causes of immunosuppression further demonstrated variability in diagnostic yield. Patients with hematological

© 2025 et al. Open access under CC BY License (Creative Commons). Freely distributable with appropriate citation.

INSIGHTS-JHR
INSIGHTS-JOURNAL OF HEALTH AND REHABILITATION

malignancies showed the highest diagnostic yield at 77.8%, followed closely by those receiving chronic corticosteroid therapy (75.0%). In contrast, patients with HIV infection, solid organ transplants, and those undergoing chemotherapy for solid tumors all demonstrated similar diagnostic yields of 66.7%. These findings indicate that while endobronchial washing remains valuable across all immunocompromised groups, its yield may be influenced by the type and pathophysiological nature of the underlying immunosuppressive condition.

Table 1: Demographic, Clinical, and Radiological Characteristics of the Study Population

Parameter	Value/Distribution
Total Patients	120
Age (mean ± SD)	45.2 ± 13.6 years
Male: Female	1.4: 1
Underlying Cause of Immunosuppression	
Hematological Malignancies	30%
HIV Infection	25%
Solid organ transplant	15%
Chronic corticosteroid therapy	20%
Chemotherapy for solid tumors	10%
Radiological Pattern (Chest Imaging)	
Alveolar consolidation	38.3%
Ground-glass opacities	25%
Nodular lesions	15.8%
Cavitations	12.5%
Reticulonodular infiltrates	8.4%
Imaging Modality	
Chest X-ray	120 patients (100%)
HRCT	70 patients (58.3%)

Table 2: Correlation Between Radiological Patterns and Etiological Diagnoses (n = 120)

Radiological Pattern	TB (n=28)	Bacterial (n=22)	Fungal (n=18)	PJP (n=10)	Viral (n=6)	Malignancy (n=8)	p-value
Alveolar consolidation	12	15	3	1	1	1	0.047
Ground-glass opacities	2	1	2	6	3	0	0.013
Cavitations	10	2	1	0	0	1	0.002
Nodular lesions	2	0	8	1	0	6	0.021
Reticulonodular patterns	2	4	4	2	2	0	0.164

Table 3: Diagnostic Yield Analysis

Imaging Modality	Total Patients	Positive Diagnoses via Washing	Diagnostic Yield (%)
Chest X-ray Only	50	30	60
HRCT + Chest X-ray	70	62	88.6

© 2025 et al. Open access under CC BY License (Creative Commons). Freely distributable with appropriate citation.

Table 4: Subgroup Analysis by Immunosuppression Type

Cause of Immunosuppression	Total Patients	Positive Diagnoses via Washing	Diagnostic Yield (%)
Hematological Malignancies	36	28	77.8
HIV Infection	30	20	66.7
Solid Organ Transplant	18	12	66.7
Chronic Corticosteroid Therapy	24	18	75
Chemotherapy for Solid Tumors	12	8	66.7

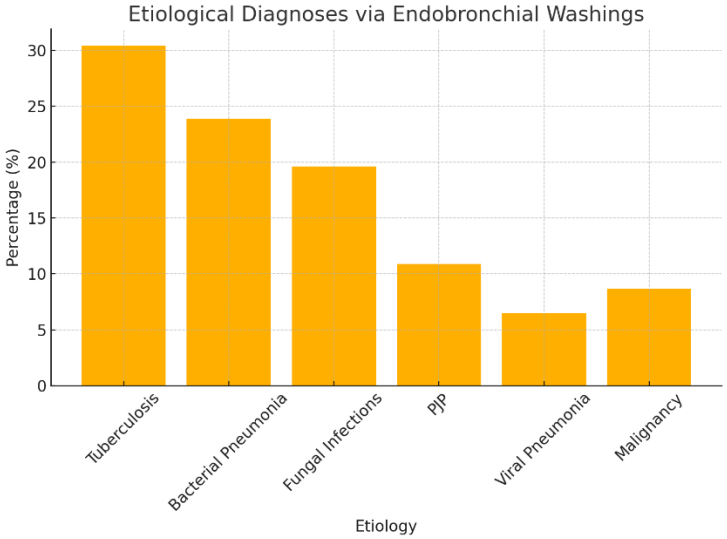

Figure 1 Etiological Diagnoses via Endobronchial Washings

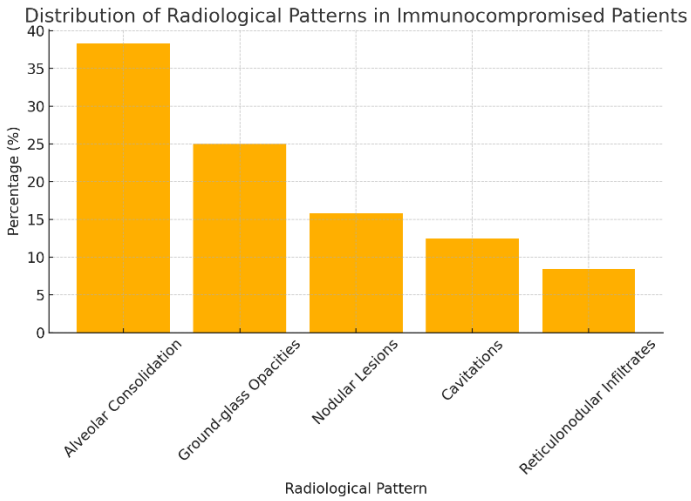

Figure 2 Distribution of Radiological Patterns in Immunocompromised Patients

DISCUSSION

This study highlighted the clinical value of establishing etio-radiological correlations and the diagnostic utility of endobronchial washings in immunocompromised patients presenting with chest infiltrates. With a diagnostic yield of 76.7%, the findings affirmed the significant role of fiberoptic bronchoscopy, especially in resource-constrained settings, where radiologic findings are often indeterminate and patients present with overlapping clinical syndromes. In a high tuberculosis (TB) burden country such as Pakistan, such evidence is particularly relevant. Tuberculosis emerged as the leading etiology, contributing to 30.4% of confirmed cases and demonstrating a strong association with cavitary lesions on imaging. This finding is in line with international data, including World Health Organization reports, which rank Pakistan among the top contributors to global TB incidence (12). Regional literature similarly reports TB as a major pathogen among immunocompromised populations, particularly in those receiving chronic corticosteroids or chemotherapy. The presence of cavitations strongly associated with TB ($p = 0.002$) further validates imaging-guided diagnostic algorithms in such settings. Bacterial infections, primarily caused by gram-negative organisms like *Klebsiella* and *Pseudomonas*, accounted for 23.9% of diagnoses. These were frequently associated with alveolar consolidation, a pattern supported by existing literature linking bacterial superinfections with immunosuppressive states such as malignancy and neutropenia (13,14). The predominance of nosocomial pathogens echoed the trends commonly seen in low- and middle-income country tertiary hospitals, where prolonged hospitalization and antimicrobial exposure are prevalent.

Fungal infections represented 19.6% of cases, largely comprising *Aspergillus* and *Candida* species. These infections commonly presented as nodular or mass-like lesions, particularly in hematologic malignancy and transplant recipients, consistent with invasive fungal disease patterns outlined by the EORTC/MSG consensus criteria (15). Similarly, Pneumocystis jirovecii pneumonia (PJP), accounting for 10.9% of cases, was mostly observed in patients with HIV or hematologic malignancies and was radiologically characterized by ground-glass opacities. These findings aligned with previous radiological and clinical studies highlighting PJP's typical imaging and epidemiological profile (16). Viral pneumonias, although less frequent (6.5%), were documented in severely

© 2025 et al. Open access under CC BY License (Creative Commons). Freely distributable with appropriate citation.

immunosuppressed patients and confirmed by PCR assays, illustrating the critical value of molecular diagnostics in the detection of viral pathogens (17,18). Radiological characteristics proved to be valuable indicators of underlying etiology. Ground-glass opacities were significantly associated with PJP and viral pneumonias ($p = 0.013$), while nodular lesions correlated with fungal infections and malignancies ($p = 0.021$). However, overlapping imaging patterns posed challenges; alveolar consolidation, though primarily linked with bacterial pneumonia, also appeared in TB cases. This underscores the importance of complementing imaging findings with invasive diagnostics, especially in cases where radiologic appearances do not conclusively suggest a specific pathogen (19,20). Endobronchial washing proved highly effective, particularly in patients with localized lesions or cavitations, supporting the notion that HRCT-guided bronchoscopy optimizes diagnostic yield. The observed yield aligns with previously reported rates of 60–80% in immunocompromised cohorts (21). In settings where access to advanced molecular diagnostics is limited, as in many parts of Pakistan, bronchoscopy remains a practical and indispensable tool for pathogen identification and timely therapeutic intervention.

This study offered several strengths, including its focus on a high-burden population, prospective data collection, and integration of radiologic-pathologic correlation to reinforce diagnostic accuracy. However, limitations must be acknowledged. Being a single-center study limits generalizability, and the absence of bronchoalveolar lavage or broader molecular testing panels may have contributed to missed diagnoses. Critically ill patients who were ineligible for bronchoscopy were not included, introducing potential selection bias. Additionally, while subgroup analysis by imaging modality and immunosuppression type was performed, further granularity—such as stratification by radiological sub-patterns within each etiological group—would offer greater diagnostic precision. Future studies should focus on multicenter collaborations and incorporate advanced diagnostics such as next-generation sequencing and expanded PCR panels. Comparative analyses between endobronchial washing and bronchoalveolar lavage would further delineate the most effective sampling technique in different clinical scenarios. Moreover, efforts to integrate imaging-driven diagnostic algorithms into routine clinical protocols may help reduce reliance on empirical therapies and curb antimicrobial resistance in immunocompromised populations.

CONCLUSION

This study concludes that the integration of radiological pattern recognition with endobronchial washing-based diagnosis serves as an effective and practical approach for identifying the underlying causes of chest infiltrates in immunocompromised patients. In settings with high burdens of infectious diseases such as tuberculosis, this combined diagnostic strategy holds particular importance in guiding timely, targeted treatment and reducing reliance on empirical therapies. By enhancing diagnostic precision, it contributes meaningfully to improving clinical outcomes and optimizing resource utilization in vulnerable patient populations.

© 2025 et al. Open access under CC BY License (Creative Commons). Freely distributable with appropriate citation.

INSIGHTS-JHR
INSIGHTS-JOURNAL OF HEALTH AND REHABILITATION

AUTHOR CONTRIBUTION

Author	Contribution
Shafi Ullah*	Substantial Contribution to study design, analysis, acquisition of Data Manuscript Writing Has given Final Approval of the version to be published
Shahzeb Ahmad Satti	Substantial Contribution to study design, acquisition and interpretation of Data Critical Review and Manuscript Writing Has given Final Approval of the version to be published
Muhammad Imran	Substantial Contribution to acquisition and interpretation of Data Has given Final Approval of the version to be published
Aiman Sajjad	Contributed to Data Collection and Analysis Has given Final Approval of the version to be published
Muhammad Yaqoob Khan	Contributed to Data Collection and Analysis Has given Final Approval of the version to be published
Mehwish Abbas	Substantial Contribution to study design and Data Analysis Has given Final Approval of the version to be published

REFERENCES

1. Maskin LP, Garcia Hernandez MH, Stryjewski ME, Rodriguez PO. A 31-Year-Old Man With Seizures, Brain Lesion, and Lung Nodules. Chest. 2021;160(6):e639-e43.
2. Makkar P, Stover D, Ko JP, Machnicki SC, Borczuk A, Raoof S. Algorithmic Approach to an Abnormal Computed Tomography of the Chest in the Immunocompromised Host. Clin Chest Med. 2025;46(1):1-20.
3. Otsuka Y, Kobayashi T. Case Report: A Patient with COVID-19 under Myelosuppression Induced by Chemotherapy. Am J Trop Med Hyg. 2020;103(5):1983-5.
4. Zhang P, Liu M, Zhang L, Guo X, Lu B, Wang Y, et al. Clinical and CT findings of adenovirus pneumonia in immunocompetent adults. Clin Respir J. 2021;15(12):1343-51.
5. Cai S, Sun W, Li M, Dong L. A complex COVID-19 case with rheumatoid arthritis treated with tocilizumab. Clin Rheumatol. 2020;39(9):2797-802.
6. Honjo K, Russell RM, Li R, Liu W, Stoltz R, Tabengwa EM, et al. Convalescent plasma-mediated resolution of COVID-19 in a patient with humoral immunodeficiency. Cell Rep Med. 2021;2(1):100164.
7. Cheng D, Wen J, Liu Z, Lv T, Chen JS. Coronavirus disease 2019 in renal transplant recipients: Report of two cases. Transpl Infect Dis. 2020;22(5):e13329.
8. Hsu JJ, Gaynor P, Kamath M, Fan A, Al-Saffar F, Cruz D, et al. COVID-19 in a high-risk dual heart and kidney transplant recipient. Am J Transplant. 2020;20(7):1911-5.
9. Aigner C, Dittmer U, Kamler M, Collaud S, Taube C. COVID-19 in a lung transplant recipient. J Heart Lung Transplant. 2020;39(6):610-1.
10. Machado DJB, Ianhez LE. COVID-19 pneumonia in kidney transplant recipients-Where we are? Transpl Infect Dis. 2020;22(5):e13306.
11. Marinelli L, Ristagno E, Fischer P, Abraham R, Joshi A. Cryptococcal pneumonia in an adolescent with a gain-of-function variant in signal transduction and activator of transcription 1 (STAT1). BMJ Case Rep. 2020;13(4).
12. World Health organization Global Tuberculosis Report 2023.

© 2025 et al. Open access under CC BY License (Creative Commons). Freely distributable with appropriate citation.

13. Huang JF, Zheng KI, George J, Gao HN, Wei RN, Yan HD, et al. Fatal outcome in a liver transplant recipient with COVID-19. Am J Transplant. 2020;20(7):1907-10.
14. Raj R, Venkatnarayan K, Krishnaswamy UM, Devaraj U, Ramachandran P, Savio J. A filamentous trio. Monaldi Arch Chest Dis. 2020;90(4).
15. Li F, Cai J, Dong N. First cases of COVID-19 in heart transplantation from China. J Heart Lung Transplant. 2020;39(5):496-7.
16. Asti E, Lovece A, Bonavina L. Gangrenous cholecystitis during hospitalization for SARS-CoV2 infection. Updates Surg. 2020;72(3):917-9.
17. Bellini MI, Fresilli D, Lauro A, Mennini G, Rossi M, Catalano C, et al. Liver Transplant Imaging prior to and during the COVID-19 Pandemic. Biomed Res Int. 2022;2022:7768383.
18. Mejia Buritica L, Karduss Urueta AJ. Pulmonary Mucormycosis. N Engl J Med. 2021;384(18):e69.
19. Ma F, Hu J, Bai M, Liu X, Liang G. SARS-CoV-2 not Detected in the Nasopharyngeal Sample but in Bronchoalveolar Lavage Fluid. Clin Lab. 2024;70(9).
20. Ritschl PV, Nevermann N, Wiering L, Wu HH, Moroder P, Brandl A, et al. Solid organ transplantation programs facing lack of empiric evidence in the COVID-19 pandemic: A By-proxy Society Recommendation Consensus approach. Am J Transplant. 2020;20(7):1826-36.
21. Abia-Trujillo D, Kornafeld A, Fernandez-Bussy S. Endobronchial Lesions in an Immunocompromised Host: An Atypical Case for Mycobacterium fortuitum. J Bronchology Interv Pulmonol. 2020;27(4):e65-e6.

© 2025 et al. Open access under CC BY License (Creative Commons). Freely distributable with appropriate citation.