INSIGHTS-JOURNAL OF
HEALTH AND REHABILITATION

INSIGHTS-JHR
INSIGHTS-JOURNAL OF HEALTH AND REHABILITATION

FORENSIC AGE ESTIMATION BASED ON THE FUSION OF ILIAC CREST EPIPHYSIS ON PELVIC X-RAYS

Original Research

Anwar Ul Haq[1], Naheed Siddiqui[1]*
[1]Forensic Medicine and Toxicology, Khyber Girls Medical College Hayatabad, Peshawar

Corresponding Author: Naheed Siddiqui, Assistant Professor, Forensic Medicine and Toxicology, Khyber Girls Medical College Hayatabad, Peshawar, naheedsiddiqui@ymail.com
DOI: https://doi.org/10.71000/cz022260
Conflict of Interest: None
Grant Support & Financial Support: None

ABSTRACT

Background: Forensic age estimation plays a crucial role in medico-legal investigations, immigration cases, and criminal proceedings. Skeletal maturity indicators such as iliac crest ossification have been widely studied to assess chronological age. While conventional radiography has been frequently used for age estimation, variability in ossification timelines across populations necessitates further validation. The iliac crest apophysis follows a predictable maturation pattern, making it a valuable marker for forensic age determination. This study evaluates the reliability of iliac crest ossification staging in forensic age estimation using pelvic X-rays.

Objective: To assess the ossification status of the iliac crest apophysis in individuals aged 10 to 29 years using Kreitner's four-stage classification and determine its applicability in forensic age estimation.

Methods: A retrospective cross-sectional study was conducted at Hayatabad Medical Complex, Peshawar, involving 549 individuals who underwent pelvic X-rays between January 2023 and August 2024. Participants included 277 females (50.5%) and 272 males (49.5%), aged 10–29 years. Digital pelvic radiographs were analyzed by an experienced radiologist blinded to patient age. Iliac crest ossification was classified into four stages: stage 1 (absence of ossification), stage 2 (ossification without apophyseal fusion), stage 3 (partial fusion), and stage 4 (complete fusion). Spearman's correlation was used to assess the relationship between age and ossification stages, with $P < 0.05$ considered statistically significant.

Results: Stage 2 ossification was first observed at 12 years in females and 13 years in males. Stage 3 was first detected at 15 years in females and 17 years in males. Stage 4 ossification was identified at a minimum age of 17 years in males on both sides of the pelvis, while in females, it appeared at 20 years on the right iliac crest. The maximum observed age for stage 2 was 24 years in females and 25 years in males, while stage 3 and 4 ossification extended up to 28 years. A significant correlation was observed between age and iliac crest ossification ($P = 0.0001$), with correlation coefficients of $r = 0.719$ (right) and $r = 0.716$ (left) in males and $r = 0.724$ (right) and $r = 0.700$ (left) in females.

Conclusion: Iliac crest ossification assessed via conventional radiography provides a reliable skeletal marker for forensic age estimation. When used alongside other skeletal maturity indicators, this method enhances the accuracy of age determination. Further research with larger and diverse populations is needed to standardize age estimation criteria for forensic and clinical applications. Iliac crest ossification assessed via conventional radiography provides a reliable skeletal marker for forensic age estimation. When used alongside other skeletal maturity indicators, this method enhances the accuracy of age determination. Further research with larger and diverse populations is needed to standardize age estimation criteria for forensic and clinical applications.

Keywords: Age estimation, forensic anthropology, iliac crest, ossification, pelvic radiography, skeletal maturity, X-ray

© 2024 et al. Open access under CC BY License (Creative Commons). Freely distributable with appropriate citation.

INSIGHTS-JOURNAL OF
HEALTH AND REHABILITATION

INSIGHTS-JHR
INSIGHTS-JOURNAL OF HEALTH AND REHABILITATION

INTRODUCTION

Forensic age estimation plays a pivotal role in legal medicine, assisting in criminal investigations, immigration cases, and the identification of unknown individuals. Various skeletal and dental markers have been utilized for age determination, with the iliac crest epiphysis emerging as a significant indicator due to its well-defined ossification and fusion patterns. The assessment of the iliac crest on pelvic radiographs provides a non-invasive and practical approach to estimating chronological age, particularly in late adolescence and early adulthood. As skeletal development progresses, the secondary ossification center of the iliac crest appears during puberty and gradually fuses with the main iliac bone, following a predictable sequence that makes it a reliable anatomical marker for forensic and clinical age estimation (1). The timing of iliac crest epiphyseal fusion varies among individuals and populations, influenced by genetic, environmental, and nutritional factors. The ossification process typically begins between the ages of 13–15 years in females and 14–16 years in males. As maturation advances, partial fusion becomes evident between 16 and 20 years, with complete fusion occurring between 20 and 25 years. Notably, females generally exhibit earlier fusion than males, a pattern observed in numerous skeletal maturation studies (2). Previous research has explored the ossification of different anatomical structures for forensic age estimation, highlighting skeletal indicators such as the clavicle, hand-wrist, and iliac crest. Studies have consistently reported that iliac crest fusion correlates strongly with chronological age, making it a valuable criterion for forensic analysis (3).

Several key investigations have reinforced the reliability of this method. A study underscored the significance of skeletal and dental markers in forensic assessments, while another study specifically examined iliac crest epiphysis and confirmed its utility for age estimation. (4). More recently, researchers have analyzed that iliac crest fusion in male and female adolescents, reaffirming its forensic potential, while another researcher extended the research by incorporating digital X-ray assessments of both the iliac crest and ischial tuberosity (5). Despite the growing body of evidence, the accuracy and reliability of age estimation based on iliac crest fusion require further validation. Much of the existing literature has focused on clavicular and hand-wrist ossification, with fewer studies systematically evaluating the forensic applicability of iliac crest fusion (6). This study aims to analyze and evaluate the forensic potential of iliac crest epiphysis fusion on pelvic X-rays, assessing its correlation with chronological age and developing a predictive model for forensic investigations. By addressing existing gaps in research, this study seeks to enhance the accuracy of forensic age estimation, contributing to improved methodologies in legal medicine.

METHODS

This retrospective cross-sectional study was conducted at Hayatabad Medical Complex, Peshawar, from January 2023 to August 2024, to estimate forensic age based on iliac crest epiphyseal fusion observed in pelvic X-rays. Ethical approval was obtained from the Institutional Review Board (IRB) of Hayatabad Medical Complex, and informed consent was secured from all participants or their legal guardians where applicable. No additional radiation exposure was administered beyond standard clinical imaging protocols to ensure patient safety and compliance with ethical guidelines (7). A total of 549 participants, including both males and females aged 10–29 years, were enrolled in the study. Participants were individuals who underwent radiographic imaging for medical reasons such as trauma, abdominal pain, and other non-skeletal conditions. Exclusion criteria included individuals with bone growth-affecting conditions such as metabolic disorders, iliac crest fractures, bone prostheses, tumors, or imaging artifacts. Medical records were reviewed to confirm the absence of skeletal development abnormalities, ensuring the integrity of the dataset (8).

Radiographic evaluations were performed using digital X-ray imaging to assess the ossification status of the iliac crest apophysis. Standardized pelvic radiographs were acquired with optimized exposure settings to ensure clear visualization of bone structures. An experienced radiologist, blinded to the participants' chronological age, analyzed the images to minimize observer bias. The ossification process was classified based on Kreitner's four-stage criteria: Stage 1—absence of an ossification center; Stage 2—presence of an ossification center without ossification of the apophyseal cartilage; Stage 3—partial ossification of the apophyseal cartilage; and Stage 4—complete ossification of the apophyseal cartilage. Representative radiographic images illustrating each stage were documented to enhance the study's reproducibility. The methodology also accounted for potential variations in ossification patterns due to genetic, environmental, and nutritional influences (9). Statistical analyses were conducted using SPSS (version 25). Spearman's correlation analysis was performed to assess the relationship between chronological age and iliac crest ossification stages. A significance level of $P < 0.05$ was considered statistically significant to determine the predictive reliability of iliac crest fusion for forensic age estimation (10).

© 2024 et al. Open access under CC BY License (Creative Commons). Freely distributable with appropriate citation.

INSIGHTS-JHR
INSIGHTS-JOURNAL OF HEALTH AND REHABILITATION

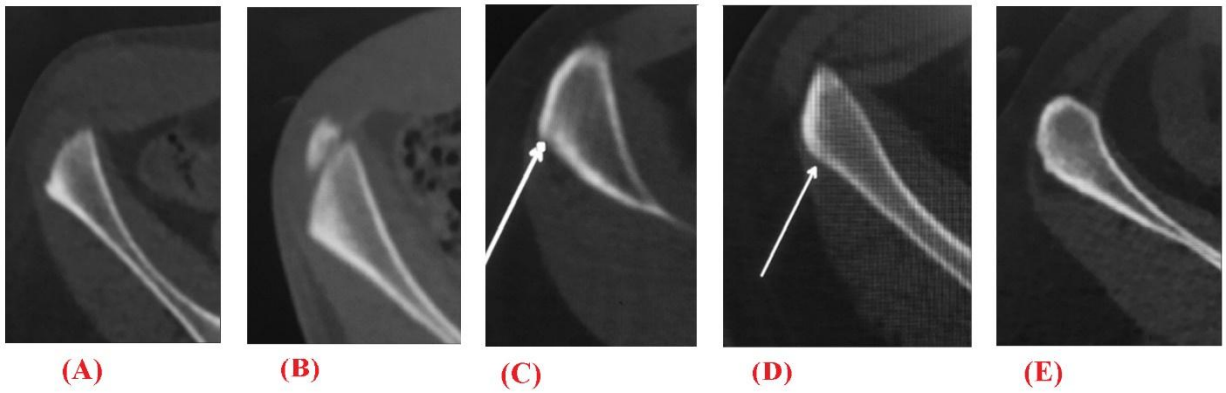

(A) Sectional CT axial image of stage 1: The ossification center has not clinically ossified yet**. (B)** Sectional CT axial image of stage 2: The ossification center has been ossified, apophyseal cartilage has not ossified **(C), (D)** Sectional CT axial image of stage 3: The cartilage has been partially calcified **(E)** Sectional CT axial image of stage 4: The apophyseal cartilage has fully ossified

RESULTS

A total of 549 pelvic radiographs were analyzed, comprising 277 females (50.5%) and 272 males (49.5%), with participants aged between 10 and 29 years. The mean age was 22.93 ± 4.85 years, and no statistically significant difference was observed between male and female age distributions (P = 0.113). Ossification stages were assessed based on Kreitner's classification, demonstrating a structured pattern of iliac crest fusion progression. The earliest observation of stage 2 ossification occurred at 12 years in females and 13 years in males. Stage 3 ossification was first noted at 15 years in females and 17 years in males. Complete fusion, categorized as stage 4, was detected at a minimum age of 17 years in males, whereas in females, it first appeared at 20 years on the right iliac crest. The ossification process varied slightly between the right and left iliac crests. Comparative analysis of ossification between both sides revealed a significant difference in iliac crest maturation in approximately 49 participants (31 males and 18 females) (P = 0.001). Correlation analysis demonstrated a strong positive relationship between chronological age and iliac crest ossification, with Spearman's correlation coefficients of r = 0.719 (right side) and r = 0.716 (left side) in males and r = 0.724 (right side) and r = 0.700 (left side) in females, all with P < 0.0001. The findings indicate that iliac crest ossification follows a predictable sequence, with females consistently exhibiting earlier fusion than males.

Descriptive statistics for ossification stages revealed stage-specific trends. For stage 1, the mean age was 11.40 ± 1.60 years in females and 13.60 ± 3.35 years in males on the right side, whereas on the left side, the mean ages were 11.00 ± 1.61 years and 13.57 ± 3.38 years, respectively. In stage 2, mean ages were 17.80 ± 2.85 years in females and 18.10 ± 3.08 years in males on the right, with corresponding values of 17.67 ± 2.96 years and 17.89 ± 2.89 years on the left. Progressing to stage 3, mean ages were 23.90 ± 3.10 years in females and 22.95 ± 3.05 years in males on the right side, and 23.76 ± 3.16 years in females and 22.87 ± 3.16 years in males on the left side. For stage 4, fusion was observed at a mean age of 26.65 ± 2.20 years in females and 26.10 ± 2.55 years in males on the right, while on the left side, mean ages were 26.35 ± 2.34 years in females and 25.98 ± 2.59 years in males. These findings reaffirm the reliability of iliac crest fusion as an indicator of skeletal maturity and chronological age.

Table: Descriptive Statistics of Iliac Crest Ossification Stages on the Right Side of the Pelvis. Mean age, minimum-maximum age range, interquartile range (IQR), and median (LQ-UQ) for different ossification stages in males and females based on Kreitner's classification.

Stage	Gender	N	Mean Age ± SD	Min-Max Age	IQR	Median (LQ-UQ)
1	Female	15	11.40 ± 1.60	10 - 15	1	11.50 (10.00 - 10.50)
	Male	9	13.60 ± 3.35	10 - 25	1	14.30 (11.00 - 13.50)
2	Female	46	17.80 ± 2.85	12 - 25	4	19.80 (16.00 - 17.50)
	Male	40	18.10 ± 3.08	13 - 26	3	19.20 (16.00 - 18.00)
3	Female	108	23.90 ± 3.10	15 - 29	4	26.00 (22.00 - 24.50)

© 2024 et al. Open access under CC BY License (Creative Commons). Freely distributable with appropriate citation.

	Male	111	22.95 ± 3.05	17 - 29	4	25.00 (21.00 - 23.50)
4	Female	110	26.65 ± 2.20	20 - 29	3	28.00 (25.00 - 27.50)
	Male	110	26.10 ± 2.55	17 - 29	3	28.00 (25.00 - 27.50)

Table: Mean, Minimum and Maximum Age, Median, and IQR in All Stages of the Iliac Crest on the Left Side of the Pelvis

Stage	Gender	N. of Individuals	Min-Max	Mean ± SD	IQR	Median; LQ; UQ
1	Female	15	10-15	11.00 ± 1.61	1	11.25; 10.00; 10
	Male	21	10-25	13.57 ± 3.38	4	14.50; 11.00; 13
2	Female	44	12-25	17.67 ± 2.96	3	19.75; 16.00; 17
	Male	39	13-26	17.89 ± 2.89	4	19.00; 16.00; 18
3	Female	97	15-29	23.76 ± 3.16	5	26.00; 21.00; 24
	Male	109	17-29	22.87 ± 3.16	4	25.00; 21.00; 23
4	Female	117	18-29	26.35 ± 2.34	3	28.00; 25.00; 27
	Male	107	17-29	25.98 ± 2.59	3	28.00; 25.00; 27

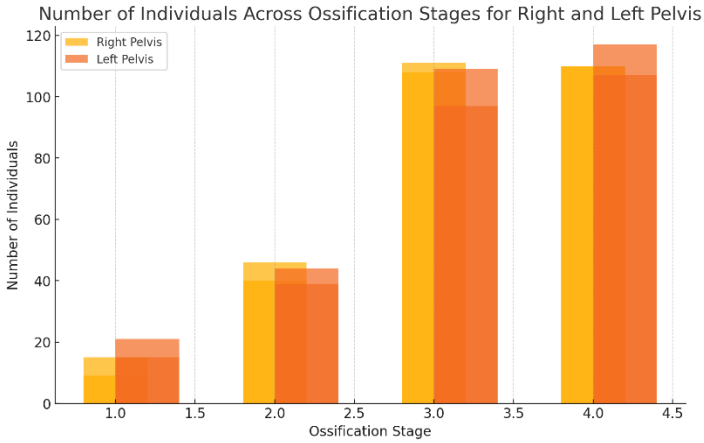

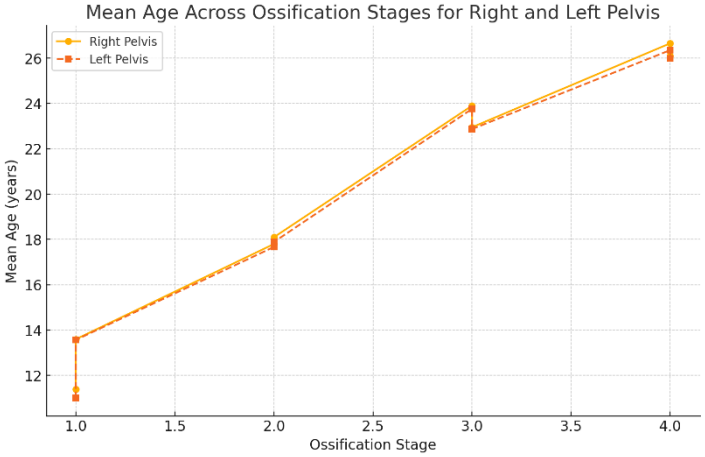

DISCUSSION

The findings of this study indicate that the iliac crest apophysis follows a well-defined ossification pattern, reinforcing its reliability as a marker for forensic age estimation. The progression from stage 2 to stage 4 occurred within expected age ranges, with stage 2 first appearing at 12 years in females and 13 years in males. Stage 3 ossification was observed at 15 years in females and 17 years in males, while stage 4 fusion was detected in males at 17 years and in females at 20 years on the right iliac crest. These results align with previously established classification systems, which have demonstrated similar ossification timelines, though minor discrepancies exist due to variations in imaging modalities, study populations, and the expertise of evaluators assessing the ossification process in computed tomography (CT) images (11,12). The consistency of iliac crest ossification stages across multiple studies highlights its applicability in forensic contexts. Prior research utilizing the four-stage classification system reported minimum ages of 12 years for stage 2 and 14 years for stage 3 in both genders. Stage 4 ossification has been documented at 17 years for both males and females, with slight differences between the right and left iliac crests. These findings closely correspond with the current study, further supporting the forensic validity of this classification system. Some studies have included an additional stage beyond complete ossification, describing stage 5 with a minimum observed age of 18 years in both sexes, though this classification was not part of the present study. The omission of this stage may limit direct comparisons with studies utilizing a five-stage classification system (13,14).

Differences in findings across studies may be attributed to imaging techniques and socioeconomic factors affecting skeletal development. Studies employing conventional radiography have reported challenges in accurately assessing iliac crest maturation due to projection artifacts and superimposition of structures, which can obscure fusion lines. Cross-sectional imaging techniques such as CT and magnetic

© 2024 et al. Open access under CC BY License (Creative Commons). Freely distributable with appropriate citation.

INSIGHTS-JHR
INSIGHTS-JOURNAL OF HEALTH AND REHABILITATION

resonance imaging (MRI) provide more precise evaluations by eliminating projection errors and allowing detailed multiplanar reconstructions. CT imaging, in particular, has demonstrated superior accuracy in forensic age estimation due to its ability to distinguish subtle ossification changes. However, it has inherent limitations, including increased radiation exposure, particularly to the gonadal region, which restricts its widespread application in forensic assessments. While protective shielding can mitigate radiation exposure, the necessity of balancing diagnostic accuracy with patient safety remains an important consideration (15,16). The findings of this study revealed that ossification stages 2 and 3 demonstrated a wide age range, with a maximum age of 24 years in females and 25 years in males at stage 2, and a maximum age of 28 years at stage 3. The presence of individuals with delayed fusion underscores the influence of genetic, environmental, and nutritional factors on skeletal maturation. Socioeconomic status has been recognized as a critical determinant of bone development, with delayed ossification frequently reported in populations with lower nutritional access and healthcare disparities. These factors should be carefully considered when applying iliac crest fusion as an age estimation criterion across diverse populations, necessitating further research to account for regional and ethnic variability (17,18).

Although CT imaging offers precise skeletal evaluations, alternative methods such as wrist radiography provide significant advantages due to lower radiation exposure, accessibility, and affordability. The medial clavicular epiphysis and hand-wrist ossification have long been utilized for skeletal age assessment and remain standard forensic markers. Integrating iliac crest assessment with established skeletal indicators may enhance the accuracy of forensic age determination by providing supplementary evidence for individuals in late adolescence and early adulthood. Given the forensic importance of distinguishing between minors and adults, refining age estimation models using multiple skeletal sites may offer a more comprehensive approach to legal and medico-legal investigations (19,20). The strengths of this study include the use of a robust classification system, a relatively large sample size, and standardized imaging protocols that ensured consistent data collection. The blinding of radiologists to patient ages minimized observer bias, enhancing the reliability of ossification stage classification. However, certain limitations should be acknowledged. The study did not account for interobserver variability, which may influence the consistency of radiological assessments. Additionally, the lack of socioeconomic and nutritional data for participants restricts the ability to evaluate external factors affecting bone maturation. Future research should focus on expanding sample diversity, incorporating advanced imaging techniques with reduced radiation exposure, and developing predictive models that integrate multiple skeletal markers for improved forensic age estimation.

CONCLUSION

The findings of this study reinforce the reliability of computed tomography as a valuable tool for forensic age estimation, particularly in assessing skeletal maturity through iliac crest ossification. By providing precise visualization of ossification stages, this method enhances the accuracy of age determination, especially in medico-legal contexts where additional verification is required. Integrating CT imaging with other skeletal assessment techniques strengthens forensic evaluations by offering a more comprehensive understanding of bone development. However, the absence of universally standardized protocols presents a challenge in establishing consistent criteria for age estimation. Further research is essential to refine imaging-based methodologies, enhance their applicability across diverse populations, and ensure their integration into forensic and clinical practice with greater accuracy and reliability.

AUTHORS' CONTRIBUTION

Author	Contribution
Anwar Ul Haq	Conceptualization, Methodology, Formal Analysis, Writing - Original Draft, Validation, Supervision Software, Validation, Writing - Original Draft
Naheed Siddiqui	Methodology, Investigation, Data Curation, Writing - Review & Editing Investigation, Data Curation, Formal Analysis, Software

REFERENCES

1. Babu, G. R., & Johnson, A. (2023). Medicolegal Investigation-Non-Invasive Procedures for The Criminal and Routine Human Identification: Prospective and Prolific Determinants for Profiling. Forensic Science and Human Rights, 91.

2. Chauvin, N. A. (2024, August). Pediatric Pelvis. In Seminars in Musculoskeletal Radiology (Vol. 28, No. 04, pp. 437-446). Thieme Medical Publishers, Inc..

3. Warrier, V., Shedge, R., Garg, P. K., Dixit, S. G., Krishan, K., & Kanchan, T. (2024). Machine learning and regression analysis for age estimation from the iliac crest based on computed tomographic explorations in an Indian population. Medicine, Science and the Law, 64(3), 204-216.

© 2024 et al. Open access under CC BY License (Creative Commons). Freely distributable with appropriate citation.

4. Edmonds, E. W., Hollnagel, K. F., Bomar, J. D., & Frick, S. L. (2023). AP radiographic assessment of the pediatric pelvis for developmental dysplasia of the hip. JAAOS-Journal of the American Academy of Orthopaedic Surgeons, 31(14), 717-726.

5. Schmeling, A., & Rudolf, E. (2022). Medical age assessment in living individuals. Handbook of Forensic Medicine, 2, 1027-1053.

6. Schmeling, A., & Geserick, G. (2024). Forensische Altersdiagnostik bei Lebenden. In Rechtsmedizin: Befunderhebung, Rekonstruktion, Begutachtung (pp. 721-731). Berlin, Heidelberg: Springer Berlin Heidelberg.

7. Maqsood, M., Bashir, M. Z. B. M. Z., Butt, M. K. B. M. K., & Maqsood, F. M. F. (2021). Epiphyseal Fusion of Iliac Crests in Male and Female Adolescents: An Age Estimation Criterion. Journal of Shalamar Medical & Dental College, 2(1), 11-21.

8. Bhardwaj, V., Kumar, I., Aggarwal, P., Singh, P. K., Shukla, R. C., & Verma, A. (2024). Demystifying the Radiography of Age Estimation in Criminal Jurisprudence: A Pictorial Review. Indian Journal of Radiology and Imaging, 34(03), 496-510.

9. Bascou A, Dubourg O, Telmon N, Dedouit F, Saint-Martin P, Savall F. Age estimation based on computed tomography exploration: a combined method. Int J Legal Med. 2021;135(6):2447-55.

10. Ost AM. Age-at-death estimation from the auricular surface of the ilium: A test of a sex-specific component method. J Forensic Sci. 2022;67(3):868-76.

11. Warrier V, Shedge R, Garg PK, Dixit SG, Krishan K, Kanchan T. Applicability of the Calce method for age estimation in an Indian population: A clinical CT-based study. Leg Med (Tokyo). 2022;59:102113.

12. Warrier V, Kanchan T, Garg PK, Dixit SG, Krishan K, Shedge R. CT-based evaluation of the acetabulum for age estimation in an Indian population. Int J Legal Med. 2022;136(3):785-95.

13. Campanacho V, Chamberlain AT, Nystrom P, Cunha E. Degenerative variance on age-related traits from pelvic bone articulations and its implication for age estimation. Anthropol Anz. 2020;77(3):259-68.

14. Fan F, Dong X, Wu X, Li R, Dai X, Zhang K, et al. An evaluation of statistical models for age estimation and the assessment of the 18-year threshold using conventional pelvic radiographs. Forensic Sci Int. 2020;314:110350.

15. Stock MK, Garvin HM, Corron LK, Hulse CN, Cirillo LE, Klales AR, et al. The importance of processing procedures and threshold values in CT scan segmentation of skeletal elements: An example using the immature os coxa. Forensic Sci Int. 2020;309:110232.

16. Monge Calleja Á M, Luna LH, Aranda CM, Santos AL. Methods for sex estimation of prepubertal individuals (< 12 years old): bibliographic review and future directions. Anthropol Anz. 2023;80(4):439-69.

17. Epain M, Valette S, Zou K, Faisan S, Heitz F, Croisille P, et al. Sex estimation from coxal bones using deep learning in a population balanced by sex and age. Int J Legal Med. 2024;138(6):2617-23.

18. Garvin HM, Stock MK, Marciniec KA, Mohamed MM, Ternent E, Cirillo LE, et al. Sex estimation of the subadult ilium prior to acetabular fusion. J Forensic Sci. 2021;66(6):2113-25.

19. Kuchař M, Henyš P, Rejtar P, Hájek P. Shape morphing technique can accurately predict pelvic bone landmarks. Int J Legal Med. 2021;135(4):1617-26.

20. Imai N, Funayama K, Suzuki H, Tsuchiya K, Nozaki A, Minato I, et al. Stature estimation formulae based on bony pelvic dimensions and femoral length. Homo. 2020;71(2):111-9.

© 2024 et al. Open access under CC BY License (Creative Commons). Freely distributable with appropriate citation.