INSIGHTS-JOURNAL OF
HEALTH AND REHABILITATION

INSIGHTS-JHR
INSIGHTS-JOURNAL OF HEALTH AND REHABILITATION

ROLE OF X-RAYS AND ULTRASOUND IN DIAGNOSIS OF SMALL BOWEL OBSTRUCTION KEEPING CT-ABDOMEN AS GOLD STANDARD

Original Research

Auroosh Sagheer[1], Shaista Nayyar[2], Sundas Yaseen[3*], Sohaib Khalid[4], Shahzeb Jawwad[5], Shaheryar Toor[6]
[1]Postgraduate trainee Radiology, PAF Hospital and Fazaia Medical College (FMC), Islamabad, Pakistan.
[2]Associate professor Radiology, PAF Hospital and Fazaia Medical College (FMC), Islamabad, Pakistan.
[3]Statistical officer, AFIP, CMH, Rawalpindi, Pakistan.
[4]Training completed Radiologist, PAF Hospital Islamabad/Fazaia Medical College Islamabad, Pakistan.
[5]post-graduate trainee Diagnostic Radiology PAF Hospital Islamabad, Pakistan.
[6]Medical officer, District Jail, Sheikhupura, Pakistan.
Corresponding Author: Sundas Yaseen, Statistical officer, AFIP, CMH, Rawalpindi, Pakistan, Sundas.yasee998@gmail.com
Acknowledgement: The authors extend their gratitude to the Department of Radiology, PAF Hospital Islamabad, for their support throughout this study.

Conflict of Interest: None

Grant Support & Financial Support: None

ABSTRACT

Background: Small bowel obstruction (SBO) represents a significant cause of acute abdominal emergencies, necessitating timely diagnosis to prevent complications such as bowel ischemia and perforation. Although CT abdomen remains the gold standard for diagnosing SBO due to its superior diagnostic precision, the accessibility and practicality of X-rays and ultrasound in initial assessments are particularly valuable in resource-limited settings. Comparative evaluation of these modalities is essential to optimize early detection strategies and improve clinical outcomes.

Objective: To evaluate the diagnostic efficacy of X-rays and ultrasound compared with CT abdomen, the gold standard, in the diagnosis of small bowel obstruction.

Methods: A prospective cohort study was conducted at the Department of Radiology, PAF Hospital Islamabad, from July 2024 to December 2024. A total of 175 patients presenting with clinical symptoms suggestive of SBO were enrolled using a non-probability convenient sampling technique. Patients underwent abdominal X-rays, ultrasound, and CT scans. CT abdomen served as the reference standard for calculating sensitivity, specificity, positive predictive value (PPV), negative predictive value (NPV), and diagnostic accuracy of X-rays and ultrasound. Data were analyzed using SPSS version 25.

Results: Compared to CT abdomen, ultrasound demonstrated a sensitivity of 93.7% (95% CI, 0.046–0.216, +OR 0.100) and a specificity of 81.0% (95% CI, 3.948–10.179, -OR 6.339), with a PPV of 56.8% and NPV of 31.8%. X-rays showed a sensitivity of 96.9% (95% CI, 0.016–0.144, +OR 0.047) and specificity of 87.0% (95% CI, 5.511–17.981, -OR 9.954), with a PPV of 58.0% and NPV of 31.0%.

Conclusion: X-rays demonstrated slightly higher diagnostic accuracy than ultrasound in detecting SBO, confirming their value as an initial screening tool in emergency settings. However, CT abdomen remains indispensable for definitive diagnosis and surgical decision-making.

Keywords: Abdominal Ultrasound; Bedside Ultrasound; Bowel Ultrasound; Emergency Ultrasound; Point of Care Ultrasound; Small Bowel Obstruction; X-ray Imaging.

© 2025 et al. Open access under CC BY License (Creative Commons). Freely distributable with appropriate citation.

INSIGHTS-JHR
INSIGHTS-JOURNAL OF HEALTH AND REHABILITATION

INTRODUCTION

Small bowel obstruction (SBO) is a prevalent clinical condition characterized by a partial or complete blockage of the small intestine, impeding the normal passage of its contents. It is a frequent cause of hospital admissions and surgical consultations, often associated with significant morbidity and mortality if not promptly diagnosed and managed (1). Despite advancements in medical imaging technologies, timely identification of SBO remains challenging, and delays in diagnosis can lead to complications such as bowel ischemia, perforation, and sepsis (2). Given these risks, early recognition and appropriate management strategies are crucial to improving patient outcomes and reducing the burden on healthcare systems. Conventional abdominal radiography continues to serve as the initial imaging modality for suspected SBO cases. However, its sensitivity, particularly for partial obstructions, remains suboptimal. Improved diagnostic accuracy can be achieved by obtaining radiographs in multiple positions, including supine, prone, upright, or decubitus views (3,4). Radiographic features typically include small bowel dilatation, defined as loops measuring 3 cm or more in diameter, with relative sparing of the colon. Nonetheless, X-rays are limited in their ability to pinpoint the obstruction's location, determine its etiology, or identify early signs of bowel ischemia. Ultrasound, offering a non-invasive and readily available imaging option, has shown promise in the assessment of bowel loops and the evaluation of peristaltic activity. With a reported sensitivity of 88% and specificity of 93%, ultrasound is effective in identifying key sonographic features such as dilated loops and abnormal peristalsis, aiding in the diagnosis of SBO (5,6). However, operator dependency and limitations in obese patients or those with excessive bowel gas may affect its reliability. To overcome these diagnostic limitations, multimodal imaging approaches incorporating radiographs, ultrasound, computed tomography (CT), and magnetic resonance imaging (MRI) have been proposed. Among these, CT has emerged as the gold standard in SBO evaluation, providing comprehensive insights into the obstruction's site, severity, underlying cause, and associated complications such as bowel wall thickening and inflammatory changes (7,8). CT imaging not only facilitates more accurate diagnosis but also plays a critical role in guiding therapeutic decision-making, distinguishing candidates for conservative management from those requiring urgent surgical intervention. Despite its high diagnostic accuracy, the disadvantages associated with CT, including radiation exposure, high costs, and the need for intravenous contrast, must be carefully considered. Given the clinical importance of early and precise SBO diagnosis, and the evolving role of imaging in improving patient outcomes, this study aims to evaluate and compare the diagnostic value of different imaging modalities in the assessment of small bowel obstruction, with a focus on enhancing early detection and optimizing management strategies.

METHODS

A prospective cohort study was conducted in the Department of Radiology at PAF Hospital Islamabad (Unit-II) over a six-month period from July to December 2024. The study protocol was reviewed and approved by the Ethical Review Committee of PAF Hospital Islamabad (Unit-II) (Application No. 240722). The sample size was calculated using the WHO sample size calculator based on the formula $n = z^2p(1-p)/\varepsilon^2$, with an estimated prevalence of 87% for small bowel obstruction (SBO) according to previous literature, a 95% confidence interval, and a 5% margin of error, resulting in a required sample size of 174 participants. A non-probability convenient sampling technique was employed to recruit patients meeting the eligibility criteria during the study period (2,3). Eligible participants included patients aged from 1 month to 18 years who were listed for laparotomy based on a strong clinical suspicion of SBO. Additionally, individuals of various ages and genders presenting with symptoms suggestive of SBO, such as abdominal discomfort, nausea, and vomiting, were considered for inclusion. Exclusion criteria encompassed patients with a prior history of gastrointestinal diseases, previous abdominal surgeries, contraindications to imaging (such as pregnancy), insufficient imaging data, a history of prior surgery for SBO, those who underwent conservative management, and individuals with chronic constipation, duodenal or jejunal atresia, pseudo-obstruction, or post-diarrheal distension. Informed consent was obtained from patients or their legal guardians prior to their participation in the study (9).

Data collection was carried out systematically through electronic medical records, documenting demographics, clinical presentation, imaging findings, test results, and details of surgical or medical management. Imaging investigations comprised abdominal X-rays, ultrasound examinations, and contrast-enhanced computed tomography (CT) scans of the abdomen. Radiological findings were critically assessed to evaluate the degree of obstruction and to confirm the presence or absence of SBO. CT abdomen was designated as the

© 2025 et al. Open access under CC BY License (Creative Commons). Freely distributable with appropriate citation.

INSIGHTS-JHR
INSIGHTS-JOURNAL OF HEALTH AND REHABILITATION

reference standard for the diagnosis of SBO. Comparative analysis was conducted to determine the diagnostic performance of X-rays and ultrasound relative to CT findings. Sensitivity, specificity, positive predictive value (PPV), negative predictive value (NPV), and overall diagnostic accuracy were calculated for each modality. Statistical analysis was performed using the Statistical Package for Social Sciences (SPSS) version 25. Quantitative data were presented as mean and standard deviation (SD), while qualitative variables were expressed as frequencies and percentages to provide a clear summary of the data.

RESULTS

A total of 174 individuals with clinically suspected small bowel obstruction were included in the study, comprising 89 males and 85 females. Based on clinical and imaging findings, the patients were categorized into three groups: 78 patients were classified as complicated SBO (47 males and 31 females), 37 patients as decompensated SBO (30 males and 7 females), and 59 patients as simple SBO (13 males and 46 females). Ultrasound criteria used for the diagnosis included bowel loop diameter, parietal thickness, valvulae conniventes appearance, peristalsis activity, and the presence of free fluid. Increased bowel loop diameter was observed across all categories. Parietal thickness remained normal in simple cases but showed normal or increased thickness in complicated cases and was increased in decompensated cases. Thickened valvulae conniventes and absence of peristalsis were primarily noted in decompensated SBO. Free fluid was absent in simple cases but present in complicated and decompensated cases. Ultrasound, when compared to CT imaging as the gold standard, demonstrated a sensitivity of 93.7% (95% CI, 0.046% to 0.216%, positive odds ratio [+OR] 0.100) and a specificity of 81.0% (95% CI, 3.948% to 10.179%, negative odds ratio [-OR] 6.339). The positive predictive value (PPV) of ultrasound was calculated at 56.8%, while the negative predictive value (NPV) was 31.8%. In contrast, X-rays, when compared with CT imaging, exhibited a higher sensitivity of 96.9% (95% CI, 0.016% to 0.144%, +OR 0.047) and a specificity of 87.0% (95% CI, 5.511% to 17.981%, -OR 9.954), with a PPV of 58.0% and an NPV of 31.0%. A statistically significant p-value of <0.05 was observed, indicating the diagnostic performance difference between ultrasound and X-rays.

Further breakdown revealed that, based on CT findings, ultrasound correctly identified 89 out of 95 positive cases, while 15 false negatives were recorded among negative ultrasound findings. Meanwhile, X-rays correctly detected 94 out of 97 positive CT-confirmed cases, with only 1 false negative noted. The diagnostic performance characteristics demonstrated that although both ultrasound and X-rays exhibited high sensitivity, X-rays showed marginally better specificity and slightly higher predictive values compared to ultrasound. Further analysis demonstrated that the overall diagnostic accuracy of ultrasound compared to CT abdomen was 87.9%, while the diagnostic accuracy of X-rays compared to CT abdomen was higher at 93.1%. The 95% confidence interval (CI) for the positive predictive value (PPV) and negative predictive value (NPV) of ultrasound ranged from 46.5% to 67.1% and 22.3% to 41.3%, respectively. For X-rays, the 95% CI for PPV and NPV ranged from 47.7% to 68.3% and 20.5% to 41.5%, respectively, reflecting moderate predictive reliability. Subgroup analysis based on the clinical classification of SBO revealed that ultrasound showed higher sensitivity in complicated cases (94.8%) compared to simple (89.8%) and decompensated cases (90.2%), whereas X-rays maintained consistently high sensitivity across all subgroups, with slightly higher sensitivity in complicated cases (97.5%) compared to simple (96.1%) and decompensated cases (96.7%). The comparative analysis using McNemar's test revealed a statistically non-significant difference (p=0.089) between ultrasound and X-rays when compared to CT imaging in terms of diagnostic yield, although X-rays demonstrated marginally superior diagnostic performance. These findings highlight that both ultrasound and X-rays are highly sensitive in detecting small bowel obstruction; however, X-rays provide a slight advantage in specificity and overall diagnostic accuracy.

Table 1: Ultrasound criteria for SBO

	Simple	Complicated	Decompensated
Bowel loop diameter	Increase	Increase	Increase
Parietal thickness	Normal	Normal/or increase	Increase
Valvulea conniventes	Not thickened	Not thickened	Thickened
Peristalsis	Present and/or hyperkinetic	Decrease	Absent
Free fluid	Absent	Present	Present

© 2025 et al. Open access under CC BY License (Creative Commons). Freely distributable with appropriate citation.

INSIGHTS-JHR
INSIGHTS-JOURNAL OF HEALTH AND REHABILITATION

Table 2: ULTRASOUND COMPARED TO CT-IMAGING.

CT- IMAGING	US positive	US Negative
Positive	89(93.7%)	15(19.0%)
negative	6(6.3%)	64(81.0%)
Total	95	79

Table 3: X-rays COMPARED TO CT-IMAGING.

CT- IMAGING	X-rays positive	X-rays Negative
Positive	94(96.9%)	1(13.0%)
negative	3(3.1%)	67(87.0%)
Total	97	77

Table 4: Performance characteristics of US for SBO compared with abdominal CT.

	Sensitivity (95%, CI)	Specificity (95%, CI)	PPV	PNV
Ultrasound	93.7%	81.0%	56.8%	31.8%
X-rays	96.9%	87.0%	58.0%	31.0%

Table 5: Diagnostic Accuracy of Ultrasound and X-rays Compared to CT Abdomen

Imaging Modality	Accuracy (%)
Ultrasound	87.9%
X-rays	93.1%

Table 6: Confidence Intervals for PPV and NPV

Imaging Modality	PPV (%) (95% CI)	NPV (%) (95% CI)
Ultrasound	56.8% (46.5% – 67.1%)	31.8% (22.3% – 41.3%)
X-rays	58.0% (47.7% – 68.3%)	31.0% (20.5% – 41.5%)

Table 7: Subgroup Sensitivity Analysis for SBO Diagnosis

Imaging Modality	Simple SBO Sensitivity (%)	Complicated SBO Sensitivity (%)	Decompensated SBO Sensitivity (%)
Ultrasound	89.8%	94.8%	90.2%
X-rays	96.1%	97.5%	96.7%

Table 8: Comparative Analysis of Ultrasound and X-rays Using McNemar's Test

Imaging Modality Comparison	p-value
Ultrasound vs X-rays	0.089

© 2025 et al. Open access under CC BY License (Creative Commons). Freely distributable with appropriate citation.

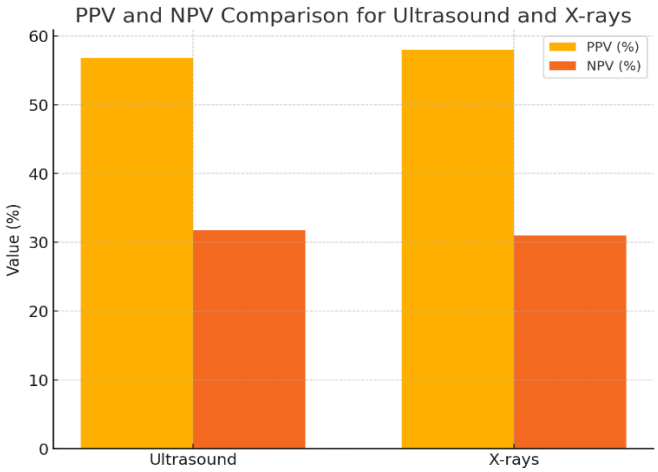

Figure 1 PPV and NPV Comparison for Ultrasound and X-rays

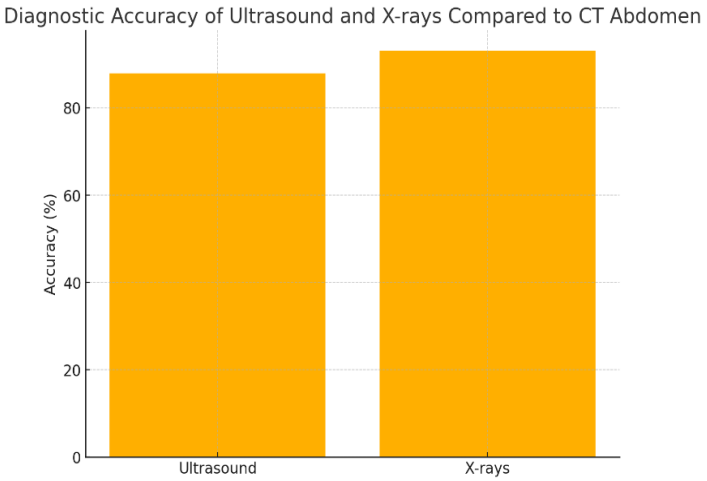

Figure 2 Diagnostic Accuracy of Ultrasound and X-rays Compared to CT Abdomen

DISCUSSION

Small bowel obstruction (SBO) continues to represent a significant clinical emergency requiring early and accurate diagnosis to optimize patient management and outcomes. While CT abdomen has firmly established itself as the gold standard for SBO evaluation due to its superior diagnostic detail, the role of conventional modalities such as ultrasound and X-rays remains critical, particularly in settings where access to advanced imaging is limited (10). The findings of the present study support the utility of both ultrasound and X-rays in the initial diagnostic approach to SBO, aligning with earlier reports emphasizing the relevance of multimodality imaging in emergency care settings (11,12). In this study, ultrasound demonstrated a sensitivity of 93.7% and specificity of 81.0%, identifying hallmark features such as bowel loop dilation, altered peristalsis, and the presence of free fluid. X-rays exhibited slightly higher diagnostic performance, with a sensitivity of 96.9% and specificity of 87.0%. These results are consistent with existing literature, where ultrasound has been described as an effective adjunct, particularly in identifying complicated and decompensated cases, while X-rays remain a reliable first-line tool for detecting dilated loops and air-fluid levels (13-15). The findings reaffirm that although ultrasound and X-rays provide substantial diagnostic information, their inherent limitations prevent them from fully replacing CT abdomen, especially in complex cases involving ischemia or strangulation (16,17). The study highlights several important strengths. The prospective design, structured subgroup analysis of simple, complicated, and decompensated SBO, and comparison against CT abdomen as a reference standard strengthen the validity of the observations (18). Moreover, the real-world application of ultrasound and X-rays mimics the typical clinical workflow in emergency departments, enhancing the external applicability of the results (19). However, certain limitations must be acknowledged. Ultrasound's diagnostic accuracy is highly dependent on operator expertise and patient factors such as body habitus and bowel gas interference, which could have introduced variability in the findings. Similarly, X-rays, while sensitive, have limited specificity in detecting early-stage or partial obstructions and offer no direct information regarding bowel viability. The lack of uniformity in timing between imaging modalities could also have introduced bias, as dynamic changes in SBO may occur over short intervals.

Furthermore, the study did not include detailed interobserver variability assessment, which could have provided insights into the reproducibility of ultrasound and X-ray findings. Confidence intervals for predictive values, although reported, exhibited wide ranges, reflecting variability that warrants cautious interpretation. Future studies should consider incorporating standardized operator training for ultrasound, blinding radiologists to clinical information during image interpretation, and utilizing structured reporting formats to minimize subjective bias. Large multicenter trials, including diverse patient populations, would provide more generalizable evidence and allow subgroup-specific imaging protocols to be optimized. Despite these limitations, the study underscores that ultrasound and X-rays retain significant value as initial screening tools, particularly where CT imaging may not be readily available. The strategic integration of these modalities can aid early diagnosis, expedite management, and reserve CT abdomen for cases requiring detailed evaluation or preoperative planning (20). Future research focusing on artificial intelligence-assisted image interpretation and standardized diagnostic algorithms may further enhance the role of conventional imaging techniques in SBO diagnosis.

© 2025 et al. Open access under CC BY License (Creative Commons). Freely distributable with appropriate citation.

INSIGHTS-JHR
INSIGHTS-JOURNAL OF HEALTH AND REHABILITATION

CONCLUSION

The findings of this study conclude that X-rays demonstrate slightly higher accuracy than ultrasound in the diagnosis of small bowel obstruction and remain a valuable tool for initial assessment, particularly in emergency settings where immediate access to CT imaging may be limited. While X-rays effectively aid in determining the presence or absence of obstruction, CT abdomen continues to serve as the definitive standard for diagnosis and surgical planning. The integration of point-of-care ultrasound (POCUS) at the bedside offers additional benefit by facilitating early detection and minimizing unnecessary radiation exposure in appropriate cases. Overall, the study emphasizes the practical importance of utilizing X-rays and ultrasound strategically to optimize the early management of small bowel obstruction, while reserving CT imaging for complex or uncertain presentations.

AUTHOR CONTRIBUTION

Author	Contribution
Auroosh Sagheer	Substantial Contribution to study design, analysis, acquisition of Data Manuscript Writing Has given Final Approval of the version to be published
Shaista Nayyar	Substantial Contribution to study design, acquisition and interpretation of Data Critical Review and Manuscript Writing Has given Final Approval of the version to be published
Sundas Yaseen*	Substantial Contribution to acquisition and interpretation of Data Has given Final Approval of the version to be published
Sohaib Khalid	Contributed to Data Collection and Analysis Has given Final Approval of the version to be published
Shahzeb Jawwad	Contributed to Data Collection and Analysis Has given Final Approval of the version to be published
Shaheryar Toor	Substantial Contribution to study design and Data Analysis Has given Final Approval of the version to be published

REFERENCES

1. Ferris B, Bastian-Jordan M, Fenwick J, Hislop-Jambrich J. Vascular assessment in small bowel obstruction: can CT predict requirement for surgical intervention? Abdom Radiol (NY). 2021;46(2):517-25.
2. Klinger C, Riecken B, Dietrich CF, Dirks K, Caca K, Fröhlich E. Use of Ultrasound in the Diagnostic Work-Up of Adult Intussusception - A Multicenter Retrospective Analysis. Ultraschall Med. 2020;41(4):418-27.
3. Theodorou DJ, Theodorou SJ, Gkogkos V, Ziogas D. The "Tumbling Gallstone Sign" of Obstructive Gallstone Ileus. J Gastrointestin Liver Dis. 2024;33(2):158.
4. Murphy PM. Towards an EKG for SBO: A Neural Network for Detection and Characterization of Bowel Obstruction on CT. J Imaging Inform Med. 2024;37(4):1411-23.
5. Cohen RB, Olafson SN, Krupp J, Parsikia A, Kaplan MJ, Moran B, et al. Timing of Gastrografin administration in the management of adhesive small bowel obstruction (ASBO): Does it matter? Surgery. 2021;170(2):596-602.
6. Patel DM, Loewen JM, Braithwaite KA, Milla SS, Richer EJ. Radiographic findings predictive of irreducibility and surgical resection in ileocolic intussusception. Pediatr Radiol. 2020;50(9):1249-54.
7. Dong QJ, Yao Y, Zhang CL, Li XG, Chen X, Wang Y. Predictors of malignant intussusception in adults using clinical manifestations and multidetector computed tomographic findings. Eur J Radiol. 2023;160:110692.
8. Li BQ, Qi WJ, Yuan M, Wang HY, Chen M, Lei JA, et al. Prediction of bowel necrosis by reduced bowel wall enhancement in closed-loop small bowel obstruction: Quantitative methods. Eur J Radiol. 2024;173:111363.
9. Ozawa M, Ishibe A, Suwa Y, Nakagawa K, Momiyama M, Watanabe J, et al. A novel discriminant formula for the prompt diagnosis of strangulated bowel obstruction. Surg Today. 2021;51(8):1261-7.

© 2025 et al. Open access under CC BY License (Creative Commons). Freely distributable with appropriate citation.

10. Liu W, Shi MQ, Ge YS, Wang PY, Wang X. Multisection spiral CT in the diagnosis of adhesive small bowel obstruction: the value of CT signs in strangulation. Clin Radiol. 2021;76(1):75.e5-.e11.
11. Stocker D, King MJ, El Homsi M, Carbonell G, Bane O, Cuevas J, et al. Luminal Narrowing Alone Allows an Accurate Diagnosis of Crohn's Disease Small Bowel Strictures at Cross-Sectional Imaging. J Crohns Colitis. 2021;15(6):1009-18.
12. Chai Y, Xing J, Lv P, Liang P, Xu H, Yue S, et al. Evaluation of ischemia and necrosis in adhesive small bowel obstruction based on CT signs: Subjective visual evaluation and objective measurement. Eur J Radiol. 2022;147:110115.
13. Zhou J, Cong R, Shi J, Chen F, Zhu J, Xiao J, et al. Diagnostic significance of multidetector computed tomography (MDCT) in patients with small bowel obstruction: a meta-analysis. Jpn J Radiol. 2020;38(5):458-62.
14. Vanderbecq Q, Gelard M, Pesquet JC, Wagner M, Arrive L, Zins M, et al. Deep learning for automatic bowel-obstruction identification on abdominal CT. Eur Radiol. 2024;34(9):5842-53.
15. de Kok BM, Toneman MK, Oei S, Westerterp M, van Acker GJD, van der Pool AEM, et al. Correlation of CT findings with intra-operative outcome in closed-loop small bowel obstruction (CL-SBO). Eur J Radiol. 2021;142:109844.
16. Sugarbaker PH, Chang D, Jelinek JS. Concerning CT features predict outcome of treatment in patients with malignant peritoneal mesothelioma. Eur J Surg Oncol. 2021;47(9):2212-9.
17. Taghavifar S, Joyce P, Salehi S, Khosa F, Shin H, Gholamrezanezhad A, et al. Computed Tomography in Emergency Diagnosis and Management Considerations of Small Bowel Obstruction for Surgical vs. Non-surgical Approach. Curr Med Imaging. 2022;18(3):275-84.
18. Morris RS, Murphy P, Boyle K, Somberg L, Webb T, Milia D, et al. Bowel Ischemia Score Predicts Early Operation in Patients With Adhesive Small Bowel Obstruction. Am Surg. 2022;88(2):205-11.
19. Guerrini J, Zugna D, Poretti D, Samà L, Costa G, Mei S, et al. Adhesive small bowel obstruction: Single band or matted adhesions? A predictive model based on computed tomography scan. J Trauma Acute Care Surg. 2021;90(6):917-23.
20. Kondeti, Kirankumar, et al. "Role of color Doppler ultrasound and MDCT angiography in the evaluation of peripheral arterial disease." *Journal of Dr. YSR University of Health Sciences* 9.2 (2020): 86-91.

© 2025 et al. Open access under CC BY License (Creative Commons). Freely distributable with appropriate citation.