INSIGHTS-JOURNAL OF
HEALTH AND REHABILITATION

INSIGHTS-JHR
INSIGHTS-JOURNAL OF HEALTH AND REHABILITATION

# NASAL ENDOSCOPY VS CONTRAST ENHANCED MRI PARANASAL SINUS, BETTER MODALITY FOR DIAGNOSING MUCORMYCOSIS

*Original Research*

**Shahzaib Shaukat Qureshi[1]*, Muhammad Umar Aasim[2], Wazir Feroze Ahmed[3], Tahir Liaquat[4], Nauman Jamil[5], Anoosha Zafar[6], Hamza Asad[7].**
[1]Registrar ENT CMH Peshawar, Pakistan.
[2]HOD Consultant ENT Department CMH Peshawar, Pakistan.
[3]Registrar CMH Lahore, Pakistan.
[4]Registrar ENT CMH Rawalpindi, Pakistan.
[5]Registrar CMH Kharian, Pakistan.
[6]Register CMH Rawalpindi, Pakistan.
[7]CMH Rawalpindi, Pakistan.
**Corresponding Author:** Shahzaib Shaukat, Registrar ENT CMH Peshawar, Pakistan, sc1932@live.com
**Acknowledgement:** The authors are grateful to the ENT Department of CMH Rawalpindi for their support during this study.

Conflict of Interest: None
Grant Support & Financial Support: None

## ABSTRACT

**Background:** Mucormycosis is a rapidly progressing, life-threatening fungal infection most commonly affecting immunocompromised individuals, especially those with uncontrolled diabetes or a history of corticosteroid use. Timely diagnosis is critical to reduce mortality and improve outcomes. In resource-constrained settings, identifying a single reliable diagnostic modality becomes essential to initiate prompt treatment. This study compares the diagnostic accuracy of nasal endoscopy and contrast-enhanced magnetic resonance imaging (MRI) against histopathology as the gold standard.

**Objective:** To compare the diagnostic accuracy of nasal endoscopy and contrast-enhanced MRI in the diagnosis of mucormycosis using histopathology as the reference standard.

**Methods:** This cross-sectional validation study was conducted at Combined Military Hospital (CMH), Rawalpindi, from January 2022 to 2024. A total of 82 patients aged ≥18 years presenting with clinical suspicion of mucormycosis were enrolled through non-probability consecutive sampling. All patients underwent nasal endoscopy, contrast-enhanced MRI of the brain, paranasal sinuses and orbits, and tissue biopsy for histopathological confirmation. Sensitivity, specificity, positive predictive value (PPV), negative predictive value (NPV), and diagnostic accuracy were calculated for both modalities. Data analysis was performed using SPSS version 22.

**Results:** The mean age of patients was 51.34 ± 11.54 years; 57 (69.51%) were male, and 25 (30.49%) were female. The mean BMI was 33.84 ± 4.54 kg/m², and mean HbA1c was 7.46 ± 1.63%. Sensitivity, specificity, PPV, NPV, and diagnostic accuracy of nasal endoscopy were 57.63%, 69.57%, 82.93%, 39.02%, and 60.98%, respectively. For contrast-enhanced MRI, these values were 83.05%, 78.26%, 90.74%, 64.29%, and 81.71%, respectively.

**Conclusion:** Contrast-enhanced MRI demonstrated significantly higher diagnostic accuracy than nasal endoscopy and should be preferred as the initial investigation in patients with suspected mucormycosis.

**Keywords:** Diagnostic imaging, Histopathology, Magnetic resonance imaging, Mucormycosis, Nasal endoscopy, Sensitivity and specificity, Tissue biopsy.

© 2024 et al. Open access under CC BY License (Creative Commons). Freely distributable with appropriate citation.

INSIGHTS-JOURNAL OF
HEALTH AND REHABILITATION

INSIGHTS-JHR
INSIGHTS-JOURNAL OF HEALTH AND REHABILITATION

## INTRODUCTION

Mucormycosis, also known as invasive fungal sinusitis, is a rare yet highly aggressive opportunistic fungal infection caused by fungi belonging to the order *Mucorales*, predominantly by *Rhizopus* species. In recent years, it has gained considerable attention due to its rising incidence in individuals with underlying immunocompromised states, including poorly controlled diabetes mellitus, malignancies, recipients of organ transplants, and patients receiving immunosuppressive or corticosteroid therapy (1,2). The disease primarily stems from the inhalation of *mucormycete* spores that are omnipresent in the environment, particularly in decaying organic matter such as soil, compost, and animal excreta (3). Once inside the body, these spores exploit weakened immune defenses to rapidly invade blood vessels and tissues, leading to necrosis and systemic dissemination. Clinically, mucormycosis can manifest in various forms, including rhinocerebral, pulmonary, cutaneous, gastrointestinal, and disseminated types. Among these, rhinocerebral mucormycosis remains the most commonly encountered subtype, especially in diabetic populations, typically involving the nasal cavity, paranasal sinuses, orbit, and occasionally, the central nervous system (4). Symptoms such as facial pain or swelling, nasal congestion or discharge, headache, proptosis, and visual disturbances often overlap with other sinus pathologies, making timely and accurate diagnosis challenging. Several physiological and iatrogenic risk factors further predispose individuals to mucormycosis. For instance, elevated serum iron levels—a characteristic of diabetic ketoacidosis or iron overload due to excessive supplementation—create a conducive environment for fungal growth (5). Similarly, traumatic injuries, burns, or postoperative wounds may serve as direct entry points for fungal spores, increasing the likelihood of cutaneous or disseminated infections (6).

Despite its alarming clinical course, mucormycosis remains a low-prevalence infection globally, but with a disproportionately higher burden in developing countries. Epidemiological data show that its incidence in resource-constrained settings may be up to 80 times higher than that in developed nations, with prevalence rates as high as 0.14 cases per 1,000 population (7). This elevated burden is compounded by diagnostic limitations. In ideal scenarios, diagnosis is based on a multifaceted approach combining clinical suspicion with imaging modalities such as computed tomography (CT) or magnetic resonance imaging (MRI), direct microscopy, histopathology, fungal cultures, and molecular or serological testing to confirm the diagnosis and identify the fungal species involved (8,9). However, in countries like Pakistan, such comprehensive diagnostic strategies are often unattainable due to economic constraints, inadequate laboratory infrastructure, and limited access to specialized testing techniques. Given these limitations, there is an urgent need to identify the most reliable standalone diagnostic modality that can facilitate early detection and treatment of mucormycosis in low-resource settings. This study, therefore, aims to compare the diagnostic efficacy of two commonly utilized diagnostic methods for mucormycosis, with the objective of determining the superior modality that may serve as a practical and effective single investigation in healthcare environments constrained by resources and accessibility.

## METHODS

This cross-sectional validation study was conducted at the indoor ENT Department of Combined Military Hospital, Rawalpindi, between January 2022 and 2024, following formal approval from the institutional ethical review committee. Written informed consent was obtained from all participants prior to their inclusion, and all ethical principles outlined in the Declaration of Helsinki were adhered to throughout the study. The sample size was determined using the WHO sample size calculator, with a confidence level of 95%, absolute precision of 8%, and an assumed mucormycosis prevalence of 16.3%, yielding a required sample size of 82 participants (10). Patients aged 18 years or older, of either gender, admitted with a clinical suspicion of mucormycosis were recruited using a non-probability consecutive sampling method. Clinical suspicion was defined as the presence of at least one of the following symptoms: nasal blockage with blackish nasal mucosal lesions, black patches on the palatal mucosa, facial pain, periorbital swelling, or ophthalmoplegia (11,12). Exclusion criteria included any prior history of mucormycosis, residual or recurrent fungal sinusitis, contraindications to MRI (such as presence of metallic implants or claustrophobia), and hypersensitivity to anesthetic agents.

Baseline demographic and clinical information—including age (in years), gender, body mass index (BMI in kg/m²), glycated hemoglobin (HbA1c%), and comorbidities such as diabetes mellitus (defined as HbA1c ≥ 6.5%), history of malignancy, prolonged steroid use (≥1 month), and immunosuppressive therapy—was documented for all participants. Each patient subsequently underwent nasal endoscopy under local anesthesia with topical decongestion in a controlled operating room environment, using a zero-degree rigid endoscope. The

© 2024 et al. Open access under CC BY License (Creative Commons). Freely distributable with appropriate citation.

procedure was carried out by an ENT consultant with a minimum of two years of post-specialization experience. Findings suggestive of mucormycosis on endoscopy were defined by the presence of mucosal discoloration, blackening, crusting, or erosions involving the turbinates, nasal septum, or adjacent mucosa. During endoscopy, tissue biopsy specimens were obtained using punch biopsy instruments and sent to the institutional histopathology laboratory. A consultant histopathologist (minimum two years' experience) performed the diagnostic evaluation using potassium hydroxide (KOH) mount microscopy to identify the characteristic features of mucormycosis, namely broad, ribbon-like, aseptate or sparsely septate hyphae with right-angle branching. Histopathological diagnosis served as the reference standard for the study. All enrolled patients also underwent contrast-enhanced magnetic resonance imaging (MRI) of the brain, paranasal sinuses, and orbits. MRI evaluations were interpreted by a consultant radiologist with a minimum of two years of experience, who documented radiologic signs suggestive of mucormycosis, such as soft tissue opacification, sinus wall erosion, orbital invasion, or intracranial extension. Based on a comparison of findings from contrast-enhanced MRI and nasal biopsy against histopathology, diagnostic outcomes were classified as true positives, false positives, true negatives, and false negatives. The data were analyzed using SPSS version 22.0. Quantitative variables such as age, BMI, and HbA1c were reported as mean ± standard deviation, while qualitative variables including comorbidities and clinical symptoms were expressed as frequencies and percentages. Diagnostic performance of both nasal biopsy and contrast-enhanced MRI was evaluated by calculating sensitivity, specificity, positive predictive value (PPV), and negative predictive value (NPV) using 2x2 contingency tables. A p-value of ≤0.05 was considered statistically significant.

## RESULTS

A total of 82 patients were included in the study. The mean age of participants was 51.34 ± 11.54 years. Of the total, 57 patients (69.51%) were male and 25 (30.49%) were female. The mean body mass index (BMI) was 33.84 ± 4.54 kg/m². Glycated hemoglobin (HbA1c) levels averaged 7.46 ± 1.63%, and 59 patients (71.95%) were identified as diabetic based on an HbA1c value ≥6.5%. A history of corticosteroid use for a duration of one month or more was present in 23 patients (28.05%). None of the participants had a history of malignancy, while 10 patients (12.19%) reported using immunosuppressive agents. Among those presenting with clinical suspicion of mucormycosis, the most commonly reported symptom was nasal blockage associated with blackish lesions on the nasal mucosa, observed in 31 patients (37.81%). Other presenting complaints included blackish lesions on the palatal mucosa in 17 patients (20.73%), facial pain in 15 (18.29%), periorbital swelling in 12 (14.63%), and ophthalmoplegia in 7 patients (8.54%).

Histopathological analysis confirmed the diagnosis of mucormycosis in 59 patients (71.95%). On nasal endoscopy, 41 patients (50.00%) demonstrated visual findings consistent with mucormycosis. Contrast-enhanced MRI showed positive findings suggestive of mucormycosis in 54 patients (65.85%). Comparison with the histopathological gold standard revealed the following for nasal endoscopy: 34 true positives, 7 false positives, 25 false negatives, and 16 true negatives. For contrast-enhanced MRI, there were 49 true positives, 5 false positives, 10 false negatives, and 18 true negatives. Diagnostic performance measures showed that nasal endoscopy had a sensitivity of 57.63%, specificity of 69.57%, positive predictive value (PPV) of 82.93%, negative predictive value (NPV) of 39.02%, and an overall diagnostic accuracy of 60.98%. In contrast, contrast-enhanced MRI demonstrated higher diagnostic efficacy, with a sensitivity of 83.05%, specificity of 78.26%, PPV of 90.74%, NPV of 64.29%, and diagnostic accuracy of 81.71%.

**Table 1: Diagnostic Accuracy of "Nasal Endoscopy" and "Contrast-Enhanced MRI" to Diagnose Mucormycosis (n = 82)**

| Diagnostic Metric | Nasal Endoscopy | Contrast-Enhanced MRI |
|---|---|---|
| Sensitivity | 57.63% | 83.05% |
| Specificity | 69.57% | 78.26% |
| Positive Predictive Value | 82.93% | 90.74% |
| Negative Predictive Value | 39.02% | 64.29% |
| Accuracy | 60.98% | 81.71% |

**Table 2: Based on Nasal Endoscopy Findings (n = 82)**

| | Mucormycosis on Histopathology | No Mucormycosis on Histopathology |
|---|---|---|
| Mucormycosis on Nasal Endoscopy | 34 (41.46%) - TP | 7 (8.64%) - FP |
| No Mucormycosis on Nasal Endoscopy | 25 (30.48%) - FN | 16 (19.51%) - TN |

© 2024 et al. Open access under CC BY License (Creative Commons). Freely distributable with appropriate citation.

INSIGHTS-JHR
INSIGHTS-JOURNAL OF HEALTH AND REHABILITATION

**Table 3: Based on Contrast-Enhanced MRI Findings (n = 82)**

| | Mucormycosis on Histopathology | No Mucormycosis on Histopathology |
|---|---|---|
| Mucormycosis on MRI | 49 (59.76%) - TP | 5 (6.09%) - FP |
| No Mucormycosis on MRI | 10 (12.20%) - FN | 18 (21.95%) - TN |

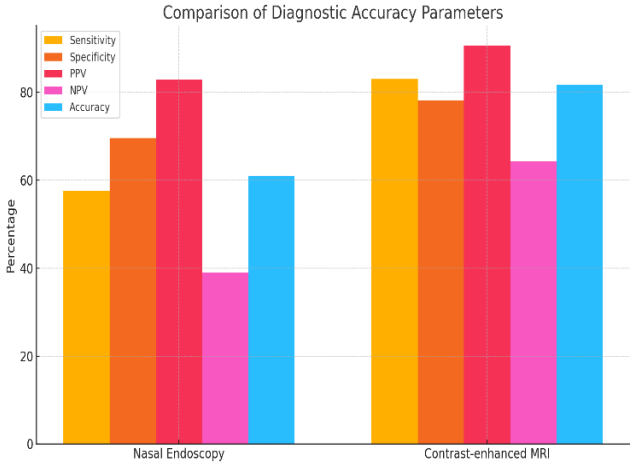


*Figure 1 Comparison of Diagnostic Accuracy Parameters*

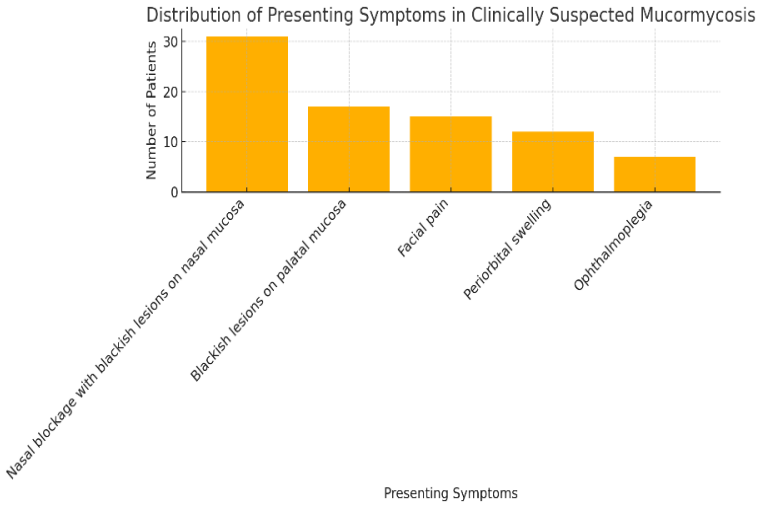


*Figure 2 Distribution Presenting Symptoms in Clinically Suspected Mucormycosis*

## DISCUSSION

Mucormycosis is a rare but life-threatening invasive fungal infection that can involve various anatomical regions, with the nasal cavities, orbits, and cranial structures being particularly vulnerable. Involvement of these areas has been associated with extremely high mortality rates, ranging between 85% and 93% (13,14). The global surge in cases following the COVID-19 pandemic has been alarming, largely attributed to the widespread and sometimes indiscriminate use of systemic corticosteroids. Recent studies have reported a nearly fifty-fold increase in the prevalence of mucormycosis during the pandemic compared to pre-pandemic levels. This unprecedented rise has intensified the focus on early and effective diagnostic strategies, as timely diagnosis remains the cornerstone of favorable clinical outcomes (15). The present study aimed to evaluate and compare the diagnostic performance of nasal endoscopy and contrast-enhanced MRI—two commonly employed modalities in the workup of suspected mucormycosis. Findings revealed that the majority of patients were above the age of fifty, with a male predominance, which is consistent with prior epidemiological trends where most reported cases occurred in males over forty years of age (16). Diabetes mellitus emerged as a common underlying condition, present in all histopathologically confirmed cases in this study, reiterating its role as the most significant predisposing factor in mucormycosis pathogenesis (19). Clinically, the most frequent presentation was nasal blockage accompanied by blackish discoloration of the nasal mucosa, followed by periorbital swelling, ophthalmoplegia, and facial pain—symptoms that are well established in the literature as indicative of rhino-orbital cerebral mucormycosis (17).

When diagnostic accuracy was analyzed, contrast-enhanced MRI demonstrated superior sensitivity (83.05%), specificity (78.26%), and overall accuracy (81.71%) in detecting mucormycosis, compared to nasal endoscopy, which yielded sensitivity of 57.63%, specificity of 69.57%, and accuracy of 60.98%. These findings were consistent with previously conducted research that placed MRI among the most reliable non-invasive imaging tools for early identification of invasive fungal sinusitis (18). In contrast, the relatively lower sensitivity and specificity observed with nasal endoscopy in this study diverged from earlier findings that reported higher diagnostic values for endoscopic assessment. This discrepancy may be attributed to differences in patient selection, disease severity at presentation, or the subjective nature of visual interpretation of endoscopic findings (19). A key strength of this study lies in its real-world applicability within a resource-constrained setting, where the need to identify a single best diagnostic tool is often a clinical necessity. Moreover, the use of histopathology as a gold standard lends robustness to the diagnostic comparison. However, several limitations must be

© 2024 et al. Open access under CC BY License (Creative Commons). Freely distributable with appropriate citation.

acknowledged. The interchangeable use of nasal endoscopy and nasal biopsy in the methodology could have introduced interpretative bias. Clarifying the distinction between visual findings from endoscopy and confirmatory histopathological results from biopsy would enhance the diagnostic delineation. In addition, the single-center nature and relatively small sample size may limit the generalizability of the findings. Despite these limitations, the study provides compelling evidence in favor of utilizing contrast-enhanced MRI as a preferred initial diagnostic approach for mucormycosis in clinically suspected cases. Being non-invasive and highly accurate, MRI offers a substantial advantage in settings where invasive procedures may not be feasible or immediately available. Nonetheless, nasal endoscopy remains valuable as it facilitates both visual assessment and targeted biopsy, especially in centers equipped for endoscopic interventions. Future research should focus on multicentric studies with larger cohorts and incorporate statistical comparisons to validate diagnostic tools. The integration of radiological, clinical, and laboratory findings into a unified diagnostic algorithm would further refine early detection and therapeutic decision-making in mucormycosis.

## CONCLUSION

In conclusion, this study highlights that contrast-enhanced MRI of the brain, paranasal sinuses, and orbit serves as a more effective and reliable diagnostic tool than nasal endoscopy for identifying mucormycosis in patients with strong clinical suspicion. When evaluated against histopathological confirmation as the diagnostic benchmark, MRI demonstrated superior diagnostic performance. Given its non-invasive nature and broader anatomical assessment capabilities, it holds significant practical value, particularly in aiding timely diagnosis and management in resource-constrained settings. These findings support the preferential use of MRI as a frontline investigation for early detection of mucormycosis, thereby contributing meaningfully to improved clinical outcomes.

**Author Contribution**

| Author | Contribution |
|---|---|
| Shahzaib Shaukat Qureshi* | Substantial Contribution to study design, analysis, acquisition of Data<br>Manuscript Writing<br>Has given Final Approval of the version to be published |
| Muhammad Umar Aasim | Substantial Contribution to study design, acquisition and interpretation of Data<br>Critical Review and Manuscript Writing<br>Has given Final Approval of the version to be published |
| Wazir Feroze Ahmed | Substantial Contribution to acquisition and interpretation of Data<br>Has given Final Approval of the version to be published |
| Tahir Liaquat | Contributed to Data Collection and Analysis<br>Has given Final Approval of the version to be published |
| Nauman Jamil | Contributed to Data Collection and Analysis<br>Has given Final Approval of the version to be published |
| Anoosha Zafar | Substantial Contribution to study design and Data Analysis<br>Has given Final Approval of the version to be published |
| Hamza Asad | Contributed to study concept and Data collection<br>Has given Final Approval of the version to be published |

## REFERENCES

1. Metwally MI, Mobashir M, Sweed AH, Mahmoud SM, Hassan AG, ElKashishy K, et al. Post COVID-19 Head and Neck Mucormycosis: MR Imaging Spectrum and Staging. Acad Radiol. 2022;29(5):674-84.
2. Hada M, Gupta P, Bagarhatta M, Tripathy K, Harsh A, Khilnani K, et al. Orbital magnetic resonance imaging profile and clinicoradiological correlation in COVID-19-associated rhino-orbital-cerebral mucormycosis: A single-center study of 270 patients from North India. Indian J Ophthalmol. 2022;70(2):641-8.

© 2024 et al. Open access under CC BY License (Creative Commons). Freely distributable with appropriate citation.

3. Kumar I, Verma A, Dangwal J, Singh PK, Chandra Shukla R, Chakravarty J. Magnetic resonance imaging spectrum of COVID-associated rhino-orbital-cerebral mucormycosis and assessment of anatomical severity. Neuroradiol J. 2023;36(4):404-13.
4. Dixit R, Gupta A, Prakash A, Pradhan GS. Magnetic resonance imaging of rhino-orbito-cerebral mucormycosis: a pictorial review. Acta Radiol. 2023;64(4):1641-9.
5. Sreshta K, Dave TV, Varma DR, Nair AG, Bothra N, Naik MN, et al. Magnetic resonance imaging in rhino-orbital-cerebral mucormycosis. Indian J Ophthalmol. 2021;69(7):1915-27.
6. Yadav T, Tiwari S, Gupta A, Garg PK, Khera PS, Rajagopal R, et al. Magnetic Resonance Imaging in Coronavirus Disease - 2019 Associated Rhino-Orbital-Cerebral Mucormycosis (CA-ROCM) - Imaging Analysis of 50 Consecutive Patients. Curr Probl Diagn Radiol. 2022;51(1):112-20.
7. Sanghvi D, Kale H. Imaging of COVID-19-associated craniofacial mucormycosis: a black and white review of the "black fungus". Clin Radiol. 2021;76(11):812-9.
8. Mazzai L, Anglani M, Giraudo C, Martucci M, Cester G, Causin F. Imaging features of rhinocerebral mucormycosis: from onset to vascular complications. Acta Radiol. 2022;63(2):232-44.
9. Ghuman SS, Sindhu P, Buxi TBS, Sheth S, Yadav A, Rawat KS, et al. CT appearance of gastrointestinal tract mucormycosis. Abdom Radiol (NY). 2021;46(5):1837-45.
10. Teixeira BM, Dias MQ, Castela G. Bilateral Rhino-Orbital-Cerebral Mucormycosis. JAMA Ophthalmol. 2024;142(7):e236486.
11. Montaño DE, Voigt K. Host immune defense upon fungal infections with mucorales: pathogen-immune cell interactions as drivers of inflammatory responses. J Fungi (Basel). 2020;6(3):173.
12. Reid G, Lynch JP 3rd, Fishbein MC, Clark NM. Mucormycosis. Semin Respir Crit Care Med. 2020;41(1):99-114.
13. Li Z, Denning DW. The impact of corticosteroids on the outcome of fungal disease: a systematic review and meta-analysis. Curr Fungal Infect Rep. 2023;17(1):54-70.
14. Skiada A, Pavleas I, Drogari-Apiranthitou M. Epidemiology and diagnosis of mucormycosis: an update. J Fungi (Basel). 2020;6(4):265.
15. Hassan F, Mansoor A, Iqbal J, Zaidi M, Ali M. Diagnostic accuracy of MRI in detection of invasive fungal sinusitis taking histopathology as gold standard. Pak J Radiol. 2021;31(3):171-176.
16. ElSayed NA, Aleppo G, Aroda VR, Bannuru RR, Brown FM, Bruemmer D, et al., on behalf of the American Diabetes Association. 2. Classification and diagnosis of diabetes: standards of care in diabetes-2023. Diabetes Care. 2023 Jan 1;46(Suppl 1):S19-S40.
17. Kaushal D, Rajan N, Soni K, Sharma A, Choudhury B, Yadav T, et al. Reducing mortality in mucormycosis of the head and neck in diabetic patients: A CARE case series. Eur Ann Otorhinolaryngol Head Neck Dis. 2022;139(3):146-152.
18. Yadav S, Bs N, Ak S. Clinical profile of central nervous system involvement in patients with rhino orbital cerebral mucormycosis. J Assoc Physicians India. 2022;70(4):11-12.
19. Shaikh N, Shakrawal N, Chouhan M, Solanki B. Diagnostic accuracy of nasal endoscopy and contrast magnetic resonance imaging in COVID-19 associated mucormycosis (CAM). Authorca [preprint]. 2021.
20. Waqar S, Ameer S, Naeem M, Bajwa MA, Bajwa SM, Bajwa GR. Diagnostic accuracy of magnetic resonance imaging for diagnosis of acute invasive fungal sinusitis taking histopathology as a gold standard. Pak Armed Forces Med J. 2020;70(6):1810-1814.

© 2024 et al. Open access under CC BY License (Creative Commons). Freely distributable with appropriate citation.