INSIGHTS-JOURNAL OF
HEALTH AND REHABILITATION

INSIGHTS-JHR
INSIGHTS-JOURNAL OF HEALTH AND REHABILITATION

Metastatic Medullary Carcinoma Thyroid of the Palatine Tonsil: A Rare Case Report

Case Report

Muhammad Saqib[1], Muhammad Usama[1], Shayan Shahid Ansari[1], Hadia Wali[1], Fahad Rehman[2], Muhammad Ali Hassan*[1]
[1]Shifa College of Medicine/Shifa International Hospital Islamabad Pakistan.
[2]Shifa International Hospital Islamabad Pakistan
Corresponding Author*: Muhammad Ali Hassan, alihassan0260060@gmail.com, Shifa College of Medicine/Shifa International Hospital Islamabad Pakistan.

Conflict of Interest: None
Grant Support & Financial Support: None
Reviewer Comments:
Reviewer 1: The paper clearly articulates its purpose, provides a comprehensive and relevant literature review, and presents results and conclusions that are well-supported and insightful.
Reviewer 2: The paper excels in presenting results logically, engaging critically with literature, and delivering insightful conclusions that are strongly supported by the findings.

Abstract

Background: Metastatic involvement of the palatine tonsil by primary thyroid tumors is an exceedingly rare clinical occurrence. Medullary carcinoma thyroid, which comprises only a small percentage of all thyroid malignancies, is known for its potential to metastasize, often resulting in a less favourable prognosis.

Case Details: We present the case of a 66-year-old male with no previous comorbidities, who had undergone a left thyroid lobectomy 35 years prior without histopathological examination. The patient was initially asymptomatic, presenting with an incidental finding of an opacity on a chest X-ray during routine examination. Subsequent investigations revealed a metastatic medullary carcinoma of the thyroid, with metastasis to the palatine tonsil, confirmed through histopathology after tonsillectomy. This case is reported to be the first of its kind involving metastasis of medullary thyroid carcinoma to the palatine tonsil.

Conclusion: This case underscores the importance of considering metastatic disease in unusual locations such as the palatine tonsil and highlights the need for thorough evaluations, including immunohistochemical analysis, for accurate diagnosis and treatment planning. The findings emphasize the necessity of a multidisciplinary approach in managing such rare occurrences to improve patient outcomes.

Keywords: Medullary Carcinoma, Metastasis, Palatine Tonsil, Thyroid Neoplasms, Tonsillar Neoplasms, Tonsillectomy, Immunohistochemistry.

© 2024 et al. Open access under CC BY License (Creative Commons). Freely distributable with appropriate citation.

INTRODUCTION

Cancer poses a significant global public health challenge, world health organization labels it as the leading cause of death worldwide, accounting for nearly one in six deaths worldwide or approximately 10 million deaths in the year 2020 (1). Weather the delays caused by corona virus disease (COVID-19) back in 2020 has directly affected the statistics of advance stage cancer diagnosis or not will be answered gradually in the coming years. What is already known is that the pandemic has exceptionally damaged racial and ethnic minorities in the U.S (2). Our case also links delayed presentation directly to more advanced disease diagnosis. Recent trends reflect a decrease in thyroid cancer incidence rate by 2% since 2014 and current survival is highest for thyroid cancer accounting for 98 % of five-year survival rate (3). Thyroid cancer delineates into four distinct histological variants, namely papillary, follicular, medullary, and anaplastic. Within the domain of thyroid cancers, medullary and anaplastic variants occupy a unique space, together contributing a small share among the total number of thyroid cancer cases. This distinction, however, is marred by their pronounced capacity for metastasis, manifesting in their significantly lower survival rates. The 5-year relative survival rates diverge notably among metastatic thyroid cancers. Metastatic papillary thyroid cancer showcases a relatively favorable 5-year survival rate of 74%, while metastatic follicular thyroid cancer follows closely behind at 67%. In contrast, metastatic medullary thyroid cancer presents a less optimistic outlook with a 5-year survival rate of 43%. Regrettably, metastatic anaplastic thyroid cancer exhibits a starkly dismal 5-year survival rate, standing at only 4% (4). Medullary thyroid carcinoma makes up 4% of all thyroid carcinoma cases (5). Approximately a thousand cases of medullary carcinoma are diagnosed annually in the United States (6). Metastatic disease occurring in the palatine tonsil is exceptionally uncommon, representing just 0.8% of malignant tonsillar neoplasms (7). Typically, metastatic palatine tonsil tumors originate from primary sites such as the hypernephroma from kidney (8), cutaneous melanoma (9), adenocarcinoma stomach (10), hepatocellular carcinoma (11), signet cell carcinoma cecum (12), colon adenocarcinoma (13), rectum adenocarcinoma (14) and small cell carcinoma lung (15).

We present a case of 66-year-old patient of metastatic medullary thyroid carcinoma who developed a big metastasis in the palatine tonsil. This is, to the best of our knowledge, the first documented case of metastatic medullary thyroid cancer of the palatine tonsil. Metastatic tonsillar carcinoma is associated with poor prognosis with the mean life expectance after diagnosis of tonsillar metastasis was just nine months (15). This report aims to discuss a rare case of metastatic medullary carcinoma of the thyroid to the palatine tonsil, a clinical occurrence of exceptional rarity. Despite medullary carcinoma comprising only a minor fraction of all thyroid cancer types, it is disproportionately represented in metastatic outcomes, which typically feature poorer prognoses. This case is particularly significant due to the unusual site of metastasis—the palatine tonsil—a location seldom involved in thyroid cancer spread. Through this report, we highlight the diagnostic journey and therapeutic interventions that culminated in the identification and management of this unique case, providing insights that may assist clinicians in handling similar rare instances.

CASE PRESENTATION

A 66-year-old patient with no previously known co-morbids. He gave the history of left thyroid lobectomy 35 years ago for which histopathology was not done at that time. At his initial presentation he was asymptomatic and presented with an incidental finding of opacity on chest X-ray. CT performed showed a mass lesion of 32x38x32mm size with speculated margins in right lower lobe of lung and enlarged hilar lymph nodes and a right lobe thyroid lesion. CT guided right lung mass biopsy was taken which turned out to be metastatic medullary carcinoma from thyroid. FNAC from thyroid was benign thyroid aspirate (BETHESDA category 2).

He underwent right lung lower lobe lobectomy and right thyroid lobectomy. Final histopathology confirmed medullary microcarcinoma with two tumor foci and tumor size of 0.3 and 0.1 CM. Right lung lower lobe lobectomy revealed metastatic medullary thyroid carcinoma with tumor size 5.5 x 4.5 x 3.2 CM. Additional margins, mediastinal fat and fat pad anterior to right scalene muscle was also sent and all turned out negative for malignancy. Final pathological stage was pT1a No M1. His surveillance imaging was performed at a three-month interval to re-evaluate. He had mild dysphagia, and nasal twang in voice but no associated hoarseness or dyspnea. Physical examination revealed left or pharyngeal mass with no palpable neck nodes or any other significant abnormality. CT revealed lobulated heterogeneous mass in the oropharynx arising from the left pharyngeal wall obliterating the left par pharyngeal fat plane (Figure-1). No evidence of residual or recurrent mass in the region of thyroid bed. Enlarged right hilar and subcarinal lymph nodes. Differentials as per radiology pointed towards both new metachronous malignancy as well as metastatic disease.

© 2024 et al. Open access under CC BY License (Creative Commons). Freely distributable with appropriate citation.

After multidisciplinary team discussion his excision of his left tonsillar lesion was performed under general anesthesia (Figure 2), histopathology confirmed metastatic medullary carcinoma (Figure 3) thyroid being positive for Calcitonin (Figure 4) and Thyroid Transcription Factor-1 (TTF1) (Figure 5). Further the patient received palliative treatment. Informed consent was obtained from the patient for the publication of this case report and any accompanying images. The patient was made aware of the nature of the report and its implications, including the potential for educational use and the contribution to medical literature. The process ensured respect for the patient's privacy and compliance with ethical standards in medical reporting.

DISCUSSION

Malignancies arising in the tonsils are usually primary. Metastatic disease of the palatine tonsil is rare. And this is the first case of metastatic disease of palatine tonsil originating from the thyroid gland, particularly when the primary tumor is medullary carcinoma thyroid. Lymphatics in the palatine tonsils are only efferent. Hematogenous spread is the probable route for metastasis although retrograde lymphatic spread has also been suggested which doesn't get explained when cervical lymph nodes are uninvolved. Different type of therapies interventions explained include surgery, chemotherapy, radiotherapy and chemo radiotherapy (16).

Malignancies appearing in the head and neck region also pose a risk to airway weather primary or metastatic. Airway management at the time of biopsy by experts is crucial in such cases. Also otherwise recognizing the ability of conversion to respiratory emergency should be kept in mind for such cases. In this report, we present the significance of close follow up and high index of suspicion for disease recurrence even in unusual places in cases of metastatic disease and keeping such rare occurrences in mind while performing clinical examination. Our case report also highlights the importance of multidisciplinary team approach as it directly affects the decision making therefore improving the management and care of patients with this condition.

CONCLUSION

This unusual presentation of metastatic medullary carcinoma of the thyroid to the palatine tonsil highlights the critical need for heightened vigilance and comprehensive evaluation of atypical symptoms in patients with a history of thyroid cancer. The findings from this case suggest that healthcare providers should consider metastatic disease in differential diagnoses for tonsillar masses, regardless of their rarity. Future research should focus on exploring the mechanisms of metastasis to uncommon sites and evaluating the effectiveness of various treatment modalities in such cases. Clinically, this case underscores the importance of a multidisciplinary approach to ensure optimal management and patient care outcomes. This approach should be integrated into practice guidelines to aid clinicians in identifying and managing similar cases effectively, thereby improving prognostic outcomes for patients with rare metastatic presentations.



Figure 1: CT showing oropharangeal mass arising from left pharangeal wall.



Figure 2: Tonsillectomy specimen

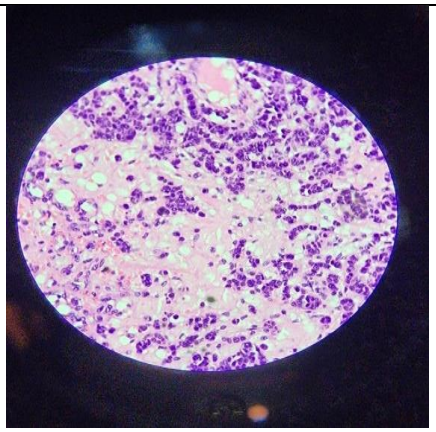

Figure 3: Histopathological appearance of medullary thyroid: solid nest of di-cohesive cells with fibrous stoma.

© 2024 et al. Open access under CC BY License (Creative Commons). Freely distributable with appropriate citation.

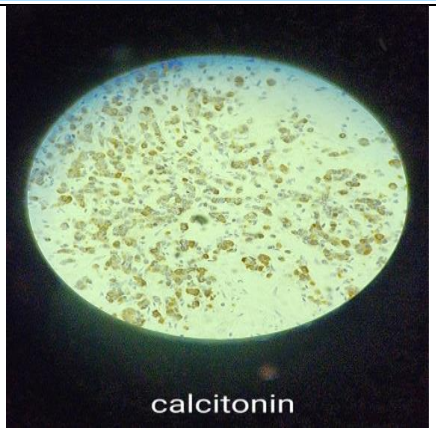

Figure 4: Representing tumor positive for calcitonin

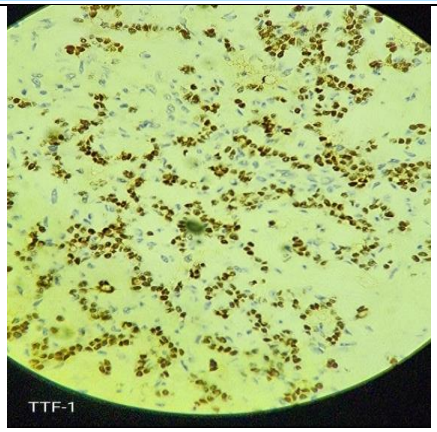

Figure 5: Representing tumor positive for TTF -1

REFERENCES

1. Ferlay J, Ervik M, Lam F, Colombet M, Mery L, Pinerous M, et al. Global Cancer Observatory: Cancer Today. Lyon: International Agency for Research on Cancer; 2020 (https;//gco.iarc.fr/today, assessed February 2021).
2. Bassetti, M.; Vena, A.; Giacobbe. D.R. The novel Chinies coronavirus (2019-nCoV) infection: Challenges for fighting the storm. Eur. J. Clin. Investig 2020, 50.
3. Mazzaferri EL. Thyroid carcinoma: papillary and follicular. In: Mazzaferri EL, Samaan N, editors. Endocrine tumors. Cambridge: Blackwell Scientific Publications; 1993. pp. 278–333.
4. Saad MF, Ordonez NG, Rashid RK, Guido JJ, Hill Cs, Jr, Hickey RC, et al. Medullary carcinoma of the thyroid. A study of the clinical features and prognostic factors in 191 patients. Medicine (Baltimore) 1984;63(6):319–42.
5. Gupta S, Jawanda MK, Kedia NB, Deb AR, Ganganna A, Saurabh K, Yadav SK, Yadav AB.J Clin Exp Dent. 2022 Oct 1;14(10):e854-e874. doi: 10.4317/jced.59773. eCollection 2022 Oct.PMID: 36320671
6. Tsakiraki Z, Delides A, Damaskou V, Psarogiorgou S, Athanasiadis I, Spathis A, Giotakis E, Panayiotides IG.Clin Case Rep. 2021 Jul 16;9(7):e04460. doi: 10.1002/ccr3.4460. eCollection 2021 Jul.PMID: 34295485.
7. Kuge T, Okabe F, Yamamoto Y, Ishijima M, Uenami T, Kanazu M, Akazawa Y, Yano Y, Yamaguchi T, Mori M.Thorac Cancer. 2021 Jun;12(12):1935-1939. doi: 10.1111/1759-7714.13948. Epub 2021 May 11.PMID: 33973724.
8. Dulskas A, Trakymas M, Gibavičienė J, Čepulis V, Čižauskaitė A, Samalavičius NE.Acta Med Litu. 2022;29(1):118-123. doi: 10.15388/Amed.2021.29.1.5. Epub 2022 Jul 25.PMID: 36061926.
9. Ross T, Malik A, Awad Z.BMJ Case Rep. 2020 Dec 13;13(12):e235768. doi: 10.1136/bcr-2020-235768.PMID: 33318261.
10. J Int Soc Prev Community Dent. 2016 Sep-Oct;6(5):393-401. doi: 10.4103/2231-0762.192935. Epub 2016 Oct 24.PMID: 27891304
11. Wannaphut C, Takahashi T, Macapagal S, Tanariyakul M, Ongsupankul S, Yinadsawaphan T, Nishimura Y, Acoba J.Cureus. 2024 Apr 14;16(4):e58250. doi: 10.7759/cureus.58250. eCollection 2024 Apr.PMID: 38745806.
12. Chen CC, Lee CT, Chang SL, Tsai MC.Medicine (Baltimore). 2019 May;98(22):e15763. doi: 10.1097/MD.0000000000015763.PMID: 31145296.
13. Hurlstone DP, Sanders DS, Smith A, Jones RB, Slater DN, Bardhan KD. Tonsillar metastasis: A rare presentation of gastric carcinoma. Eur J Surg Oncol. 2001;27:328–330.
14. Hong W, Wang X, Yu XM, Chen B, Ding GJ, Zhang YP.Int J Clin Exp Pathol. 2012;5(5):468-71. Epub 2012 May 23.PMID: 22808302
15. Am J Roentgenol Radium Ther Nucl Med. 1974 Jan;120(1):130-8
16. Bar R, Netzer A, Ostrovsky D, Daitzchman M, Golz A. Abrupt tonsillar hemorrhage from a metastatic hemangiosarcoma of the breast: case report and literature review. Ear Nose Throat J. 2011; 90: 116–120.

© 2024 et al. Open access under CC BY License (Creative Commons). Freely distributable with appropriate citation.