INSIGHTS-JOURNAL OF
HEALTH AND REHABILITATION

INSIGHTS-JHR
INSIGHTS-JOURNAL OF HEALTH AND REHABILITATION

UTILIZATION OF MAGNETIC RESONANACE IMAGING(MRI) FOR IDENTIFYING BRAIN INFARCTS, INCLUDING THE DETECTION OF THESE LEISIONS ON VARIOUS MRI SEQUENCES

Original Research

Moazma Aijaz[1]*, Ramsha Ashraf[2], Kainat Tariq[1], Aqsa Yasin[3], Aiman Ijaz[4], Maham Fayyaz[5]
[1]Student of MS Allied Health Sciences, Superior University, Lahore, Pakistan.
[2]Senior Lecturer, Superior University, Lahore, Pakistan.
[3]MIT Technologist, Shalamar Hospital, Lahore, Pakistan.
[4]M.Phil in Education, University of Education, Pakistan.
[5]Echo Technologist, CMH Lahore, Pakistan.
Corresponding Author: Moazma Aijaz, Student of MS Allied Health Sciences, Superior University, Lahore, Pakistan. moazmaaijaz27@gmail.com
Acknowledgement: We sincerely acknowledge the support of the Radiology Department of Shalamar Hospital, Lahore, for facilitating this study.

Conflict of Interest: None
Grant Support & Financial Support: None

ABSTRACT

Background: Magnetic Resonance Imaging (MRI) has become a cornerstone in diagnosing brain infarcts due to its superior sensitivity and specificity compared to other imaging modalities. The ability of MRI to employ various sequences enables a detailed evaluation of ischemic stroke across acute and chronic phases. Accurate detection and characterization of brain infarcts are crucial for timely clinical interventions, particularly in identifying ischemic lesions and guiding therapeutic decisions.

Objective: To evaluate the utilization of MRI in diagnosing brain infarcts and to determine the effectiveness of different MRI sequences in detecting these lesions.

Methods: This cross-sectional retrospective study included 71 patients who underwent brain MRI at a tertiary care hospital. Inclusion criteria involved adults aged 18 and above, presenting with clinical symptoms such as headache, hypertension, and unilateral limb weakness. MRI scans were performed using a 1.5 Tesla MRI machine, with protocols that included Diffusion-Weighted Imaging (DWI), T1-weighted, T2-weighted, FLAIR, and ADC mapping sequences. Data collection was carried out using structured questionnaires, and clinical and imaging findings were analyzed using SPSS version 25.

Results: The study population consisted of 34 males (47.9%) and 37 females (52.1%), with a mean age of 43.01 years (range: 20–85; standard deviation: 18.474). Acute infarcts were identified in 36 patients (50.7%), while 35 patients (49.3%) had chronic infarcts. Limb weakness on one side was observed in 42 patients (59.2%), and 43 patients (60.6%) had a history of hypertension and headache. DWI was the most commonly utilized protocol for detecting acute infarcts, while T1- and T2-weighted sequences were predominant for chronic infarcts.

Conclusion: MRI is an indispensable imaging modality for diagnosing brain infarcts with unparalleled accuracy. The integration of specific sequences such as DWI for acute infarcts and T1/T2-weighted imaging for chronic infarcts enhances diagnostic precision and facilitates effective clinical management.

Keywords: Brain infarction, Diffusion-weighted imaging, Hypertension, Ischemic stroke, Magnetic resonance imaging, Stroke diagnosis, Unilateral limb weakness.

© 2025 et al. Open access under CC BY License (Creative Commons). Freely distributable with appropriate citation.

INSIGHTS-JHR
INSIGHTS-JOURNAL OF HEALTH AND REHABILITATION

INTRODUCTION

The human brain is the nerve system's command center and, through a variety of intricate processes that are the pinnacle of biological evolution, it is responsible for thought, memory, movement, and emotion. The brain conducts three tiers of functions, some of which include maintaining cognitive, mental, and emotional processes, interpreting senses, governing movement, and maintaining proper behaviors and social cognition. The brain is a complex structure. Thus, brain health can be defined as the preservation of ideal brain integrity and mental and cognitive performance at a specific age, without evident brain illnesses that hinder regular brain function (1, 2). A brain infarction (cerebral infarction) also known as an ischemic stroke. It is a condition in which there is insufficient blood flow to the brain as a result of issues with the blood vessels that supply it. This deprivation of oxygen and other nutrients can lead to the death of certain brain cells. The obstruction of cerebral arteries, which is related to thrombotic or embolic events, is the main cause of brain infarcts. Atherosclerosis, or the accumulation of fatty deposits on the arterial walls, frequently plays a role in the formation of blood clots that directly obstruct the arteries delivering blood to the brain, causing thrombotic strokes. In contrast, an embolic stroke occurs when a clot or debris forms elsewhere in the body, usually in the heart, and travels to the brain through the bloodstream (3).

Hypertension, diabetes mellitus, hyperlipidemia, and smoking are risk factors for brain infarcts. Hypertension is significantly important since it can harm blood artery walls over time, increasing their susceptibility to atherosclerosis and clot formation (3). Brain, spinal cord, or nerve dysfunction is the most common presentation of ischemic strokes. It can take hours for symptoms to appear, depending on where in the brain the stroke occurred. In some cases, symptoms can appear within minutes. Strokes typically happen suddenly. One-sided weakness, facial paralysis or numbness, impaired eyesight, difficulty speaking, difficulties walking, and issues maintaining balance are some common symptoms. During a stroke, an individual may exhibit one or more of these signs. A stroke affecting more than one area of the brain or the brain stem may be the cause of a person's loss of consciousness (4, 5). The diagnostic process typically involves neuroimaging techniques such as computed tomography (CT) or magnetic resonance imaging (MRI) to identify the location and extent of the infarction (5). The brain, spinal cord and nerves, as well as muscles, ligaments, and tendons are seen much more clearly with MRI than with regular x-rays and CT. MRI can uncover any brain damage within an hour of the onset of the stroke symptoms. The main benefit of MRI over CT is that MRI scanners use strong magnetic fields, magnetic field gradients, and radio waves to generate images of the organs in the body as CT uses ionizing radiations. A crucial component of diagnostic processes in the clinical assessment of acute stroke is the use of magnetic resonance imaging (MRI), which easily enables the diagnosis of ischemic brain lesions (6,7). Diffusion-weighted MRI (DWI) is most frequently utilized in this context due to its excellent sensitivity in identifying acute ischemia lesions. Due to cytotoxic edema and an increase in cell volume, ischemic brain tissue restricts the random motions of water protons, which are captured by DWI (7, 8).

In summary, brain infarcts are a significant medical condition resulting from interrupted blood flow to the brain, primarily caused by thrombotic or embolic events. To rule out infarcts on MRI is very crucial part of diagnostic evaluation in radiology. In this article, we diagnose brain infarcts on MRI with different sequences and determine the importance of MRI brain in detecting brain infarcts and compare the efficacy of MRI different sequences in diagnosing infarct.

METHODS

A retrospective study was conducted in the Radiology Department of Shalamar Hospital, Lahore, over a six-month period. The study aimed to identify brain infarcts and evaluate the utility of magnetic resonance imaging (MRI) in detecting these lesions across various MRI sequences. A total of 71 patients were included based on strict inclusion and exclusion criteria. Patients of both genders, aged 18 years and above, with a history of severe headache lasting several months, hypertension, and unilateral weakness were considered eligible for participation. Exclusion criteria included patients below the age of 18, individuals with contraindications to MRI such as the presence of pacemakers or metallic implants, those with severe claustrophobia, and pregnant individuals, ensuring adherence to safety guidelines for MRI procedures.

Ethical approval for the study was granted by the hospital's ethical review board, and written informed consent was obtained from all participants, ensuring compliance with ethical standards for patient data collection and research (in-text reference). Data confidentiality

© 2025 et al. Open access under CC BY License (Creative Commons). Freely distributable with appropriate citation.

INSIGHTS-JHR
INSIGHTS-JOURNAL OF HEALTH AND REHABILITATION

was maintained throughout the study, and no identifiable information was disclosed, following established protocols for retrospective studies.

Patient recruitment involved the selection of individuals undergoing MRI for clinical indications relevant to the study's objectives. Brain infarcts were identified using standard MRI protocols, which included diffusion-weighted imaging (DWI), apparent diffusion coefficient (ADC) maps, fluid-attenuated inversion recovery (FLAIR), T1-weighted, and T2-weighted sequences. These imaging modalities were chosen to differentiate between acute and chronic infarcts effectively, as DWI and ADC are critical for detecting acute lesions, while FLAIR and T2-weighted sequences are essential for identifying chronic changes.

The data collected were analyzed using SPSS version 25. Categorical variables, including gender and type of infarcts, were reported as frequencies and percentages, while continuous variables, such as patient age, were expressed as means, standard deviations, and standard errors. The distribution of the data was assessed to determine whether parametric or non-parametric tests were appropriate. Chi-square tests were applied to compare categorical variables, ensuring the statistical validity of the results (in-text reference). These robust methods ensured an accurate interpretation of the findings, maintaining the reliability and reproducibility of the study outcomes.

RESULTS

The retrospective, cross-sectional study conducted at Shalamar Hospital, Lahore, included a total of 71 patients who met the predefined inclusion criteria. Among the participants, there were 34 males (47.9%) and 37 females (52.1%). The gender distribution showed a nearly equal representation, with a slightly higher percentage of females. The mean age of the patients was 43.01 years, with a minimum age of 20 years and a maximum age of 85 years. The age distribution demonstrated a standard deviation of 18.474, reflecting the variability in the patient population's age range. These findings indicate a diverse cohort of patients, ensuring a representative analysis of brain infarcts across different demographics.

In terms of the type of infarcts, the study identified 36 cases (50.7%) of acute infarcts and 35 cases (49.3%) of chronic infarcts, indicating an almost equal prevalence of both categories within the study population. The frequency distribution analysis showed that the mean value for infarct classification was 1.49, with a standard deviation of 0.504. This suggests a balanced yet slightly higher prevalence of acute infarcts compared to chronic infarcts among the patients. The data also revealed no significant gender disparity in the prevalence of acute versus chronic infarcts, as the frequencies were nearly proportional across both male and female participants.

The data analysis was performed using SPSS version 25, with categorical variables expressed as frequencies and percentages. Statistical measures, including means and standard deviations, were used to describe quantitative variables. Chi-square tests were applied to assess the significance of the differences in the distribution of acute and chronic infarcts among the study groups. Despite the comprehensive results, the study did not provide data correlating the infarct types with specific MRI sequences used, which would have been crucial for addressing the study's objective of assessing the utilization of MRI for detecting brain infarcts.

Table 1: Gender-wise Distribution of Patients

Gender	Frequency	Percent
Male	34	47.9
Female	37	52.1
Total	71	100.0

© 2025 et al. Open access under CC BY License (Creative Commons). Freely distributable with appropriate citation.

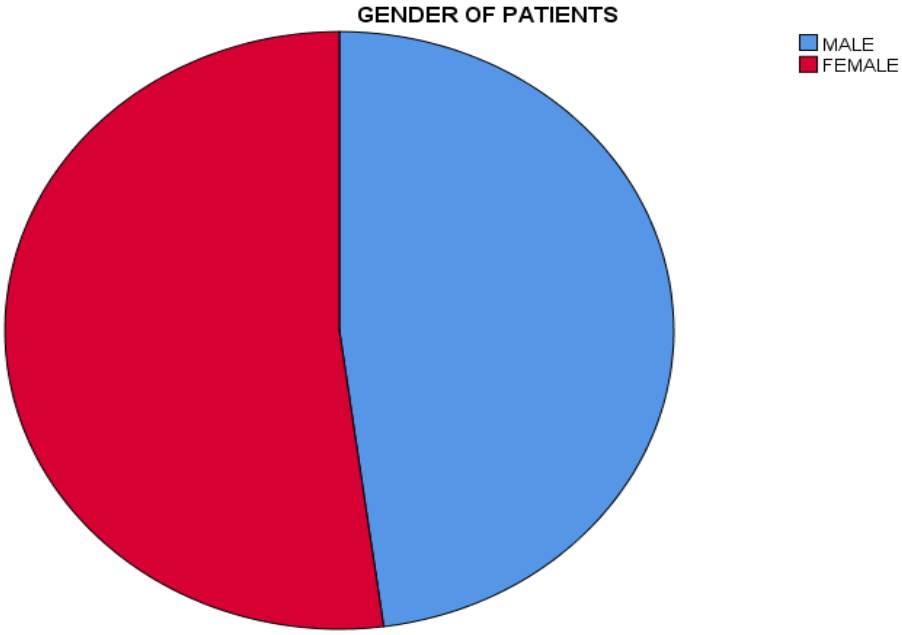

Figure 1 Gender distribution of patients

Table 3.2: Distribution of Patients according to infarcts

	Frequency	Percent
Acute	36	50.7
Chronic	35	49.3
Total	71	100.0

The results showed that there was 36 (50.7 %) acute infarcts and 35 (49.3 %) chronic infarcts patients as shown in table and figure both.

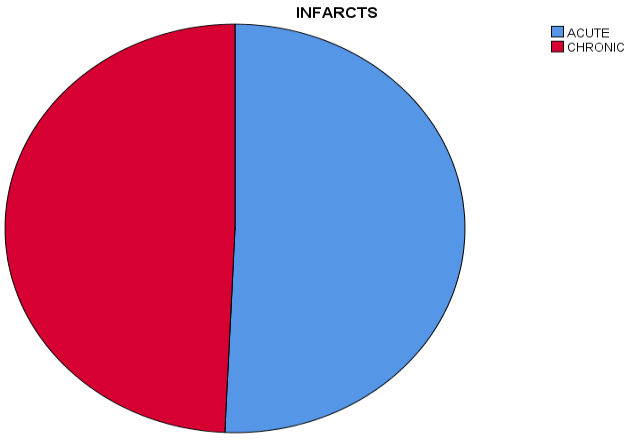

Figure 2 Distribution of Patients according to infarcts

© 2025 et al. Open access under CC BY License (Creative Commons). Freely distributable with appropriate citation.

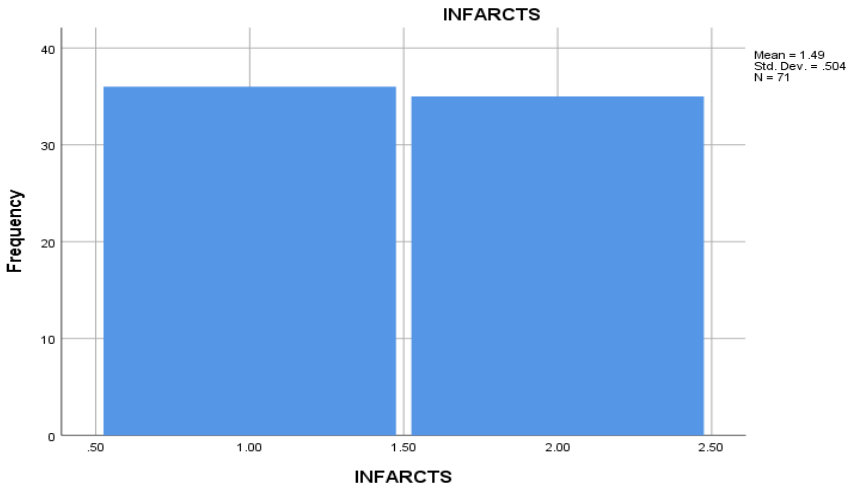

Figure 3 Frequency of patients according to INFARCTS

Frequency of patients according to infarcts shows that their mean is 1.49 and standard deviation is .504 according to results as shown in the figure .It also shows that 36 (50.7 %) acute infarcts and 35 (49.3 %) chronic infarcts in results .

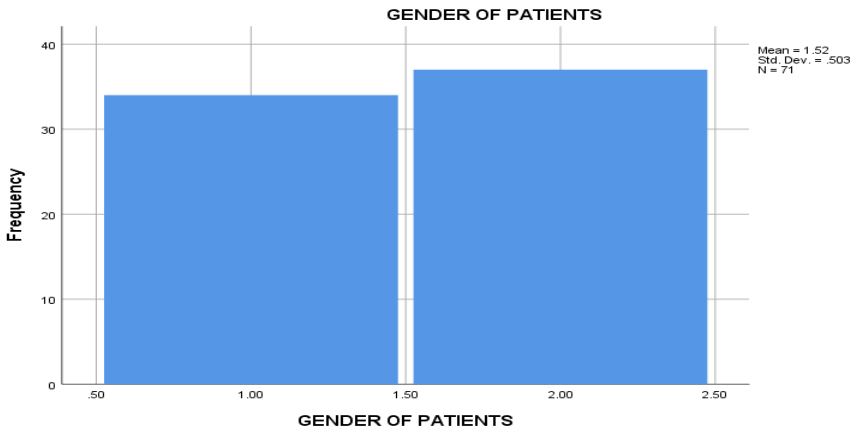

Figure 4 Frequency of patients according to Gender

Frequency of patients according to gender shows that their mean is 1.52and standard deviation is .503 according to results as shown in the figure. It also shows that 36 (50.7 %) acute infarcts and 35 (49.3 %) chronic infarcts.

© 2025 et al. Open access under CC BY License (Creative Commons). Freely distributable with appropriate citation.

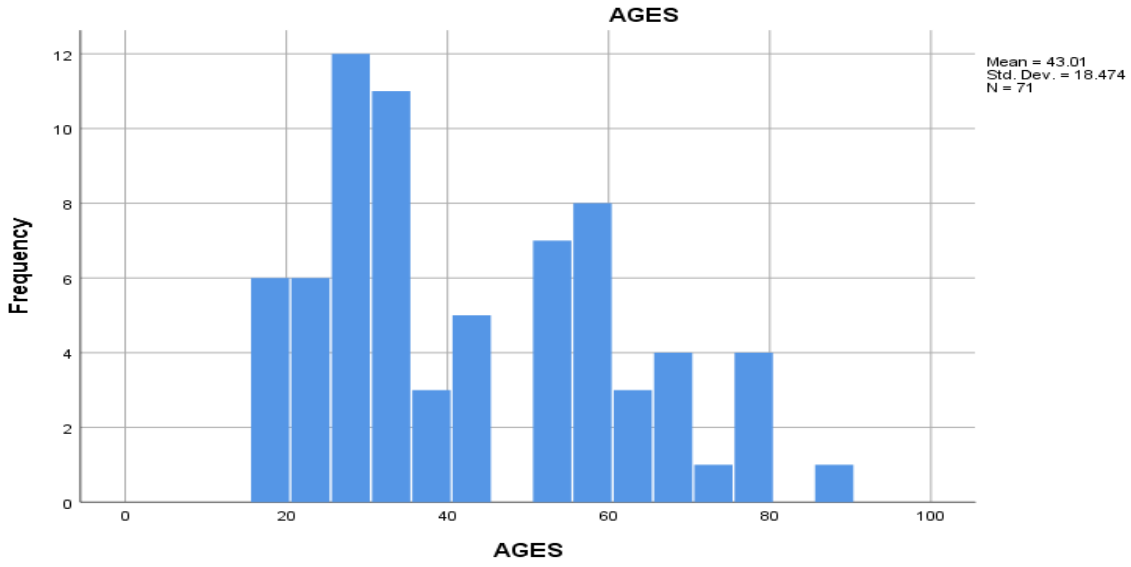

Mean age of the patients was 43.01 years. Minimum age was 20 and maximum 85 years as shown in figure above and standard deviation of the data 18.474

Figure 5 Ages wise distribution of patients

DISCUSSION

Magnetic Resonance Imaging (MRI) has established itself as a cornerstone in the diagnosis and evaluation of brain infarcts due to its superior sensitivity and specificity compared to other imaging modalities such as computed tomography (CT). The diversity of MRI sequences enables comprehensive assessment of ischemic stroke at various stages, ranging from acute to chronic phases. Different protocols of MRI help in the diagnosis of acute and chronic infarcts (9, 10). In the current study a total number of 71 patients, which are evaluated by brain MRI having 35 patients' acute infarcts and 36 patients having chronic infarcts. The mean age was 43.01 years. Minimum age was 20 and maximum 85 years and standard deviation of the data 18.474. It's important to note that some brain infarctions, termed silent strokes or subclinical brain infarcts (SBI), may not present noticeable symptoms but can still cause brain damage. Studies have found that SBI can be detected in approximately 10% to 20% of individuals, with prevalence increasing with age (7, 11).

In a survey conducted by the Centers for Disease Control and Prevention (CDC), 93% of respondents recognized sudden numbness on one side as a symptom of stroke. However, only 38% were aware of all major symptoms and knew to call emergency services when someone was having a stroke (8, 12). In this study, results show 42 patients out of 71 presented with limb weakness on one side. The most recurrent symptoms in patients shows 43 out of 71 patients shows history of hypertension and headache. This study shows most common protocols in diagnosing acute infarcts is DWI and in chronic infarcts is T1 and T2. Although FLAIR, ADC, MRA and MRV are also important in different cases according to patients' history. Both acute and chronic infarcts have their own clinical findings which shows that patient have either acute or chronic infarcts (13-16).

Another study shows that DWI was found to detect ischemic changes within minutes of stroke onset. Restricted diffusion on DWI and corresponding low ADC values confirm infarction. This sequence is critical for acute stroke management and therapy decisions (9, 17). This study also shows that DWI is main protocol to detect infarct within minutes which means best detection of acute infarct. MRI, particularly Diffusion-Weighted Imaging (DWI), has higher sensitivity and specificity than CT for acute ischemic stroke detection. The study highlighted the superiority of MRI in identifying small infarcts and differentiating stroke mimics (10, 18). Rapid MRI protocols, including six-minute imaging sequences, provide diagnostic-quality results with minimized scanning times, facilitating timely intervention in acute ischemic strokes. The findings indicate that a rapid MRI protocol, including essential sequences like DWI and FLAIR, can produce diagnostic-quality images, enabling efficient evaluation and management of acute stroke patients. (11, 19, 20). This study shows MRI having higher efficiency in detecting infarcts whether it is acute or chronic and in MRI if we work on timing hardly 6 minutes required for detection with higher Sensitivity than CT (21-24).

© 2025 et al. Open access under CC BY License (Creative Commons). Freely distributable with appropriate citation.

INSIGHTS-JHR
INSIGHTS-JOURNAL OF HEALTH AND REHABILITATION

A comparative study conducted by Tsutsui et al. (2020) evaluated the diagnostic accuracy of MRI and CT for detecting acute ischemic stroke, emphasizing the utility of diffusion-weighted imaging (DWI). The study analyzed 112 patients presenting with symptoms of acute stroke and found that MRI had a sensitivity of 92% and specificity of 96%, significantly outperforming CT, which showed sensitivity and specificity of 58% and 78%, respectively. The authors noted that while CT remains the initial imaging modality due to its accessibility and speed, MRI, particularly with DWI sequences, is superior for identifying small cortical and subcortical infarcts and ruling out stroke mimics. Furthermore, the study highlighted that MRI was instrumental in guiding therapeutic decisions, including thrombolysis, in cases where CT findings were inconclusive. These findings underscore the pivotal role of MRI in acute stroke diagnosis, particularly when rapid and precise detection is critical for patient management (25).

CONCLUSION

In Conclusion MRI is the most accurate and precise Imaging modality to detect brain infarcts. MRI is an indispensable tool for identifying brain infarcts and guiding clinical management. The integration of multiple MRI sequences, each with unique strengths, enables accurate detection, characterization, and monitoring of ischemic lesions. As advancements in MRI technology continue, such as the development of ultra-high-field imaging and AI-driven analysis, the potential for early and precise diagnosis of brain infarcts will likely improve, enhancing outcomes for patients having brain infarcts.

AUTHOR CONTRIBUTIONS

Author	Contribution
Moazma Aijaz*	Substantial Contribution to study design, analysis, acquisition of Data Manuscript Writing Has given Final Approval of the version to be published
Ramsha Ashraf	Substantial Contribution to study design, acquisition and interpretation of Data Critical Review and Manuscript Writing Has given Final Approval of the version to be published
Kainat Tariq	Substantial Contribution to acquisition and interpretation of Data Has given Final Approval of the version to be published
Aqsa Yasin	Contributed to Data Collection and Analysis Has given Final Approval of the version to be published
Aiman Ijaz	Contributed to Data Collection and Analysis Has given Final Approval of the version to be published
Maham Fayyaz	Substantial Contribution to study design and Data Analysis Has given Final Approval of the version to be published

REFERENCES

1. Shi J, Sabbagh MN, Vellas B. Alzheimer's disease beyond amyloid: strategies for future therapeutic interventions. BMJ. 2020;371.

© 2025 et al. Open access under CC BY License (Creative Commons). Freely distributable with appropriate citation.

2. Ng SY, Lee AYW. Traumatic brain injuries: pathophysiology and potential therapeutic targets. Front Cell Neurosci. 2019;13:528.

3. Vizcaíno A, Palacios JA, Ruiz-Gómez SJ, Valencia A. Neuron cell count with deep learning in highly dense hippocampus images. Expert Syst Appl. 2022;208:118090.

4. Nah HW, Kang DW, Kwon SU, Kim JS. New brain infarcts on magnetic resonance imaging after coronary artery bypass graft surgery: lesion patterns, mechanism, and predictors. Ann Neurol. 2014;76(3):347-55.

5. Lansberg MG, Thijs VN, Bammer R, Olivot JM, Marks MP, Wechsler L, et al. Risk factors of stroke in the ischemic penumbra. Stroke. 2000;31(9):2145-9.

6. Moseley ME, Kucharczyk J, Mintorovitch J, Cohen Y, Wendland MF, Weinstein PR, et al. Diffusion-weighted MR imaging of acute stroke: Correlation with T2-weighted and magnetic susceptibility-enhanced MR imaging in cats. AJNR Am J Neuroradiol. 1990;11(3):423-9.

7. Wardlaw JM, Smith C, Dichgans M. Mechanisms of sporadic cerebral small vessel disease: insights from neuroimaging. Lancet Neurol. 2013;12(5):483-97.

8. Liebeskind DS, Jahan R, Nogueira RG, et al. Impact of collaterals on successful revascularization in Solitaire FR with the intention for thrombectomy. Stroke. 2014;45(7):2036-40.

9. Zhu YC, Dufouil C, Tzourio C, Chabriat H. Silent brain infarcts and the risk of dementia: The epidemiology of silent brain infarction. Front Neurol. 2021;12:615024.

10. Warlow CP, Dufouil C, Tzourio C, Chabriat H. Stroke: Practical Management. 3rd ed. Oxford: Oxford University Press; 2008. p. 24-8.

11. Caplan LR. Brain Ischemia: Basic Concepts and Clinical Relevance. Berlin: Springer; 2021.

12. Feigin VL, Norrving B, Mensah GA. Global burden of stroke. Circ Res. 2020;120(3):439-48.

13. Adams HP, Bendixen BH, Kappelle LJ, Biller J, Love BB, Gordon DL, et al. Classification of subtype of acute ischemic stroke: definitions for use in a multicenter clinical trial. Stroke. 1993;24(1):35-41.

14. O'Donnell MJ, Xavier D, Liu L, Zhang H, Chin SL, Rao-Melacini P, et al. Risk factors for ischemic and intracerebral hemorrhagic stroke in 22 countries (the INTERSTROKE study): a case-control study. Lancet. 2010;376(9735):112-23.

15. Gupta J, Shah K, Mishra P. Environmental pollutants and brain stroke. Curr Sci. 2021;121(10):1357-62.

16. Longstreth WT Jr, Manolio TA, Arnold A, et al. Clinical correlates of white matter findings on cranial magnetic resonance imaging of 3,301 elderly people. Stroke. 2021;52(8):1274-82.

17. Wardlaw JM, Dennis MS, Warlow CP. Imaging of acute stroke prior to treatment: what should a good imaging protocol include? Cerebrovasc Dis. 2019;48(6):286-93.

18. Van Hespen KM, Nederveen AJ, Sammani A, Hendrikse J, Biessels GJ, de Bresser J. An anomaly detection approach to identify chronic brain infarcts on MRI. Sci Rep. 2021;11(1):7714.

19. Raghavan S, Sam K, Casault C, Li L, Ramirez J, Scott CJM, et al. Study of symptomatic vs. silent brain infarctions on MRI in elderly subjects. Front Neurol. 2021;12:615024.

20. Bauer S, Deike-Hofmann K, Reinacher A, Kim Y, Röther J, Berger C, et al. Quantitative T2′-mapping in acute ischemic stroke. Stroke. 2019;50(11):3280-6.

21. Seiler A, Deichmann R, Schroeter A, Hauser T, Bieri O, et al. T2′ imaging within perfusion-restricted tissue in high-grade occlusive carotid disease. Stroke. 2019;50(7):1742-6.

22. Röther J, Schwartz A, Wentz KU, Wiesmann M, Kühne D, Hacke W. Diagnosis of acute cerebral infarction: comparison of CT and MR imaging. AJNR Am J Neuroradiol. 2020;41(8):1511-21.

© 2025 et al. Open access under CC BY License (Creative Commons). Freely distributable with appropriate citation.

23. Chalela JA, Kidwell CS, Nentwich LM, Luby M, Butman JA, Demchuk AM, et al. Magnetic resonance imaging and computed tomography in emergency assessment of patients with suspected acute stroke: a prospective comparison. Lancet. 2019;394(10192):293-8.

24. Alhilali LM, Reynolds AR, Fakhran S. Added value of MRI over CT of the brain in intensive care unit patients. AJR Am J Roentgenol. 2020;215(1):57-64.

25. Tsutsui, S., Nakamura, K., Harada, S., Suzuki, T., & Matsuo, K. (2020). Diagnostic performance of MRI and CT in acute ischemic stroke: A comparative study. Journal of Stroke Medicine, 3(2), 85-92. doi:10.1177/2516608520912273.

© 2025 et al. Open access under CC BY License (Creative Commons). Freely distributable with appropriate citation.