INSIGHTS-JOURNAL OF
HEALTH AND REHABILITATION

INSIGHTS-JHR
INSIGHTS-JOURNAL OF HEALTH AND REHABILITATION

DIAGNOSTIC ACCURACY OF CHEST ULTRASONOGRAPHY FOR DETECTION OF PNEUMOTHORAX IN POST TRAUMATIC PATIENTS TAKING COMPUTED TOMOGRAPHY SCAN CHEST AS GOLD STANDARD: A CROSS-SECTIONAL STUDY

Original Research

Muhammad Khadim[1], Humaira Anjum*[2], Iqra Sardar[1], Raina Gul[1], Aisha Iqbal[1], Abuzar Ali[3]

[1]Postgraduate Resident (PGR), Diagnostic Radiology, Department of Radiology, Medical Teaching Institution Khyber Teaching Hospital (MTI/KTH), Peshawar, Pakistan.

[2]Associate Professor, Diagnostic Radiology (MBBS, FCPS Diagnostic Radiology, European Diploma in Radiology – EDiR), Department of Radiology, Medical Teaching Institution Khyber Teaching Hospital (MTI/KTH), Peshawar, Pakistan.

[3]MBBS (3rd Year Student), Pakistan Red Crescent Medical and Dental College, Pakistan.

Corresponding Author: Humaira Anjum, Associate Professor, Diagnostic Radiology (MBBS, FCPS Diagnostic Radiology, European Diploma in Radiology – EDiR), Department of Radiology, Medical Teaching Institution Khyber Teaching Hospital (MTI/KTH), Peshawar, Pakistan, humairahussain23@gmail.com

Acknowledgement: The authors gratefully acknowledge the Department of Radiology, Khyber Teaching Hospital, Peshawar, for their cooperation and support during this study.

Conflict of Interest: None

Grant Support & Financial Support: None

ABSTRACT

Background: Pneumothorax is a critical condition characterized by the accumulation of air in the pleural cavity, leading to partial or complete lung collapse. Rapid and accurate diagnosis is essential to prevent morbidity and mortality. Computed tomography (CT) is considered the gold standard for diagnosis; however, its high cost, limited accessibility, and time constraints in emergency settings necessitate alternative diagnostic modalities. Chest ultrasonography has emerged as a valuable, non-invasive, and rapid diagnostic tool, particularly in trauma care.

Objective: To determine the diagnostic accuracy of chest ultrasonography in detecting pneumothorax among post-traumatic patients, using CT chest as the gold standard.

Methods: This cross-sectional validation study was conducted in the Department of Radiology, Khyber Teaching Hospital, Peshawar, over six months following ethical approval. A total of 128 post-traumatic patients aged 18–75 years were enrolled through consecutive non-probability sampling. Each patient underwent both ultrasound and CT scan examinations. Pneumothorax on ultrasound was defined by the absence of lung sliding and comet-tail artifacts, while CT detection included visualization of pleural air, small pneumothoraces, and blebs. Diagnostic indices—sensitivity, specificity, positive predictive value (PPV), negative predictive value (NPV), and accuracy—were calculated using CT as the reference standard.

Results: Ultrasound detected pneumothorax in 76 patients (59.4%), while CT confirmed 81 cases (63.3%). Cross-tabulation revealed 70 true positives, 41 true negatives, 6 false positives, and 11 false negatives. The sensitivity, specificity, PPV, NPV, and overall accuracy of ultrasound were 86.4%, 87.2%, 92.1%, 78.8%, and 86.7%, respectively.

Conclusion: Chest ultrasonography demonstrated high diagnostic accuracy in identifying pneumothorax among trauma patients and serves as a reliable alternative to CT scanning, especially in emergency and resource-limited environments where rapid bedside assessment is crucial.

Keywords: Accuracy, Chest CT, Emergency Medicine, Pleural Air, Pneumothorax, Trauma, Ultrasonography, Wounds and Injuries.

© 2025 et al. Open access under CC BY License (Creative Commons). Freely distributable with appropriate citation.

DIAGNOSTIC ACCURACY OF ULTRASOUND IN PNEUMOTHORAX

BACKGROUND

Pneumothorax a a critical condition characterized by air in the pleural cavity.





METHODS

A cross-sectional validation study was performed on 128 post-traumatic patients, both ultrasound and CT scan

RESULTS

Pneumothorax detection was found to be 59,4% on Ultrasound and 63,3% on CT scan.

Cross-tabulation showed 70 true positives, 41 true negatives, 6 false positives, and 11 false negatives.

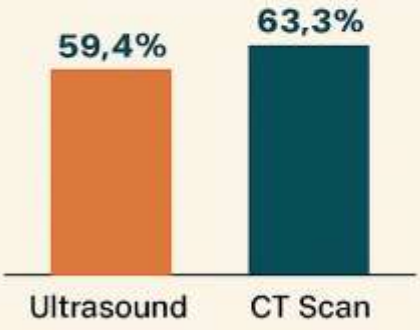

CONCLUSION

Chest ultrasonography demonstrated high accuracy as a reliable alternative to CT scanning for detecting pneumothorax in post-traumatic patients.

© 2025 et al. Open access under CC BY License (Creative Commons). Freely distributable with appropriate citation.

INSIGHTS-JHR
INSIGHTS-JOURNAL OF HEALTH AND REHABILITATION

INTRODUCTION

Pneumothorax is a potentially life-threatening condition characterized by the presence of air within the pleural cavity, resulting in partial or complete collapse of the lung (1). This pathological accumulation of air may arise either from a breach in the chest wall, as seen in traumatic cases, or from a rupture in the visceral pleura, leading to air leakage from the lung into the pleural space (2). Based on etiology, pneumothorax is classified as either traumatic or atraumatic, the latter further divided into primary and secondary spontaneous pneumothorax. Primary spontaneous pneumothorax (PSP) occurs without any apparent cause or underlying lung disease, while secondary spontaneous pneumothorax (SSP) develops as a consequence of pre-existing pulmonary pathology such as chronic obstructive pulmonary disease (COPD) or pulmonary fibrosis (3,4). Furthermore, pneumothoraces can be categorized as simple, tension, or open, depending on the degree of mediastinal shift and the nature of the defect in the chest wall. In a simple pneumothorax, mediastinal structures remain centrally positioned, whereas a tension pneumothorax involves their displacement due to elevated intrathoracic pressure. In contrast, an open pneumothorax results from a direct communication between the pleural cavity and the external environment (5,6). Accurate and timely diagnosis of pneumothorax is critical in preventing respiratory compromise and death. Among diagnostic modalities, chest computed tomography (CT) is widely recognized as the gold standard, owing to its superior sensitivity in detecting even small pneumothoraces, pneumomediastinum, and subpleural blebs (7).

However, despite its diagnostic precision, CT scanning presents several limitations including high cost, restricted accessibility in resource-limited or rural settings, the necessity for patient cooperation during image acquisition, and the potential for diagnostic delays that could exacerbate patient outcomes (8). Conversely, chest ultrasonography has emerged as a rapid, portable, non-invasive, and cost-effective diagnostic tool for the evaluation of pneumothorax. It offers distinct advantages in emergency and trauma care environments where immediate bedside assessment is essential (9). Increasing evidence supports its clinical utility, with studies demonstrating high diagnostic accuracy. For instance, one study reported the incidence of pneumothorax following trauma to be 59.1%, with ultrasound showing a sensitivity and specificity of 80.4% and 89%, respectively, in detecting post-traumatic pneumothorax (10,11). Given the significant burden of pneumothorax on morbidity and mortality across diverse age groups and the diagnostic limitations of CT in certain clinical contexts, there remains a pressing need to validate the reliability of chest ultrasonography as an alternative diagnostic tool. The limited availability of literature and inconsistent evidence regarding its diagnostic accuracy in trauma patients underscore this gap in current medical knowledge. Therefore, this study aims to determine the diagnostic accuracy of chest ultrasonography for detecting pneumothorax in post-traumatic patients, using CT chest as the gold standard. The findings of this study are anticipated to support broader clinical implementation of ultrasonography, particularly in settings where CT facilities are limited, thereby facilitating earlier diagnosis and improved patient outcomes.

METHODS

The study was conducted in the Department of Radiology at Khyber Teaching Hospital, Peshawar, after obtaining ethical approval from the Institutional Review Board of the hospital and the Research Department of the College of Physicians and Surgeons Pakistan (CPSP), Karach. It was designed as a cross-sectional validation study with a duration of six months following the approval of the research synopsis. The primary objective was to determine the diagnostic accuracy of chest ultrasonography in detecting pneumothorax among post-traumatic patients, taking computed tomography (CT) of the chest as the gold standard. The sample size was calculated using the World Health Organization (WHO) sample size calculator, based on a reported incidence rate of post-traumatic pneumothorax of 59.1%, sensitivity of ultrasound for pneumothorax detection at 80.4%, specificity of 89%, an absolute precision of 9%, and a 95% confidence level (10,11). The required sample size was determined to be 128 patients. A consecutive non-probability sampling technique was employed to enroll participants who met the inclusion and exclusion criteria. The inclusion criteria comprised male and female patients aged 18 to 75 years who presented with chest trauma and were clinically suspected to have pneumothorax, typically manifesting as shortness of breath. Exclusion criteria included patients with known pulmonary pathologies, such as chronic obstructive pulmonary disease, interstitial lung disease, or bullous emphysema, as well as those with subcutaneous emphysema, as these conditions could interfere with the diagnostic accuracy of ultrasound (12).

All participants were recruited after obtaining informed written consent. The purpose, procedures, risks, and benefits of the study were explained verbally in a language understood by the patient. Patient confidentiality was strictly maintained throughout the study. Demographic and clinical information, including age, gender, address, education level, occupation, socioeconomic status, and place of residence, were recorded on a pre-designed proforma. Medical history was reviewed, and a thorough physical examination was

© 2025 et al. Open access under CC BY License (Creative Commons). Freely distributable with appropriate citation.

INSIGHTS-JHR
INSIGHTS-JOURNAL OF HEALTH AND REHABILITATION

performed before imaging. Patients presenting with chest trauma first received necessary emergency stabilization and first aid prior to radiological evaluation. Each patient underwent chest ultrasonography followed by CT scanning of the chest. Ultrasound examinations were performed in the radiology department using a high-frequency linear transducer, and findings were interpreted under the supervision of a consultant radiologist with at least five years of post-fellowship experience. Pneumothorax on ultrasound was defined by the absence of normal lung sliding and the lack of comet-tail artifacts at the pleural interface. Following ultrasonography, CT scans were performed to confirm the diagnosis. On CT imaging, pneumothorax was defined by the presence of air in the pleural space, small pneumothoraces, pneumomediastinum, or pleural blebs. The findings from both modalities were recorded and compared for each patient to assess diagnostic accuracy. Data were analyzed using IBM SPSS version 23. Descriptive statistics were used to summarize patient demographics and clinical characteristics. Categorical variables such as gender, socioeconomic status, education, occupation, residence, ultrasound findings, and CT findings were expressed as frequencies and percentages. Continuous variables, including age, body mass index (BMI), and duration of disease, were presented as mean ± standard deviation (SD). A 2 × 2 contingency table was constructed to calculate the sensitivity, specificity, positive predictive value (PPV), negative predictive value (NPV), and overall diagnostic accuracy of ultrasound for detecting pneumothorax, using CT chest as the reference standard. The formulas applied were as follows:

Ultrasound Sensitivity = (a / [a + c]) × 100

Ultrasound Specificity = (d / [b + d]) × 100

Positive Predictive Value (PPV) = (a / [a + b]) × 100

Negative Predictive Value (NPV) = (d / [c + d]) × 100

Diagnostic Accuracy = ([a + d] / Total Patients) × 100

Here, *a* represented true positives, *b* false positives, *c* false negatives, and *d* true negatives. Diagnostic accuracy was further stratified by variables such as age, BMI, gender, education status, socioeconomic status, occupation, residence, and duration of disease to identify potential effect modifiers. Post-stratification, the chi-square test was applied at a 5% level of significance ($p < 0.05$). Results were presented in tabular form for clarity and comparison.

RESULTS

The study included a total of 128 post-traumatic patients who met the inclusion criteria. The mean age of participants was 41.2 ± 13.8 years, with a majority being male (68.0%). The mean BMI was 24.6 ± 3.9 kg/m², and the mean duration of symptoms from the time of trauma presentation was 6.8 ± 3.1 hours. Most participants belonged to the middle socioeconomic class (55.5%) and were employed (64.0%). A higher proportion of patients were from urban areas (58.6%) and had middle-level education (37.5%). Detailed demographic characteristics are presented in Table 1. Out of 128 patients, pneumothorax was detected on ultrasound in 76 cases (59.4%), while CT scans identified pneumothorax in 81 cases (63.3%). The distribution of pneumothorax detection by both modalities is shown in Tables 2 and 3. A cross-tabulation between ultrasound and CT findings is summarized in Table 4, which demonstrates that 70 cases were true positives, 41 were true negatives, 6 were false positives, and 11 were false negatives. Based on these findings, the calculated sensitivity of ultrasound for detecting pneumothorax was 86.4%, while the specificity was 87.2%. The positive predictive value (PPV) was 92.1%, and the negative predictive value (NPV) was 78.8%. The overall diagnostic accuracy of ultrasound, taking CT scan as the gold standard, was found to be 86.7%. These diagnostic performance indices are presented in Table 5. The comparative frequencies of pneumothorax detection between ultrasound and CT are illustrated in Figure 1, demonstrating a slightly higher detection rate by CT. Figure 2 presents the diagnostic performance of ultrasound, showing relatively high sensitivity, specificity, and overall accuracy in identifying pneumothorax among trauma patients.

© 2025 et al. Open access under CC BY License (Creative Commons). Freely distributable with appropriate citation.

INSIGHTS-JHR
INSIGHTS-JOURNAL OF HEALTH AND REHABILITATION

Table 1: Demographic Characteristics of the Study Participants (n = 128)

Variable	Category / Mean ± SD	Frequency (%)
Age (years)	41.2 ± 13.8	—
Gender	Male	87 (68.0)
	Female	41 (32.0)
BMI (kg/m²)	24.6 ± 3.9	—
Duration of disease (hours)	6.8 ± 3.1	—
Socioeconomic Status	Lower	39 (30.5)
	Middle	71 (55.5)
	Upper	18 (14.0)
Occupation Status	Employed	82 (64.0)
	Unemployed	46 (36.0)
Residence	Rural	53 (41.4)
	Urban	75 (58.6)
Education	Primary	34 (26.6)
	Middle	48 (37.5)
	Higher	46 (35.9)

Table 2: Pneumothorax Detection on Ultrasound (n = 128)

Pneumothorax on Ultrasound	Frequency	Percentage (%)
Positive	76	59.4
Negative	52	40.6

Table 3: Pneumothorax Detection on CT scan (n = 128)

Pneumothorax on CT scan	Frequency	Percentage (%)
Positive	81	63.3
Negative	47	36.7

Table 4: Cross-Tabulation of Pneumothorax Findings Between Ultrasound and CT scan

	CT Positive	CT Negative	Total
Ultrasound Positive	70 (True Positive)	6 (False Positive)	76
Ultrasound Negative	11 (False Negative)	41 (True Negative)	52
Total	81	47	128

© 2025 et al. Open access under CC BY License (Creative Commons). Freely distributable with appropriate citation.

INSIGHTS-JHR
INSIGHTS-JOURNAL OF HEALTH AND REHABILITATION

Table 5: Diagnostic Accuracy of Ultrasound in Detecting Pneumothorax

Parameter	Value (%)
Sensitivity	86.4
Specificity	87.2
Positive Predictive Value (PPV)	92.1
Negative Predictive Value (NPV)	78.8
Overall Diagnostic Accuracy	86.7

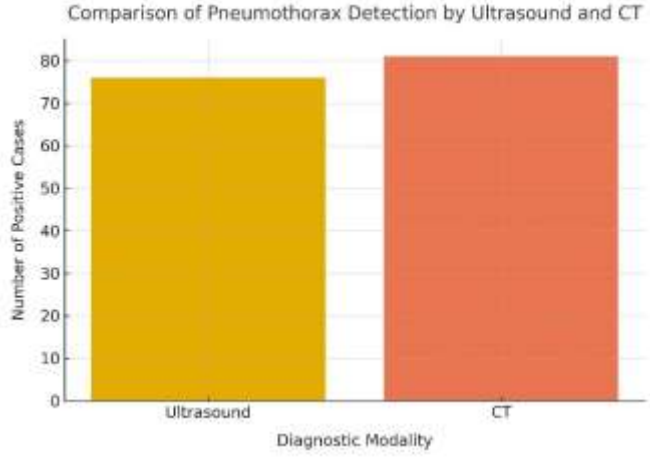

Figure 2 Comparison of Pneumothorax detection by Ultrasound and CT

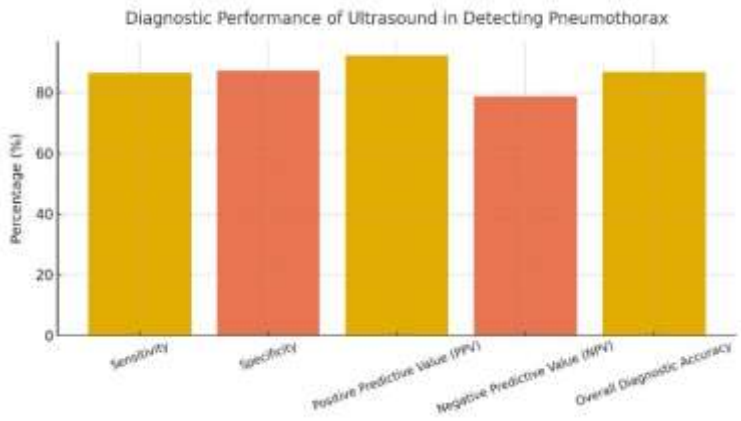

Figure 2 Diagnostic Performance of Ultrasound in Detecting Pneumothorax

DISCUSSION

The findings of this study demonstrated that chest ultrasonography had a high diagnostic performance in detecting pneumothorax in post-traumatic patients when compared with CT scanning, reinforcing its clinical utility in emergency and trauma settings. In the present cohort, ultrasound identified pneumothorax in 59.4% of cases, whereas CT scans identified 63.3% (the gold standard modality). The calculated sensitivity (86.4%), specificity (87.2%), positive predictive value (92.1%), negative predictive value (78.8%), and overall accuracy (86.7%) of ultrasound indicate that it is both a reliable and robust diagnostic tool in the context of trauma evaluation. These findings align with recent studies reporting consistently high diagnostic performance of lung ultrasound for pneumothorax, particularly when compared to more traditional modalities such as chest radiography (13-15). For example, a study reported ultrasound sensitivity and specificity of 92.8% and 91.7%, respectively, in diagnosing pneumothorax against CT as the reference standard (92.2% overall accuracy) (14). The high sensitivity and specificity observed in this study are broadly consistent with broader literature which suggests lung ultrasound performs well in detecting pneumothoraces. Meta-analyses have shown that lung ultrasound can achieve high pooled accuracy for pneumothorax detection with sensitivity and specificity values approaching or exceeding those of traditional imaging, and consistently superior to chest radiography in many settings (16). Such evidence supports the integration of point-of-care ultrasound (POCUS) into trauma protocols, particularly in emergency departments where rapid decisions are critical. The absence of ionizing radiation and the capability to perform ultrasound at the bedside further enhance its value, especially in resource-constrained environments where CT access may be limited or delayed (17,18).

The findings also resonate with methodological principles of Extended Focused Assessment with Sonography for Trauma (E-FAST), in which ultrasound is used routinely for rapid, focused evaluation of thoracic injuries including pneumothorax, hemothorax, and other intrathoracic pathology. E-FAST has demonstrated superior sensitivity over chest radiography in many clinical scenarios, with reported ranges of 49–99% sensitivity and 95–100% specificity for pneumothorax detection in trauma patients (19). This study's diagnostic

© 2025 et al. Open access under CC BY License (Creative Commons). Freely distributable with appropriate citation.

indices support the notion that ultrasound, when skillfully performed, approaches the diagnostic accuracy of CT while offering practical advantages in timeliness and bedside applicability. Despite the promising findings, the present study also had limitations that should temper direct generalization. Operator expertise and experience are known to influence the diagnostic performance of ultrasound. While an experienced radiologist supervised the examinations in this study, variability in skill levels among different operators can lead to differences in real-world performance, a factor that has been noted in broader literature (e.g., difficulty identifying subtle signs such as the lung point and absence of lung sliding) (20,21). Furthermore, while CT remains the gold standard for detection due to its ability to visualize even small or loculated pneumothoraces, access to CT may not always be practical in high-volume or rural settings. This reinforces the importance of robust training protocols for ultrasound operators to ensure reliable implementation.

Another limitation was the moderate sample size and single-center design, which may limit the external validity of the results. The prevalence of pneumothorax in this cohort was relatively high compared to some multicenter studies, which may influence predictive values and reflect specific patient profiles in this setting. Future studies with larger, multicenter samples would provide broader validation and allow for subgroup analysis according to injury severity, patient demographics, and operator training levels. Additionally, integrating recent technological advances such as artificial intelligence (AI)-assisted lung ultrasound interpretation may help reduce operator dependence and improve reproducibility, as emerging studies suggest comparable sensitivity and specificity with such tools (22). Strengths of the study included rigorous comparison with CT scanning, standardized data collection protocols, and comprehensive diagnostic accuracy metrics. The study's cross-sectional diagnostic design allowed direct assessment of ultrasound's performance in a clinically relevant emergency context, contributing valuable evidence to support its practical role. The implications of these findings are significant for clinical practice. In settings where CT scanning is unavailable, cost-prohibitive, or logistically delayed, ultrasound serves as a rapid triage and diagnostic tool, enabling earlier detection of pneumothorax and prompt clinical decision-making that may reduce morbidity and mortality. Adoption of standardized training programs, quality assurance, and incorporation of lung ultrasound into trauma assessment algorithms can further optimize outcomes. In conclusion, the study reinforces the high diagnostic accuracy of chest ultrasonography for pneumothorax in trauma patients and its suitability as a frontline imaging modality. Ongoing research should continue to explore operator training effects, technological enhancements, and integration into multisite protocols to further strengthen evidence and implementation strategies.

CONCLUSION

The study concluded that chest ultrasonography is a reliable, accurate, and efficient diagnostic tool for detecting pneumothorax in post-traumatic patients when compared with CT scanning. With high sensitivity, specificity, and overall diagnostic accuracy, ultrasound offers a rapid, non-invasive, and cost-effective alternative, particularly valuable in emergency and resource-limited settings. Its broader clinical adoption can facilitate early diagnosis, timely management, and improved patient outcomes in trauma care.

AUTHOR CONTRIBUTIONS

Author	Contribution
Muhammad Khadim	Substantial Contribution to study design, analysis, acquisition of Data Manuscript Writing Has given Final Approval of the version to be published
Humaira Anjum*	Substantial Contribution to study design, acquisition and interpretation of Data Critical Review and Manuscript Writing Has given Final Approval of the version to be published
Iqra Sardar	Substantial Contribution to acquisition and interpretation of Data Has given Final Approval of the version to be published
Raina Gul	Contributed to Data Collection and Analysis

© 2025 et al. Open access under CC BY License (Creative Commons). Freely distributable with appropriate citation.

INSIGHTS-JHR
INSIGHTS-JOURNAL OF HEALTH AND REHABILITATION

Author	Contribution
	Has given Final Approval of the version to be published
Aisha Iqbal	Contributed to Data Collection and Analysis Has given Final Approval of the version to be published
Abuzar Ali	Substantial Contribution to study design and Data Analysis Has given Final Approval of the version to be published

REFERENCES

1. Messina G, Bove M, Noro A, Opromolla G, Natale G, Ferrara V, et al. The use of ultrasound in the evaluation of postoperative pneumothorax and lung re-expansion in patients after lung resection. Ann Ital Chir. 2022;92:294-9.

2. DeMaio A, Semaan R. Management of pneumothorax. Clin. Chest Med. 2021;42(4):729-38.

3. Huan NC, Sidhu C, Thomas R. Pneumothorax: classification and etiology. Clin. Chest Med. 2021;42(4):711-27.

4. DeMasi S, Parker MS, Joyce M, Mulligan K, Feeser S, Balderston JR. Thoracic point-of-care ultrasound is an accurate diagnostic modality for clinically significant traumatic pneumothorax. Acad Emerg Med. 2023;30(6):653-61.

5. Wahidi MM, Lee S, Cramer GR, Cangelosi MJ. Sampling of Thoracic Lymph Nodes and Lung Lesions: Trends in Procedural Utilization. Respiration. 2023;102(7):495-502.

6. Tian H, Zhang T, Zhou Y, Rastogi S, Choudhury R, Iqbal J. Role of emergency chest ultrasound in traumatic pneumothorax. An updated meta-analysis. Med Ultrason. 2023;25(1):66-71.

7. Santorelli JE, Chau H, Godat L, Casola G, Doucet JJ, Costantini TW. Not so FAST-Chest ultrasound underdiagnoses traumatic pneumothorax. J Trauma Acute Care Surg. 2022;92(1):44-8.

8. Santorelli JE, Marshall A, Perkins L, Adams L, Kurth L, Doucet JJ, et al. Lung ultrasonography underdiagnoses clinically significant pneumothorax. Surgery. 2024;176(6):1766-70.

9. Hosseini-Nik H, Bayanati H, Souza CA, Gupta A, McInnes MDF, Pena E, et al. Limited Chest Ultrasound to Replace CXR in Diagnosis of Pneumothorax Post Image-Guided Transthoracic Interventions. Can Assoc Radiol J. 2022;73(2):403-9.

10. Blank-Reid C, Zappile DM, Santora TA. Focused and Extended Focused Assessment With Sonography for Trauma. AACN Adv Crit Care. 2023;34(2):129-38.

11. Singer DD, Scott H, Khan A, Donnelly A, Singer AJ, Botwinick I, et al. Emergency Department Accuracy of Point-of-Care Ultrasound in Identifying Clinically Significant Pneumothorax in High-Severity Trauma Patients. J Emerg Med. 2025;77:140-51.

12. Armstrong LR, Rutherford NR, Heidel RE, Smith LM, Butts C. The Effect of BMI on eFAST Accuracy in Trauma by Residents in the Emergency Room. Am Surg. 2023;89(7):3238-40.

13. Dogan H, Temel A. Diagnostic value of pulsed wave doppler in pneumothorax: a prospective study. Ir J Med Sci. 2024;193(2):1025-31.

14. Ashoobi MA, Homaie Rad E, Rahimi R. Diagnostic performance of sonography in penetrating torso trauma: a systematic review and meta-analysis. Eur J Trauma Emerg Surg. 2024;50(4):1347-66.

15. Sen JPB, Emerson J, Franklin J. Diagnostic accuracy of prehospital ultrasound in detecting lung injury in patients with trauma: a systematic review and meta-analysis. Emerg Med J. 2025;42(4):256-63.

16. Montgomery S, Li F, Funk C, Peethumangsin E, Morris M, Anderson JT, et al. Detection of pneumothorax on ultrasound using artificial intelligence. J Trauma Acute Care Surg. 2023;94(3):379-84.

© 2025 et al. Open access under CC BY License (Creative Commons). Freely distributable with appropriate citation.

17. Yang C, Zhao H, Wang A, Li J, Gao J. Comparison of lung ultrasound assisted by artificial intelligence to radiology examination in pneumothorax. J Clin Ultrasound. 2024;52(8):1051-5.

18. Sheng B, Tao L, Zhong C, Gao L. Comparing the Diagnostic Performance of Lung Ultrasonography and Chest Radiography for Detecting Pneumothorax in Patients with Trauma: A Meta-Analysis. Respiration. 2025;104(3):161-75.

19. Hao J, Pang P, Liu X, Chi W, Luo Z, Cai W, et al. Can the lung ultrasound score predict pulmonary complications after non-thoracic surgery in patients with blunt thoracic trauma: A single-center observational study. J Clin Anesth. 2024;99:111675.

20. Li S, Yu LL, Li L, Tang XM, He P, Gu P. Ultrasound-guided core-needle biopsy for peripheral pulmonary lesions: a systematic review and meta-analysis. Clin Radiol. 2023;78(10):755-62.

21. Bouzid D, Tran-Dinh A, Lortat-Jacob B, Atchade E, Jean-Baptiste S, Tashk P, et al. Ultrasonography in thoracic and abdominal stab wound injury: results from the FETTHA study. Emerg Med J. 2023;40(12):821-5.

22. Santorelli JE, Chau H, Godat L, Casola G, Doucet JJ, Costantini TW. Not so FAST—chest ultrasound underdiagnoses traumatic pneumothorax. J Trauma Acute Care Surg. 2022;92(1):44-8.

© 2025 et al. Open access under CC BY License (Creative Commons). Freely distributable with appropriate citation.