INSIGHTS-JOURNAL OF
HEALTH AND REHABILITATION

INSIGHTS-JHR
INSIGHTS-JOURNAL OF HEALTH AND REHABILITATION

DIAGNOSTIC ACCURACY OF ULTRASONOGRAPHY IN DIAGNOSING ACUTE PANCREATITIS TAKING COMPUTED TOMOGRAPHY AS GOLD STANDARD

Original Research

Iqra Sardar[1], Hina Gul[2]*, Muhammad Khadim[1], Ayesha Begum[1], Raina Gul[1]

[1]PGR Diagnostic Radiology, Department of Radiology, Medical Teaching Institution (MTI), Khyber Teaching Hospital (KTH), Peshawar, Pakistan.

[2]Professor Diagnostic Radiology, Medical Teaching Institution (MTI), Khyber Teaching Hospital (KTH), Peshawar, Pakistan.

Corresponding Author: Hina Gul, Professor Diagnostic Radiology, Medical Teaching Institution (MTI), Khyber Teaching Hospital (KTH), Peshawar, Pakistan, hina.gul@kmc.edu.pk

Acknowledgement: The authors sincerely thank the Department of Radiology, Khyber Teaching Hospital, Peshawar, for their support and cooperation throughout the study.

Conflict of Interest: None

Grant Support & Financial Support: None

ABSTRACT

Background: Acute pancreatitis is a frequent and potentially severe inflammatory disorder of the pancreas associated with significant morbidity and mortality. Early and accurate diagnosis is crucial to prevent complications and guide timely management. While contrast-enhanced computed tomography (CT) remains the gold standard for diagnosis, ultrasonography offers a non-invasive, readily available, and cost-effective alternative, especially in resource-limited settings.

Objective: To determine the diagnostic accuracy of ultrasonography in detecting acute pancreatitis, using contrast-enhanced CT as the gold standard.

Methods: This cross-sectional validation study was conducted at the Department of Radiology, Khyber Teaching Hospital, MTI, Peshawar, over six months. A total of 192 patients aged 18–80 years with clinical suspicion of acute pancreatitis were enrolled through non-probability consecutive sampling. Ultrasonography was performed by an experienced radiologist, followed by CT scanning for confirmation. Findings from both modalities were compared, and diagnostic parameters including sensitivity, specificity, positive predictive value (PPV), negative predictive value (NPV), and diagnostic accuracy were calculated using IBM SPSS version 25.

Results: The mean age of participants was 45.8 ± 13.2 years, with 55.2% males. Ultrasonography detected acute pancreatitis in 72 patients (37.5%), while CT confirmed 68 cases (35.4%). Comparison between modalities showed 60 true positives, 12 false positives, 8 false negatives, and 112 true negatives. Ultrasonography yielded a sensitivity of 88.2%, specificity of 90.3%, PPV of 83.3%, NPV of 93.3%, and overall diagnostic accuracy of 89.6%.

Conclusion: Ultrasonography demonstrated high diagnostic accuracy in detecting acute pancreatitis when compared with CT, supporting its role as an effective initial diagnostic modality. Its use can significantly aid early detection and management, particularly in facilities where CT access is limited.

Keywords: Acute Pancreatitis, Computed Tomography, Diagnostic Accuracy, Predictive Value, Radiology, Sensitivity, Specificity, Ultrasonography.

© 2025 et al. Open access under CC BY License (Creative Commons). Freely distributable with appropriate citation.

INSIGHTS-JOURNAL OF
HEALTH AND REHABILITATION

INSIGHTS-JHR
INSIGHTS-JOURNAL OF HEALTH
AND REHABILITATION

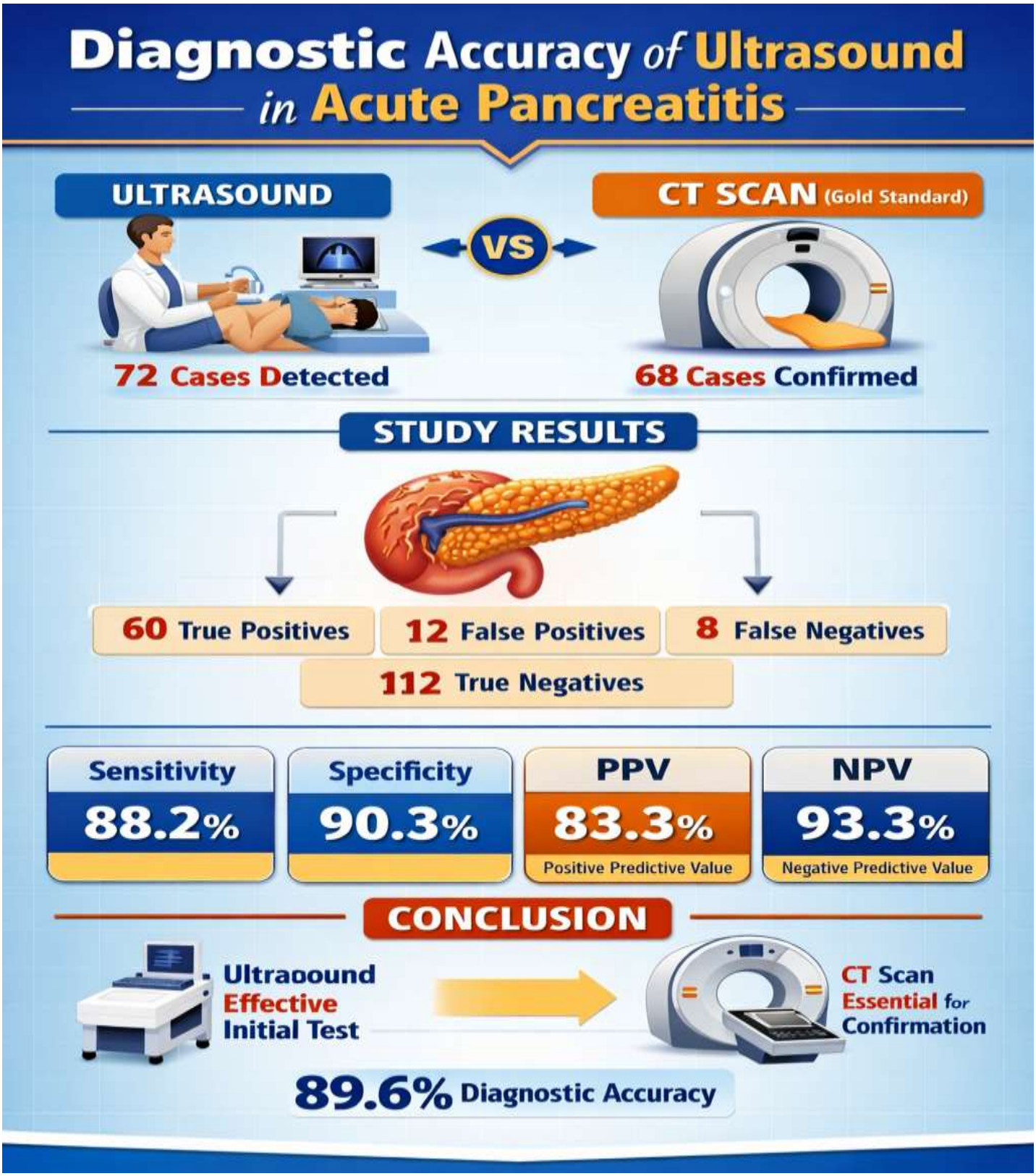

© 2025 et al. Open access under CC BY License (Creative Commons). Freely distributable with appropriate citation.

INSIGHTS-JHR
INSIGHTS-JOURNAL OF HEALTH AND REHABILITATION

INTRODUCTION

Acute pancreatitis is a common inflammatory disorder of the exocrine pancreas characterized by sudden and severe abdominal pain, often accompanied by multi-organ dysfunction. If left untreated, the condition can progress to pancreatic necrosis and irreversible organ failure, contributing to a mortality rate ranging from 1–5% (1). The global incidence of acute pancreatitis is estimated to be approximately 30–40 cases per 100,000 individuals per year, though some regions report rates nearly double this figure (2). Among children, the incidence is also notable, with 10–15 cases reported per 100,000 annually (3). The disease carries substantial short- and long-term morbidity, with a subset of patients experiencing chronic inflammation, exocrine or endocrine pancreatic insufficiency, and persistent debility (4). Furthermore, chronic pain, recurrent hospitalizations, and associated financial and social burdens significantly impair quality of life, an aspect frequently underestimated in clinical practice (5,6). Despite the considerable impact of acute pancreatitis, no pharmacological therapy has yet been internationally approved to modify its disease course. This limitation may be attributed to an incomplete understanding of the underlying pathophysiology and inappropriate selection of therapeutic targets (7). Early diagnosis is crucial, as it markedly improves patient outcomes, guides management, and reduces complications associated with necrotizing pancreatitis. Ultrasonography (US) serves as a useful initial diagnostic tool for confirming suspected cases due to its non-invasiveness, availability, and cost-effectiveness (8). However, contrast-enhanced computed tomography (CT) remains the gold standard for diagnosing acute pancreatitis, given its superior ability to detect the extent of inflammation, necrosis, and related complications (9,10).

Although the diagnosis of mild cases is often straightforward, the routine use of CT in all patients is generally unwarranted. Studies have demonstrated a detection rate of 35.4% for acute pancreatitis using ultrasound, with reported sensitivity and specificity values of 90.77% and 86.81%, respectively (11,12). Imaging thus plays a pivotal role in the management of acute pancreatitis by delineating disease severity and complications. Nevertheless, the diagnostic performance of ultrasonography relative to CT remains an area of ongoing clinical interest, particularly in regions lacking extensive local data. Given the limited literature and absence of regional studies, this research seeks to address the knowledge gap by assessing the diagnostic accuracy of ultrasonography for detecting acute pancreatitis using CT as the reference standard. The objective of this study is to determine the diagnostic accuracy—including sensitivity, specificity, positive predictive value, and negative predictive value—of ultrasonography in diagnosing acute pancreatitis, taking contrast-enhanced computed tomography as the gold standard. This investigation aims to provide valuable local data and explore the potential of ultrasonography as a reliable, accessible, and cost-effective alternative for diagnosing acute pancreatitis.

METHODS

The present study employed a cross-sectional validation design conducted in the Department of Radiology, Khyber Teaching Hospital, Medical Teaching Institution (MTI), Peshawar. The study was carried out over a period of at least six months following the approval of the research synopsis by the institutional ethical review board and the Research Department of the College of Physicians and Surgeons Pakistan (CPSP), Karachi. Ethical approval was obtained before the initiation of data collection, and written informed consent was obtained from all participants after explaining the study objectives, potential benefits, and associated risks. Confidentiality and anonymity of participants were maintained throughout the research process in accordance with institutional ethical guidelines. A total of 192 patients were enrolled in the study. The sample size was calculated considering the reported occurrence of acute pancreatitis (35.4%) (11), with the sensitivity and specificity of ultrasonography being 90.77% and 86.81%, respectively (12), an absolute precision of 7%, and a 95% confidence level. Non-probability consecutive sampling was employed to recruit participants who met the inclusion criteria. Patients of both genders, aged 18 to 80 years, suspected of having acute pancreatitis and presenting with clinical features such as sudden onset of abdominal pain with a Visual Analogue Scale (VAS) score greater than 4, tachycardia (heart rate >120/min), fever exceeding 101°F, and elevated serum amylase levels above 400 U/L were included. Exclusion criteria comprised patients with chronic kidney failure and those who were claustrophobic, as they could not safely undergo CT imaging (13,14).

After obtaining informed consent, demographic and clinical details—including age, gender, educational status, occupation, socioeconomic class, and area of residence—were recorded on a pre-designed proforma. All patients underwent a comprehensive medical evaluation and physical examination. Ultrasonography was performed in the hospital's radiology department using a high-resolution ultrasound machine by an experienced radiologist. The ultrasound examination assessed features such as pancreatic glandular enlargement, altered echogenicity, peripancreatic fluid collections, and pancreatic duct dilatation. Subsequently, each participant underwent a contrast-enhanced computed tomography (CT) scan of the abdomen. The CT scans were interpreted by a consultant radiologist with a minimum of five years of post-fellowship experience, evaluating for findings including focal or diffuse pancreatic

© 2025 et al. Open access under CC BY License (Creative Commons). Freely distributable with appropriate citation.

INSIGHTS-JHR
INSIGHTS-JOURNAL OF HEALTH AND REHABILITATION

enlargement, fascial plane thickening, irregular pancreatic margins, and intraperitoneal fluid accumulation. All imaging results were documented, and the findings of ultrasonography were compared with those of CT scans, which served as the gold standard for diagnosis. Statistical analysis was performed using IBM SPSS version 25. Numerical variables such as age, body mass index (BMI), and duration of illness were expressed as mean ± standard deviation (SD), while categorical variables such as gender, education, occupation, socioeconomic status, area of residence, and imaging findings were presented as frequencies and percentages. A 2×2 contingency table was constructed to calculate the diagnostic parameters of ultrasonography, including sensitivity, specificity, positive predictive value (PPV), negative predictive value (NPV), and overall diagnostic accuracy, using the following standard formulas:

- Sensitivity = (a / a + c) × 100
- Specificity = (d / b + d) × 100
- PPV = (a / a + b) × 100
- NPV = (d / c + d) × 100
- Diagnostic Accuracy = (a + d) / Total Patients × 100

where “a” denotes true positives, “b” false positives, “c” false negatives, and “d” true negatives. Diagnostic accuracy was further stratified by age, gender, BMI, disease duration, education, profession, socioeconomic status, and area of residence to identify potential effect modifiers. Post-stratification, the chi-square test was applied at a 5% level of significance to assess statistical associations. Results were presented in tables for clarity and interpretability. Overall, the methodology ensured a standardized and ethically sound approach to evaluating the diagnostic performance of ultrasonography in comparison with contrast-enhanced computed tomography for the detection of acute pancreatitis.

RESULTS

A total of 192 patients suspected of acute pancreatitis were enrolled in the study. The mean age of participants was 45.8 ± 13.2 years, with a slightly higher proportion of males (55.2%) compared to females (44.8%). The mean body mass index (BMI) was 26.4 ± 3.8 kg/m², and the mean duration of disease prior to hospital presentation was 4.8 ± 1.9 days. Regarding socioeconomic distribution, the majority of participants belonged to the middle socioeconomic class (49.0%), followed by the lower (37.5%) and upper (13.5%) classes. More than half of the participants were employed (61.5%), and 53.1% were residents of rural areas, while 46.9% resided in urban regions. Educational attainment was evenly distributed, with 25.0% having primary education, 37.5% middle, and 37.5% higher education levels (Table 1). On ultrasonographic evaluation, acute pancreatitis was detected in 72 patients (37.5%), while 120 (62.5%) showed no ultrasonographic evidence of the disease. Computed tomography (CT), used as the gold standard, confirmed the diagnosis in 68 patients (35.4%), whereas 124 (64.6%) had no CT evidence of pancreatitis (Table 2). Comparison of both imaging modalities revealed that 60 patients were true positives (disease confirmed on both ultrasound and CT), 12 were false positives, 8 were false negatives, and 112 were true negatives. Based on these findings, the sensitivity of ultrasonography for diagnosing acute pancreatitis was calculated at 88.2%, and specificity was 90.3%. The positive predictive value (PPV) was 83.3%, and the negative predictive value (NPV) was 93.3%. The overall diagnostic accuracy of ultrasonography, when compared with CT, was 89.6% (Table 3).

When results were stratified according to demographic and clinical variables, sensitivity and specificity were slightly higher among patients under 50 years of age and those with a BMI below 28 kg/m². No significant variation in diagnostic accuracy was observed concerning gender or area of residence. The chi-square test showed no statistically significant association between demographic variables and diagnostic accuracy ($p > 0.05$). The findings are further illustrated in Figures 1 and 2. Figure 1 demonstrates the gender distribution of study participants, indicating a modest male predominance. Figure 2 compares the number of patients diagnosed with acute pancreatitis using ultrasonography and CT imaging, showing close agreement between the two modalities. Collectively, the results demonstrate a high diagnostic performance of ultrasonography for identifying acute pancreatitis, closely approximating that of computed tomography, with strong sensitivity, specificity, and predictive values within the study population.

© 2025 et al. Open access under CC BY License (Creative Commons). Freely distributable with appropriate citation.

INSIGHTS-JHR
INSIGHTS-JOURNAL OF HEALTH AND REHABILITATION

Table 1: Demographic Characteristics of Study Participants (n = 192)

Variable	Values (mean ± SD, n %)
Age (years)	45.8 ± 13.2
Gender	
Male	106 (55.2%)
Female,	86 (44.8%)
BMI (kg/m²)	26.4 ± 3.8
Duration of Disease (days,)	4.8 ± 1.9
Socioeconomic Status	
Lower	72 (37.5%)
Middle	94 (49.0%)
Upper	26 (13.5%)
Occupation	
Employed	118 (61.5%)
Unemployed	74 (38.5%)
Residence	
Rural	102 (53.1%)
Urban	90 (46.9%)
Education	
Primary	48 (25.0%)
Middle	72 (37.5%)
Higher	72 (37.5%)

Table 2: Comparison of Ultrasound and CT Findings in Acute Pancreatitis

Findings	Ultrasound (+)	Ultrasound (−)
Acute Pancreatitis on CT (+)	60	8
Acute Pancreatitis on CT (−)	12	112

Table 3: Diagnostic Accuracy of Ultrasound in Diagnosing Acute Pancreatitis

Parameter	Value (%)
Sensitivity	88.2
Specificity	90.3
Positive Predictive Value (PPV)	83.3
Negative Predictive Value (NPV)	93.3
Diagnostic Accuracy	89.6

© 2025 et al. Open access under CC BY License (Creative Commons). Freely distributable with appropriate citation.

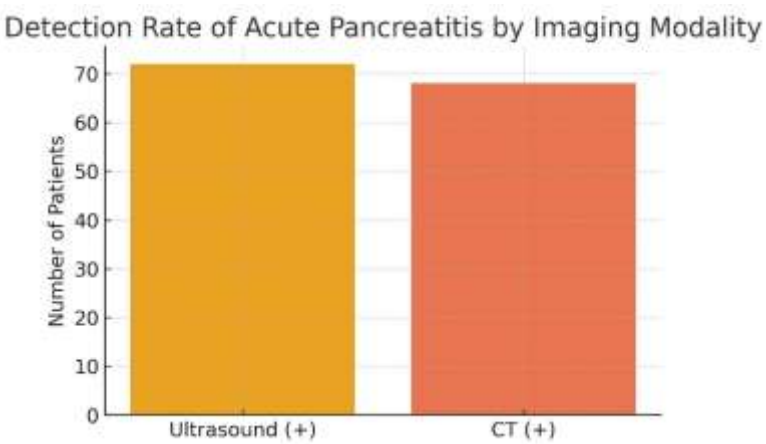

Figure 2 Detection Rate of Acute Pancreatitis by Imaging Modality

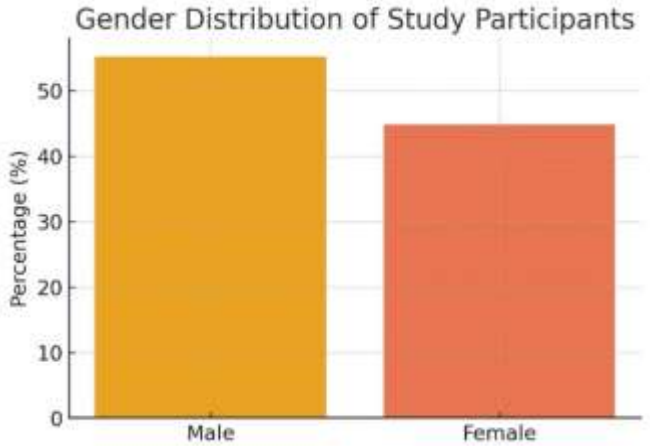

Figure 2 Gender Distribution of Study Participants

DISCUSSION

The results of the present study demonstrated a high diagnostic performance of transabdominal ultrasonography in detecting acute pancreatitis when compared to contrast-enhanced computed tomography (CT), which served as the reference standard. The sensitivity of ultrasonography was 88.2%, specificity was 90.3%, positive predictive value (PPV) was 83.3%, and negative predictive value (NPV) was 93.3%, yielding an overall diagnostic accuracy of 89.6%. These findings indicate that in this cohort ultrasonography correctly identified the majority of true positive and true negative cases when benchmarked against CT imaging, supporting its potential utility in clinical settings as a non-invasive initial diagnostic tool. Comparative interpretation of these findings with previously published literature reveals mixed but informative results. A cross-sectional study from Lahore reported results of similar magnitude, with ultrasonography showing a sensitivity of 90.77%, specificity of 86.81%, and a diagnostic accuracy of 88.46% relative to CT, reinforcing the high performance of ultrasound observed in the current study (15). This concordance suggests that under optimal conditions and with experienced operators, ultrasound can provide reliable diagnostic information. Conversely, other research has documented much lower diagnostic performance for ultrasound. In a study conducted at a tertiary care facility in Islamabad, ultrasonography demonstrated a sensitivity of only 41% and a specificity of 35.1%, resulting in a diagnostic accuracy of 37.6% when compared with CT (16). Such discrepancies likely reflect differences in operator expertise, patient habitus, timing of imaging, and equipment quality, which are known to impact ultrasonographic visualization of the pancreas. A separate comparative analysis found that ultrasonography had a sensitivity of 64% compared with CT's 96% in detecting acute pancreatitis features, reiterating the limitations of ultrasound in certain clinical scenarios (17). These contrasting results underscore the variability inherent in ultrasonographic diagnosis of acute pancreatitis, highlighting that while it may achieve high diagnostic accuracy in controlled settings, its performance is not universally consistent across all clinical environments.

Notwithstanding these variations, CT remains widely acknowledged as the gold standard for imaging in acute pancreatitis because of its superior capability to visualize pancreatic morphology, parenchymal changes, and associated complications such as necrosis, fluid collections, and extra-pancreatic inflammatory spread. Clinical guidelines emphasize that CT is most valuable when the diagnosis is unclear, when complications are suspected, or when assessing disease severity, particularly beyond the first 48–72 hours after symptom onset (18,19). MRI has also been shown in recent systematic evaluations to offer even higher sensitivity and specificity than CT in some settings, although cost, availability, and access issues limit its routine use (20). The findings of the present study have important clinical implications. The high sensitivity and specificity observed for ultrasonography suggest that, in appropriately selected patients and with skilled operators, it can serve as a useful first-line imaging modality. Its advantages include lack of ionizing radiation, relative lower cost, and immediate bedside availability, which are particularly valuable in resource-limited settings or in initial assessment of suspected acute pancreatitis. However, the variability in diagnostic performance reported across different studies highlights the necessity of corroborating ultrasonographic findings with CT, especially when ultrasound results are equivocal, when clinical suspicion remains high despite negative ultrasonography, or when signs of severe pancreatitis or complications are present.

© 2025 et al. Open access under CC BY License (Creative Commons). Freely distributable with appropriate citation.

INSIGHTS-JHR
INSIGHTS-JOURNAL OF HEALTH AND REHABILITATION

The strengths of this study include a standardized imaging protocol and comparison with CT as the diagnostic reference, which strengthens the validity of the diagnostic accuracy measures reported. The inclusion of a balanced sample from an authentic clinical population enhances the generalizability of the findings within similar healthcare settings. Despite these strengths, certain limitations must be acknowledged. First, ultrasonography is inherently operator-dependent, and variations in technique and experience can significantly influence outcomes; this variability was not fully controlled for in this study. Second, factors such as patient body habitus, bowel gas, and timing of imaging relative to symptom onset can impair ultrasonographic visualization of the pancreas and were not systematically adjusted for in the analysis. Third, the study did not stratify diagnostic performance by severity of pancreatitis, which could provide additional insights into the differential performance of imaging modalities in mild versus severe disease. Future research should aim to address these limitations by incorporating multicenter designs, larger sample sizes, and stratification by disease severity and patient factors such as obesity and timing of imaging. Comparative studies that also evaluate emerging imaging approaches — including contrast-enhanced ultrasonography and advanced MRI techniques — could further elucidate optimal diagnostic pathways for acute pancreatitis (21,22). Additionally, cost-effectiveness analyses and integration of imaging with clinical scoring systems may help refine diagnostic algorithms that balance accuracy, resource use, and patient outcomes.

CONCLUSION

The study concluded that ultrasonography demonstrated high sensitivity, specificity, and overall diagnostic accuracy in detecting acute pancreatitis when compared with contrast-enhanced computed tomography, confirming its reliability as an initial imaging modality. Given its accessibility, safety, and cost-effectiveness, ultrasound can serve as a valuable first-line diagnostic tool, particularly in resource-limited or emergency settings. However, CT remains essential for definitive evaluation and complication assessment. Integrating both modalities in a tiered diagnostic approach can enhance early diagnosis, optimize patient management, and improve clinical outcomes in acute pancreatitis.

AUTHOR CONTRIBUTIONS

Author	Contribution
Iqra Sardar	Substantial Contribution to study design, analysis, acquisition of Data Manuscript Writing Has given Final Approval of the version to be published
Hina Gul*	Substantial Contribution to study design, acquisition and interpretation of Data Critical Review and Manuscript Writing Has given Final Approval of the version to be published
Muhammad Khadim	Substantial Contribution to acquisition and interpretation of Data Has given Final Approval of the version to be published
Ayesha Begum	Contributed to Data Collection and Analysis Has given Final Approval of the version to be published
Raina Gul	Contributed to Data Collection and Analysis Has given Final Approval of the version to be published

© 2025 et al. Open access under CC BY License (Creative Commons). Freely distributable with appropriate citation.

REFERENCES

1. Boraschi P, Giugliano L, Mercogliano G, Donati F, Romano S, Neri E. Abdominal and gastrointestinal manifestations in COVID-19 patients: Is imaging useful? World J Gastroenterol. 2021;27(26):4143-59.

2. Artunduaga M, Grover AS, Callahan MJ. Acute pancreatitis in children: a review with clinical perspectives to enhance imaging interpretation. Pediatr Radiol. 2021;51(11):1970-82.

3. Hu JX, Zhao CF, Wang SL, Tu XY, Huang WB, Chen JN, et al. Acute pancreatitis: A review of diagnosis, severity prediction and prognosis assessment from imaging technology, scoring system and artificial intelligence. World J Gastroenterol. 2023;29(37):5268-91.

4. Formanchuk T. Acute Pancreatitis: Radiological Detection and Clinical Significance of Pancreatic Ascites, Pleural and Parapancreatic Fluid Effusions. Prague Med Rep. 2024;125(4):309-23.

5. Whitcomb DC, Buchner AM, Forsmark CE. AGA Clinical Practice Update on the Epidemiology, Evaluation, and Management of Exocrine Pancreatic Insufficiency: Expert Review. Gastroenterology. 2023;165(5):1292-301.

6. Mukai S, Takeyama Y, Itoi T, Ikeura T, Irisawa A, Iwasaki E, et al. Clinical Practice Guidelines for post-ERCP pancreatitis 2023. Dig Endosc. 2025;37(6):573-87.

7. von Stade L, Rao S, Marolf AJ. Computed tomographic evaluation of pancreatic perfusion in 10 dogs with acute pancreatitis. Vet Radiol Ultrasound. 2023;64(5):823-33.

8. Mittal N, Oza VM, Muniraj T, Kothari TH. Diagnosis and Management of Acute Pancreatitis. Diagnostics (Basel). 2025;15(3).

9. Mejri A, Arfaoui K, Omri A, Rchidi J, Mseddi MA, Saad S. Gallbladder adenomyomatosis: Diagnosis and management. Int J Surg Case Rep. 2021;84:106089.

10. Aghdassi AA, Seidensticker M. [Imaging diagnostics in acute pancreatitis]. Internist (Berl). 2021;62(10):1044-54.

11. Pavlidis ET, Psarras K, Symeonidis NG, Geropoulos G, Pavlidis TE. Indications for the surgical management of pancreatic trauma: An update. World J Gastrointest Surg. 2022;14(6):538-43.

12. López Morales P, Ruiz Marín M, Albarracín Marín-Blázquez A. Lumen-apposing metal stent deployment failure. Rev Esp Enferm Dig. 2021;113(3):224-5.

13. Evola G, Vacante M, Evola FR, Reina GA, Maugeri G, Musumeci G, et al. An Overview of Acute Pancreatitis: Role of the Prediction Scores for the Assessment of Severity. Chirurgia (Bucur). 2025;120(3):314-21.

14. Wang Y, Liu K, Xie X, Song B. Potential role of imaging for assessing acute pancreatitis-induced acute kidney injury. Br J Radiol. 2021;94(1118):20200802.

15. Bikkumalla S, Chandak SR, Reddy S, Ram Sohan P, Hatewar A. Radiological and Biochemical Parameters in Assessing Acute Pancreatitis Severity: A Comprehensive Review. Cureus. 2024;16(6):e62288.

16. Lohse MR, Ullah K, Seda J, Thode HC, Jr., Singer AJ, Morley EJ. The role of emergency department computed tomography in early acute pancreatitis. Am J Emerg Med. 2021;48:92-5.

17. Singh A, Aggarwal M, Garg R, Walsh M, Stevens T, Chahal P. Spontaneous Internal Pancreatic Fistulae Complicating Acute Pancreatitis. Am J Gastroenterol. 2021;116(7):1381-6.

18. Iannuzzi JP, King JA, Leong JH, Quan J, Windsor JW, Tanyingoh D, et al. Global incidence of acute pancreatitis is increasing over time. Gastroenterology. 2022;162(1):122-34.

19. Barreto SG, Habtezion A, Gukovskaya A, Lugea A, Jeon C, Yadav D, et al. Critical thresholds: key to unlocking the door to the prevention and specific treatments for acute pancreatitis. Gut. 2021;70(1):194-203.

20. Mederos MA, Reber HA, Girgis MD. Acute pancreatitis: a review. J Am Med Assoc. 2021;325(4):382-90.

© 2025 et al. Open access under CC BY License (Creative Commons). Freely distributable with appropriate citation.

21. Brizi MG, Perillo F, Cannone F, Tuzza L, Manfredi R. The role of imaging in acute pancreatitis. Radiol Med. 2021;126(8):1017-29

22. Irum R, Yousaf M. Diagnostic Accuracy of Ultrasonography in Diagnosing Acute Pancreatitis, Taking Computed Tomography as Gold Standard. J Sharif Med Dent Coll. 2021;7(1):30-6.

© 2025 et al. Open access under CC BY License (Creative Commons). Freely distributable with appropriate citation.