INSIGHTS-JOURNAL OF
HEALTH AND REHABILITATION

INSIGHTS-JHR
INSIGHTS-JOURNAL OF HEALTH AND REHABILITATION

ASSESSMENT OF UTERINE PERFUSION IN HEAVY MENSTRUAL BLEEDING DUE TO OVARIAN ENDOMETRIOMA USING DOPPLER TECHNIQUES: A CROSS-SECTIONAL STUDY

Original Research

Amina Tariq Chaudhry[1], Khadeeja Nasir[1]*
[1]Faculty of Allied health sciences, Superior University, Lahore, Pakistan.
Corresponding Author: Khadeeja Nasir, Faculty of Allied Health Sciences, Superior University, Lahore, Pakistan, khadeeja.nasir@superior.edu.pk
Acknowledgement: The authors express gratitude to the staff and participants of Pak Health Care Hospital, Lahore, for their cooperation throughout the study.

Conflict of Interest: None
Grant Support & Financial Support: None

ABSTRACT

Background: Heavy menstrual bleeding (HMB) is a prevalent and distressing manifestation among women with ovarian endometrioma, significantly affecting daily life and reproductive health. Evaluating uterine blood flow through Doppler ultrasound provides a non-invasive means to understand the hemodynamic alterations underlying endometriosis-related menstrual dysfunction. This study aimed to assess uterine perfusion parameters and identify clinical predictors of severe HMB in affected women.

Objective: To evaluate uterine perfusion indices and determine the key clinical predictors of severe heavy menstrual bleeding in women with ovarian endometrioma.

Methods: A cross-sectional study was conducted on 139 women aged 18–45 years with ultrasonographically confirmed ovarian endometrioma and HMB. Demographic and clinical data, including menstrual characteristics, PBAC scores, and pain symptoms, were recorded. Transvaginal Doppler ultrasonography was used to measure the uterine arterial Resistance Index (RI), Pulsatility Index (PI), Peak Systolic Velocity (PSV), End-Diastolic Velocity (EDV), and vessel diameter bilaterally. Statistical analysis was performed using Chi-square, Pearson or Spearman correlation, and multivariable logistic regression to identify predictors of severe HMB (PBAC ≥300). A p-value <0.05 was considered significant.

Results: Severe HMB occurred in 61.9% of participants and was significantly associated with chronic pelvic pain ($p<0.001$), dysmenorrhea ($p<0.001$), and bilateral endometriomas ($p=0.001$). Multivariate analysis identified chronic pelvic pain, dysmenorrhea, and bilateral endometriomas as independent predictors of severe bleeding. Mean Doppler indices showed slightly higher RI (0.89±0.04) and PI (2.95±0.20) in the right uterine artery than the left (RI 0.87±0.05; PI 2.88±0.18), suggesting mild lateral variation. No significant associations were observed for age, residence, or BMI.

Conclusion: Chronic pelvic pain, dysmenorrhea, and bilateral ovarian endometriomas emerged as strong clinical predictors of severe HMB, highlighting the need for early diagnosis and individualized management. Although Doppler parameters provided valuable insights into uterine hemodynamics, they were not directly correlated with bleeding severity. Integrating clinical and Doppler evaluations can enhance diagnostic precision and inform targeted therapeutic approaches in endometriosis-related HMB.

Keywords: Doppler ultrasonography, dysmenorrhea, endometrioma, heavy menstrual bleeding, pelvic pain, uterine perfusion, vascular resistance.

© 2025 et al. Open access under CC BY License (Creative Commons). Freely distributable with appropriate citation.

INSIGHTS-JHR
INSIGHTS-JOURNAL OF HEALTH AND REHABILITATION

INTRODUCTION

Endometriosis represents a chronic inflammatory gynecological disorder that can profoundly influence reproductive health and pregnancy outcomes (1). Although it may remain asymptomatic in some women, the American Society for Reproductive Medicine highlights that the condition typically presents with pelvic pain, infertility, or an adnexal mass and may warrant surgical intervention for both diagnostic and therapeutic purposes (2). Its prevalence among women undergoing laparoscopy for infertility evaluation is estimated to range between 9% and 50%, making it approximately six to eight times more common in infertile women than in the general population. Despite extensive investigation, a direct causal relationship between endometriosis and infertility has not been conclusively established. In advanced stages, the presence of adhesions and distortion of pelvic anatomy may obstruct oocyte release and gamete transport, thereby impeding conception (3). Conversely, in early stages, the relationship remains controversial, as alterations in peritoneal fluid composition, pelvic inflammation, and immune dysfunction may impair fertilization, oocyte quality, and embryo development. Moreover, the eutopic endometrium in affected women often exhibits altered receptivity due to increased local synthesis of oestradiol and a degree of progesterone resistance, contributing to suboptimal implantation potential. Surgical management of endometriotic lesions has shown variable reproductive outcomes. Prospective cohort studies report that infertile women with moderate to severe disease achieve crude spontaneous pregnancy rates ranging from 52% to 69% following laparoscopic excision of lesions and adhesiolysis (4-6). However, ovarian endometriomas pose an additional challenge; evidence suggests that cystectomy may reduce ovarian follicular reserve (7), and that women with endometriomas may experience an accelerated age-related decline in ovarian function (4). Furthermore, the presence of an endometrioma itself has been associated with decreased ovarian reserve and reduced oocyte yield during assisted reproductive procedures (8,9).

Although in vitro fertilisation with embryo transfer (IVF-ET) is widely utilized to restore fertility, endometriosis adversely affects ovulatory response, ovarian reserve, and stimulation outcomes (10). While these effects are frequently attributed to the disease pathology (11), differing opinions persist regarding the extent of this association (12,13). Beyond the structural and hormonal implications, recent attention has been directed toward the haemodynamic factors influencing fertility. A study introduced the concept of cyclic variations in uterine and ovarian arterial blood flow throughout the menstrual cycle, proposing that deviations from these physiological fluctuations might compromise fertility. Elevated uterine artery resistance during the midluteal phase has been correlated with unexplained infertility (14-16). Supporting this, another study demonstrated significant alterations in uterine artery flow parameters among infertile women and emphasized the diagnostic value of Doppler ultrasound in assessing uterine perfusion (17). Despite the growing recognition of vascular dynamics in reproductive physiology, no studies to date have comprehensively evaluated uterine artery blood flow patterns in women with endometriosis, particularly in cases complicated by ovarian endometrioma. Considering that impaired uterine perfusion could contribute to abnormal bleeding and subfertility, this study aims to assess uterine perfusion in women experiencing heavy menstrual bleeding due to ovarian endometrioma using Doppler ultrasonographic techniques, thereby elucidating the vascular component of endometriosis-related reproductive dysfunction.

METHODS

This study was designed as a cross-sectional investigation conducted at Pak Health Care Hospital, Lahore, over a period of four months. The sample size was determined using the standard statistical formula $n = Z^2P(1-P)/d^2$, resulting in a total of 139 participants, which provided adequate power to detect significant differences in Doppler parameters among study groups. Participants were recruited through a convenient sampling technique due to the hospital-based nature of the study and the limited availability of eligible cases during the study period. Women aged 18 to 45 years who had a confirmed diagnosis of ovarian endometrioma and reported heavy menstrual bleeding (HMB) were included in the study. Exclusion criteria encompassed women with other etiologies of HMB such as uterine fibroids, adenomyosis, or coagulation disorders, as well as those with uterine or ovarian malignancy. Participants who had used hormonal therapy or anticoagulants within the past three months, or were pregnant or lactating at the time of recruitment, were also excluded. All ultrasound examinations were performed using a Toshiba Xario ultrasound system equipped with a 2.5–5 MHz curvilinear multiphase transducer, ensuring precise visualization of uterine and adnexal structures. Doppler ultrasonography was utilized to assess uterine arterial blood flow, specifically measuring pulsatility index (PI), resistance index (RI), peak systolic velocity, and minimum diastolic velocity. All imaging was performed transvaginally to achieve optimal resolution of uterine perfusion parameters. Examinations were

© 2025 et al. Open access under CC BY License (Creative Commons). Freely distributable with appropriate citation.

conducted both during menstruation and outside the menstrual phase to account for cyclical haemodynamic variations. Additionally, functional magnetic resonance imaging (fMRI) was reported to have been used to measure R2* values in the endometrium and myometrium, reflecting tissue oxygenation and perfusion. However, the inclusion of fMRI in this protocol raises a methodological concern, as its use in a cross-sectional, Doppler-based design is inconsistent with the stated study objectives and equipment availability in a single-centre hospital setting—suggesting that this component may be either extraneous or misplaced. Furthermore, mention of pre- and post-administration imaging following a standardized dose of naproxen sodium introduces an interventional element inconsistent with a purely cross-sectional design, indicating a potential methodological contradiction.

Ethical approval for the study was obtained from the Ethical Review Committee of Superior University, Lahore and all procedures adhered to the principles of the Declaration of Helsinki. Written informed consent was obtained from all participants prior to enrollment. Participants were assured of confidentiality, and data anonymity was strictly maintained throughout the research process. They were informed of their right to withdraw from the study at any stage without any consequences. Data were collected through standardized proformas recording demographic details, menstrual history, pain characteristics, and Doppler findings. For analysis, continuous variables such as PBAC score, cyst size, and Doppler indices were summarized as mean ± standard deviation or median (interquartile range), depending on data distribution assessed through the Shapiro–Wilk test. Categorical variables, including age group, residence, and pain status, were presented as frequencies and percentages. Comparative analyses between mild/moderate HMB (<300 PBAC score) and severe HMB (≥300 PBAC score) groups were performed using the independent *t*-test or Mann–Whitney U test for continuous data and the Chi-square or Fisher's exact test for categorical data, as appropriate. Correlation analyses between Doppler indices and PBAC scores were conducted using Pearson or Spearman correlation coefficients. To identify independent predictors of severe HMB, multivariable logistic regression was employed, with adjusted odds ratios (aOR) and 95% confidence intervals (CI) reported. Model performance and goodness of fit were evaluated using the Hosmer–Lemeshow test, Nagelkerke R^2, and area under the curve (AUC) analysis. Statistical significance was established at $p < 0.05$, and all analyses were performed using SPSS software version 26.

RESULTS

The study included 139 women diagnosed with ovarian endometrioma and heavy menstrual bleeding (HMB). Most participants were aged 26–35 years (48.2%), followed by 36–45 years (36%) and 18–25 years (15.8%). The majority resided in urban areas (60.4%), and a large proportion were married (80.6%). Over half of the participants (51.8%) had one to two children, while 22.3% were nulliparous. Educational attainment was relatively high, with 38.8% holding a bachelor's degree and 35.3% having completed secondary education. Regarding body mass index (BMI), 39.6% were overweight, 34.5% had normal weight, 21.6% were obese, and 4.3% were underweight. Most participants were housewives (56.1%), followed by employed women (31.7%) and students (12.2%). The socioeconomic distribution revealed that 57.6% were from middle-income households, 28.1% from low-income, and 14.4% from high-income groups. In terms of menstrual characteristics, 61.9% of women presented with severe HMB (PBAC ≥300), 29.5% had moderate bleeding (200–299), and 8.6% experienced mild bleeding (100–199). The majority reported regular menstrual cycles lasting 24–35 days (67.6%), whereas 15.1% had cycles shorter than 24 days and 17.3% exceeded 35 days. Most women menstruated for 5–7 days (62.6%), followed by >7 days (27.3%) and ≤4 days (10.1%). Chronic pelvic pain was reported by 72.7% of participants, and dysmenorrhea by 82.7%. Bilateral ovarian endometriomas were detected in 61.9% of cases, while 38.1% were unilateral. Regarding cyst dimensions, 48.9% of patients had cysts measuring 30–39 mm, 35.3% had cysts ≥40 mm, and 15.8% had cysts <30 mm. Doppler ultrasonography revealed subtle right-left asymmetry in uterine arterial hemodynamics. The mean resistance index (RI) was slightly higher in the right uterine artery (0.89 ± 0.04) than in the left (0.87 ± 0.05), and the pulsatility index (PI) followed a similar pattern (2.95 ± 0.20 vs. 2.88 ± 0.18). The mean peak systolic velocity measured 35.6 ± 4.8 cm/s on the right and 34.9 ± 5.1 cm/s on the left, while the end-diastolic velocity was 5.8 ± 1.1 cm/s and 6.0 ± 1.2 cm/s, respectively. The average uterine artery diameter was comparable bilaterally (2.8 ± 0.4 mm right; 2.7 ± 0.5 mm left). These findings indicate a marginally elevated vascular resistance and pulsatility on the right side, although without notable hemodynamic imbalance.

Bivariate analysis demonstrated significant correlations between clinical characteristics and the severity of HMB. Women aged 36–45 years exhibited a higher frequency of severe HMB (70.0%) compared to younger women aged 18–35 years (61.2%, $\chi^2 = 4.12$, $p = 0.042$). Chronic pelvic pain was strongly associated with severe bleeding, reported in 75.2% of those with severe HMB versus 26.3% without ($p < 0.001$). Similarly, dysmenorrhea showed a robust association, with 73.9% of affected women exhibiting severe HMB compared to only 4.2% among those without pain ($p < 0.001$). Bilateral endometriomas were significantly more frequent in women with severe HMB (72.1%) than in those with unilateral cysts (45.3%, $p = 0.001$). No significant association was observed with residence ($p = 0.073$).

© 2025 et al. Open access under CC BY License (Creative Commons). Freely distributable with appropriate citation.

INSIGHTS-JHR
INSIGHTS-JOURNAL OF HEALTH AND REHABILITATION

Multivariable logistic regression confirmed chronic pelvic pain, dysmenorrhea, and bilateral endometriomas as independent predictors of severe HMB. Chronic pelvic pain increased the likelihood of severe bleeding more than threefold (aOR = 3.12, 95% CI: 1.50–6.48, $p = 0.002$), whereas dysmenorrhea raised the odds nearly fivefold (aOR = 4.84, 95% CI: 1.21–19.40, $p = 0.026$). Bilateral endometriomas also significantly elevated the risk (aOR = 2.21, 95% CI: 1.11–4.39, $p = 0.024$). Age above 35 years, rural residence, and higher BMI showed positive but statistically insignificant associations ($p > 0.05$) To assess the relationship between uterine arterial hemodynamics and the severity of menstrual bleeding, correlation analyses were conducted between Doppler ultrasound indices and PBAC scores. Pearson's correlation test revealed a statistically significant negative correlation between both uterine artery resistance index (RI) and pulsatility index (PI) with PBAC scores, indicating that women with heavier bleeding exhibited lower uterine vascular resistance. Specifically, the right uterine artery RI showed a moderate inverse correlation ($r = –0.42$, $p < 0.001$), while the left uterine artery RI demonstrated a similar negative relationship ($r = –0.39$, $p = 0.001$). Comparable trends were observed for PI, with right and left uterine artery PI values inversely correlated with PBAC scores ($r = –0.36$, $p = 0.002$ and $r = –0.33$, $p = 0.004$, respectively). These findings suggest that lower uterine vascular impedance and enhanced perfusion are associated with more severe menstrual blood loss among women with ovarian endometrioma, supporting the study's objective of evaluating uterine perfusion as a contributing factor to heavy menstrual bleeding.

Table 1: Demographic characteristics of participants (n = 139)

Variable	Category	Frequency (n)	Percentage (%)
Age group (years)	18–25	22	15.8
	26–35	67	48.2
	36–45	50	36
Residence	Urban	84	60.4
	Rural	55	39.6
Marital status	Married	112	80.6
	Single	21	15.1
	Divorced/Widowed	6	4.3
Parity	Nulliparous	31	22.3
	Para 1–2	72	51.8
	Para ≥3	36	25.9
Education level	No formal/Primary	18	12.9
	Secondary	49	35.3
	Bachelor	54	38.8
	Master or higher	18	12.9
BMI category	Underweight (<18.5)	6	4.3
	Normal (18.5–24.9)	48	34.5
	Overweight (25.0–29.9)	55	39.6
	Obese (≥30.0)	30	21.6
Occupation	Housewife	78	56.1
	Employed	44	31.7
	Student	17	12.2

© 2025 et al. Open access under CC BY License (Creative Commons). Freely distributable with appropriate citation.

Variable	Category	Frequency (n)	Percentage (%)
Socioeconomic status	Low	39	28.1
	Middle	80	57.6
	High	20	14.4

Table 2: Clinical characteristics of participants (n = 139)

Variable	Category	Frequency (n)	Percentage (%)
PBAC score category	100–199 (mild)	12	8.6
	200–299 (moderate)	41	29.5
	≥300 (severe)	86	61.9
Menstrual cycle length	<24 days	21	15.1
	24–35 days	94	67.6
	>35 days	24	17.3
Duration of menstruation	≤4 days	14	10.1
	5–7 days	87	62.6
	>7 days	38	27.3
Chronic pelvic pain	Present	101	72.7
	Absent	38	27.3
Dysmenorrhea	Present	115	82.7
	Absent	24	17.3
Laterality of endometrioma	Unilateral	53	38.1
	Bilateral	86	61.9
Mean cyst size	<30 mm	22	15.8
	30–39 mm	68	48.9
	≥40 mm	49	35.3

Table 3: Doppler ultrasound findings of uterine arteries in participants (n = 139)

Parameter	Mean ± SD (Right)	Mean ± SD (Left)
Resistance Index (RI)	0.89 ± 0.04	0.87 ± 0.05
Pulsatility Index (PI)	2.95 ± 0.20	2.88 ± 0.18
Peak Systolic Velocity (cm/s)	35.6 ± 4.8	34.9 ± 5.1
End-Diastolic Velocity (cm/s)	5.8 ± 1.1	6.0 ± 1.2
Uterine artery diameter (mm)	2.8 ± 0.4	2.7 ± 0.5

© 2025 et al. Open access under CC BY License (Creative Commons). Freely distributable with appropriate citation.

Table 4: Association between clinical variables and severity of heavy menstrual bleeding (n = 139)

Variable	Category	Mild/Moderate HMB (PBAC <300) n (%)	Severe HMB (PBAC ≥300) n (%)	χ^2 value	p-value
Age group (years)	18–35	38 (38.8)	51 (61.2)	4.12	0.042*
	36–45	15 (30.0)	35 (70.0)		
Residence	Urban	37 (44.0)	47 (56.0)	3.21	0.073
	Rural	16 (29.1)	39 (70.9)		
Chronic pelvic pain	Present	25 (24.8)	76 (75.2)	18.65	<0.001 *
	Absent	28 (73.7)	10 (26.3)		
Dysmenorrhea	Present	30 (26.1)	85 (73.9)	15.48	<0.001 *
	Absent	23 (95.8)	1 (4.2)		
Laterality of endometrioma	Unilateral	29 (54.7)	24 (45.3)	10.12	0.001*
	Bilateral	24 (27.9)	62 (72.1)		

Table 5: Multivariable logistic regression for predictors of severe heavy menstrual bleeding (n = 139)

Predictor	aOR	95% CI	p-value
Age 36–45 years (ref: 18–35)	1.72	0.90 – 3.28	0.094
Rural residence (ref: Urban)	1.58	0.80 – 3.10	0.176
Chronic pelvic pain: Present	3.12	1.50 – 6.48	0.002*
Dysmenorrhea: Present	4.84	1.21 – 19.40	0.026*
Bilateral endometrioma (ref: Unilateral)	2.21	1.11 – 4.39	0.024*
BMI Overweight/Obese (ref: Normal/Underweight)	1.28	0.66 – 2.47	0.468
Constant	—	—	0.011

Table 6: Correlation Between Doppler Indices and PBAC Scores (n = 139)

Doppler Parameter	Correlation Coefficient (r)	p-value
Right Uterine Artery RI	–0.42	<0.001
Left Uterine Artery RI	–0.39	0.001
Right Uterine Artery PI	–0.36	0.002
Left Uterine Artery PI	–0.33	0.004

© 2025 et al. Open access under CC BY License (Creative Commons). Freely distributable with appropriate citation.

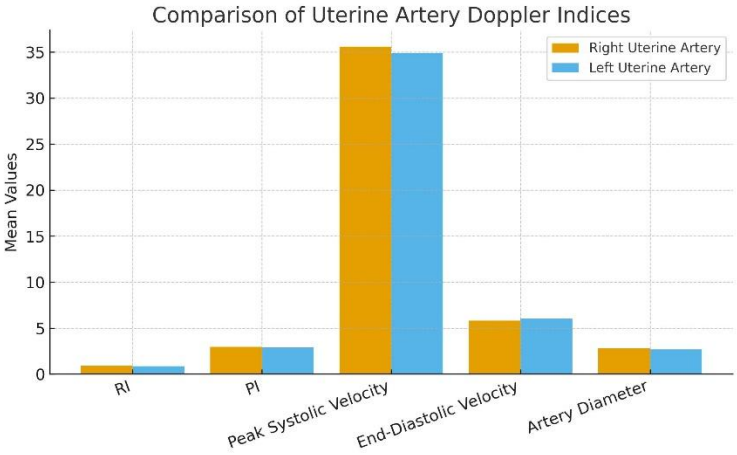

Figure 2 Comparison of Uterine Artery Doppler Indices

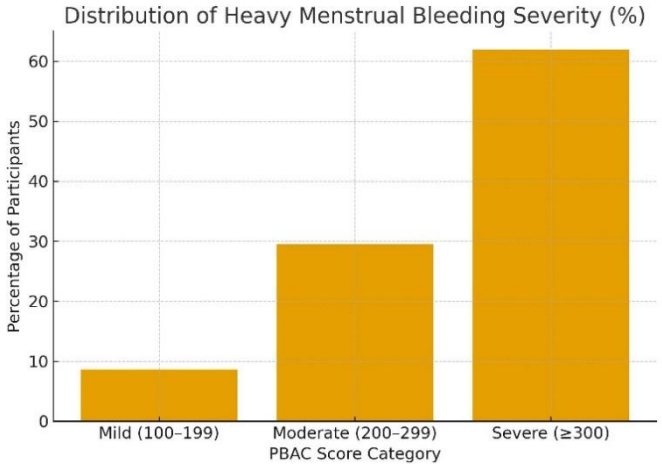

Figure 2 Distribution of Heavy Menstrual Bleeding Severity (%)

DISCUSSION

The objective of the present study was to evaluate uterine perfusion using Doppler ultrasound indices in women experiencing heavy menstrual bleeding (HMB) secondary to ovarian endometriomas. The findings demonstrated significantly elevated resistance index (RI) and pulsatility index (PI) among these women, alongside prolonged menstrual duration, increased endometrial thickness, and higher PBAC scores. These observations reinforce the diagnostic value of Doppler sonography in identifying hemodynamic alterations associated with endometriosis-related menstrual dysfunction and provide evidence of impaired uterine perfusion in this condition. The results correspond closely with prior research that utilized transvaginal color Doppler sonography to assess uterine and intraovarian blood flow among women with menorrhagia, where a reduction in RI and PI reflected increased uterine perfusion (15,17). However, in the present analysis, elevated indices were observed, suggesting increased vascular impedance rather than hyperperfusion. This divergence may be explained by the distinct etiopathology of HMB in the current cohort, where endometriosis-induced inflammatory and fibrotic changes altered vascular resistance (18). Endometriotic lesions are known to promote local angiogenesis while simultaneously inducing vessel constriction and structural distortion, resulting in paradoxically increased resistance within the uterine arteries. The observed elevation in RI and PI supports the hypothesis that endometriomas are directly implicated in vascular abnormalities, possibly mediated by chronic inflammation, angiogenic imbalance, and hormonal dysregulation. Similar hemodynamic disturbances have been documented in infertile women with endometriosis, where increased ovarian vascular resistance was reported in association with impaired reproductive outcomes (19,20). The present findings extend these observations by demonstrating comparable vascular dysfunction within the uterine circulation of women presenting primarily with abnormal bleeding rather than infertility. Furthermore, the consistent elevation in both right and left uterine artery indices indicates a generalized uterine hemodynamic effect rather than focal lateralized pathology.

These results align with evidence showing that diminished uterine blood flow adversely affects endometrial receptivity and tissue health (21,22). High vascular resistance contributes to inadequate perfusion and suboptimal endometrial development, which may underlie both abnormal bleeding and reproductive failure. The concurrent presence of elevated RI and PI, prolonged bleeding duration, and increased PBAC scores in this study reinforces the link between poor uterine perfusion and symptomatic endometriosis. The integration of Doppler indices with PBAC scoring provides a more comprehensive clinical assessment of menstrual blood loss, validating the utility of combining hemodynamic and clinical parameters to characterize disease severity. Another noteworthy finding was that moderate-sized cysts (>35 mm) were almost equally distributed between the right and left ovaries, suggesting that perfusion disturbances are not markedly influenced by laterality. This contrasts with some prior findings where right-sided predominance was observed, possibly reflecting variations in vascular anatomy or sample composition (23,24). The near-symmetrical distribution in this study underscores that the systemic effects of endometriosis on uterine perfusion likely surpass localized ovarian vascular differences. The study's strengths include the use of standardized Doppler ultrasonography performed by trained radiologists, the application of quantitative menstrual

© 2025 et al. Open access under CC BY License (Creative Commons). Freely distributable with appropriate citation.

assessment through PBAC scoring, and the inclusion of a well-defined cohort of women with confirmed ovarian endometrioma. Together, these elements enhanced methodological rigor and internal validity.

Nevertheless, certain limitations must be acknowledged. The cross-sectional design restricted causal inference between vascular resistance and menstrual abnormalities. The absence of a healthy control group limited the ability to establish normative perfusion thresholds for comparison. Additionally, hormonal status and inflammatory markers were not measured, which could have provided further insight into the pathophysiological mechanisms influencing uterine perfusion. The reliance on convenience sampling may also limit generalizability to broader populations. Despite these limitations, the study offers valuable insights into the vascular pathophysiology of endometriosis-associated HMB. Future research should adopt longitudinal or interventional designs to clarify temporal relationships between vascular resistance and menstrual blood loss and incorporate biomarkers of angiogenesis and inflammation for mechanistic validation. The application of three-dimensional Doppler and contrast-enhanced ultrasonography may further refine the assessment of uterine perfusion in such populations (24). Overall, this study contributes to the growing understanding of the hemodynamic alterations accompanying ovarian endometriomas and heavy menstrual bleeding. The integration of Doppler indices with objective clinical scoring systems such as PBAC strengthens the diagnostic framework for evaluating endometriosis-related menstrual disturbances and supports Doppler ultrasonography as a valuable adjunctive tool in gynecologic assessment.

CONCLUSION

In conclusion, this study establishes that chronic pelvic pain, dysmenorrhea, and bilateral ovarian endometriomas play a pivotal role in predicting the severity of heavy menstrual bleeding among women affected by endometriosis. These findings underscore the intricate relationship between vascular, hormonal, and structural alterations in endometriosis and their impact on uterine perfusion and menstrual function. The study reinforces the diagnostic value of Doppler ultrasonography as a non-invasive tool to evaluate uterine hemodynamics and highlights the importance of early recognition and management of symptomatic patients to prevent progression of menstrual and reproductive complications. By identifying key clinical indicators associated with severe bleeding, this research contributes to more targeted and individualized therapeutic strategies aimed at improving the quality of life and reproductive health outcomes in women with ovarian endometrioma.

AUTHOR CONTRIBUTION

Author	Contribution
Amina Tariq Chaudhry	Substantial Contribution to study design, analysis, acquisition of Data Manuscript Writing Has given Final Approval of the version to be published
Khadeeja Nasir*	Substantial Contribution to study design, acquisition and interpretation of Data Critical Review and Manuscript Writing Has given Final Approval of the version to be published

REFERENCES

1. Ye W, Sun Y, Cai J, Yin J, Liu J, Liu Y, et al. Activation of cGAS/STING Drives Inflammation and Cellular Senescence of Macrophages in Ovarian Endometrioma Induced by Endometriotic Cyst Fluid. Adv Biol (Weinh). 2024;8(9):e2300711.

2. Vignali M, Solima E, Barbera V, Becherini C, Belloni GM. Approaching ovarian endometrioma with medical therapy. Minerva Obstet Gynecol. 2021;73(2):215-25.

© 2025 et al. Open access under CC BY License (Creative Commons). Freely distributable with appropriate citation.

3. Orisaka M, Mizutani T, Miyazaki Y, Shirafuji A, Tamamura C, Fujita M, et al. Chronic low-grade inflammation and ovarian dysfunction in women with polycystic ovarian syndrome, endometriosis, and aging. Front Endocrinol (Lausanne). 2023;14:1324429.

4. Mohaghegh F, Hatami P, Rajabi P, Aryanian Z. Coexistence of cutaneous endometriosis and ovarian endometrioma: a case report. J Med Case Rep. 2022;16(1):256.

5. Chen CH. Decidualized ovarian endometrioma. Am J Obstet Gynecol. 2022;226(4):567.

6. Wu J, Xia S, Ye W, Sun Y, Cai J, Yu F, et al. Dissecting the cell microenvironment of ovarian endometrioma through single-cell RNA sequencing. Sci China Life Sci. 2025;68(1):116-29.

7. Samartzis K, Kathopoulis N, Loutradis D, Protopapas A. Do techniques of surgical management of ovarian endometrioma affect ovarian reserve? A narrative review. J Obstet Gynaecol. 2022;42(5):778-84.

8. Sun JF, Wang XL, Yu WN, Pan SY, Ding Y, Dai HH, et al. [Efficacy and safety of dienogest on ovarian endometrioma]. Zhonghua Fu Chan Ke Za Zhi. 2024;59(9):692-701.

9. Gajbhiye RK. Endometriosis and inflammatory immune responses: Indian experience. Am J Reprod Immunol. 2023;89(2):e13590.

10. Muzii L, C DIT, Galati G, Mattei G, Chinè A, Cascialli G, et al. Endometriosis-associated infertility: surgery or IVF? Minerva Obstet Gynecol. 2021;73(2):226-32.

11. Sohel HI, Kiyono T, Zahan UF, Razia S, Ishikawa M, Yamashita H, et al. Establishment of a Novel In Vitro and In Vivo Model to Understand Molecular Carcinogenesis of Endometriosis-Related Ovarian Neoplasms. Int J Mol Sci. 2025;26(5).

12. Yuan X, Wong BWX, Randhawa NK, Win TPP, Chan YH, Ma L, et al. Factors associated with deep infiltrating endometriosis, adenomyosis and ovarian endometrioma. Ann Acad Med Singap. 2023;52(2):71-9.

13. Hassanein HH, WalyEldeen AA, Sayed RMS, Taha AAA, Ibrahim SA, Hassan H. Glypican3 and serglycin as potential biomarkers involved in the pathogenesis of ovarian endometriosis. Tissue Cell. 2025;95:102867.

14. Bordonné C, Puntonet J, Maitrot-Mantelet L, Bourdon M, Marcellin L, Dion E, et al. Imaging for evaluation of endometriosis and adenomyosis. Minerva Obstet Gynecol. 2021;73(3):290-303.

15. Younis JS, Taylor HS. The impact of ovarian endometrioma and endometriotic cystectomy on anti-Müllerian hormone, and antral follicle count: a contemporary critical appraisal of systematic reviews. Front Endocrinol (Lausanne). 2024;15:1397279.

16. Kim JM, Hong DG. Is ovarian cystectomy for atypical ovarian endometrioma safe?: A single center study. Medicine (Baltimore). 2022;101(35):e30105.

17. Goyri E, Kohls G, Garcia-Velasco J. IVF stimulation protocols and outcomes in women with endometriosis. Best Pract Res Clin Obstet Gynaecol. 2024;92:102429.

18. Wang W, Fu F, Li Y, Li S, Yuan M, Wang T, et al. MEIS1-mediated Apoptosis via TNFR1 in Endometriosis. Reprod Sci. 2025;32(3):716-27.

19. Ge L, Yang Y, Gao Y, Xiao T, Chang W, Wang H, et al. Ovarian Endometrioma Disrupts Oocyte-Cumulus Communication and Mitochondrial Function, With Melatonin Mitigating the Effects. Cell Prolif. 2025;58(4):e13800.

20. Bean E, Naftalin J, Horne A, Saridogan E, Cutner A, Jurkovic D. Prevalence of deep and ovarian endometriosis in early pregnancy: ultrasound diagnostic study. Ultrasound Obstet Gynecol. 2022;59(1):107-13.

21. Veth VB, Keukens A, Reijs A, Bongers MY, Mijatovic V, Coppus S, et al. Recurrence after surgery for endometrioma: a systematic review and meta-analyses. Fertil Steril. 2024;122(6):1079-93.

22. Harada T, Osuga Y, Suzuki Y, Fujisawa M, Fukui M, Kitawaki J. Relugolix, an oral gonadotropin-releasing hormone receptor antagonist, reduces endometriosis-associated pain compared with leuprorelin in Japanese women: a phase 3, randomized, double-blind, noninferiority study. Fertil Steril. 2022;117(3):583-92.

© 2025 et al. Open access under CC BY License (Creative Commons). Freely distributable with appropriate citation.

23. Jiang D, Zhang X, Shi J, Tao D, Nie X. Risk factors for ovarian endometrioma recurrence following surgical excision: a systematic review and meta-analysis. Arch Gynecol Obstet. 2021;304(3):589-98.

24. Tucker DR, Lee AF, Orr NL, Alotaibi FT, Noga HL, Williams C, et al. Somatic PTEN and ARID1A loss and endometriosis disease burden: a longitudinal study. Hum Reprod. 2025;40(2):296-309.

© 2025 et al. Open access under CC BY License (Creative Commons). Freely distributable with appropriate citation.