INSIGHTS-JOURNAL OF
HEALTH AND REHABILITATION

INSIGHTS-JHR
INSIGHTS-JOURNAL OF HEALTH AND REHABILITATION

COMPARISON OF DIAGNOSTIC ACCURACY OF PREOPERATIVE TRANSABDOMINAL AND TRANSVAGINAL ULTRASONOGRAPHY FOR STAGING OF GYNECOLOGICAL TUMORS TAKING HISTOPATHOLOGY AS GOLD STANDARD

Original Research

Khansa Saleem[1], Aqsa Rao[1], Hafiza Zuha Bashir[1], Khadeeja Nasir[1]*
[1]Faculty of Allied health sciences, Superior University, Lahore, Pakistan.
Corresponding Author: Khadeeja Nasir, Faculty of Allied health sciences, Superior University, Lahore, Pakistan, khadeeja.nasir@superior.edu.pk
Acknowledgement: The authors sincerely acknowledge the support of the Department of Gynecology and Obstetrics, Shaukat Khanum Cancer Hospital, Lahore.

Conflict of Interest: None
Grant Support & Financial Support: None

ABSTRACT

Background: Accurate preoperative staging of gynecological malignancies is fundamental for determining optimal treatment and predicting prognosis. Ultrasonography, particularly transabdominal (TAUS) and transvaginal (TVUS) methods, provides a non-invasive and cost-effective diagnostic approach. However, comparative data on their diagnostic performance against histopathology remain limited, especially in resource-limited clinical settings where imaging accuracy directly influences surgical planning and patient outcomes.

Objective: To compare the diagnostic accuracy of TAUS and TVUS in the preoperative staging of gynecological malignancies, using histopathology as the gold standard.

Methods: This prospective cohort study included 70 women aged ≥18 years presenting with suspected gynecological tumors at a tertiary care cancer hospital. All participants underwent both TAUS and TVUS prior to surgical management. Standardized imaging protocols were applied, and staging was determined according to FIGO criteria. Histopathological examination of surgical specimens served as the reference standard. Data were analyzed using SPSS version 25.0. Diagnostic indices including sensitivity, specificity, positive predictive value (PPV), negative predictive value (NPV), and overall accuracy were calculated. Binary logistic regression was performed to identify independent imaging predictors of malignancy.

Results: The mean age of participants was 44.7 ± 11.3 years; 58.6% were postmenopausal, and 37.1% were multiparous. Histopathology confirmed malignancy in 45 cases (64.3%). TAUS demonstrated a sensitivity of 84.4%, specificity of 80.0%, PPV of 88.4%, NPV of 74.1%, and accuracy of 82.9%. TVUS showed higher diagnostic metrics—sensitivity 93.3%, specificity 88.0%, PPV 93.3%, NPV 88.0%, and accuracy 91.4%. TVUS also had fewer staging misclassifications across FIGO stages, particularly in Stage II and III diseases. Regression analysis identified TVUS as a stronger independent predictor of malignancy (OR = 8.17, p = 0.001) than TAUS (OR = 3.85, p = 0.020).

Conclusion: TVUS demonstrated superior diagnostic accuracy and staging precision compared to TAUS across all tumor types and disease stages. Its incorporation into preoperative evaluation protocols could enhance diagnostic reliability, reduce misclassification, and improve individualized surgical planning in gynecological oncology.

Keywords: Cohort Studies; Diagnostic Accuracy; Gynecologic Neoplasms; Histopathology; Preoperative Evaluation; Transabdominal Ultrasonography; Transvaginal Ultrasonography.

© 2025 et al. Open access under CC BY License (Creative Commons). Freely distributable with appropriate citation.

INTRODUCTION

Gynecological malignancies—including cancers of the endometrium, ovary, cervix, and uterus—remain a major contributor to morbidity and mortality among women worldwide, representing approximately 19% of all cancer diagnoses according to the World Health Organization (1–3). The global burden continues to rise, particularly in low- and middle-income countries where access to routine screening, early diagnostic services, and specialized oncologic care remains limited. In such settings, delayed diagnosis often results in advanced disease at presentation, complicating management and diminishing survival outcomes. Early and accurate identification of malignant pathology is therefore essential, as treatment planning, prognostication, and long-term survival are closely tied to both diagnostic precision and proper staging. Histopathology is universally regarded as the gold standard for confirming gynecological cancers and determining tumor stage; however, its application is restricted to postoperative specimens, making it unsuitable for preoperative planning (4,5). As clinicians increasingly seek reliable, non-invasive methods to guide initial decision-making, imaging modalities have become indispensable in gynecological oncology. Ultrasonography, in particular, is widely utilized due to its accessibility, affordability, real-time visualization, and absence of ionizing radiation, which make it especially valuable in resource-limited environments (6). Among available sonographic approaches, transabdominal ultrasonography (TAUS) and transvaginal ultrasonography (TVUS) are routinely used. TAUS provides a broad field of view that assists in evaluating large pelvic masses and extra-pelvic disease extension, though its accuracy can be influenced by patient-related factors such as obesity, bowel gas, and the need for optimal bladder filling (7,8). In contrast, TVUS offers superior resolution and proximity to pelvic organs, enabling clearer assessment of small lesions, endometrial thickness, myometrial invasion, and subtle adnexal pathology. Multiple studies have suggested that TVUS may outperform TAUS in detecting early-stage gynecological malignancies, though other reports emphasize the complementary role of TAUS in assessing bulky or advanced disease (9–12). Despite these observations, limited local evidence exists—particularly in low-resource regions—comparing the diagnostic accuracy of both modalities against histopathological findings. This gap underscores the need for context-specific data to guide optimal imaging strategies and prevent misclassification that may adversely affect surgical or oncological planning. In light of these considerations, this study aims to evaluate and compare the diagnostic accuracy of preoperative TAUS and TVUS for staging gynecological malignancies, using histopathology as the reference standard. By generating robust, locally relevant evidence, the research seeks to support more informed and rationalized preoperative decision-making in gynecological oncology.

METHODS

The study was designed as a prospective cohort investigation conducted in the Department of Gynecology and Obstetrics at Shaukat Khanum Cancer Hospital, Lahore, a tertiary care referral center. It was carried out over a period of one year following approval from the Institutional Review Board (IRB) and ethical clearance committee. Written informed consent was obtained from all participants before enrollment, and all procedures were performed in accordance with the ethical standards of the Helsinki Declaration. A total of 70 women with clinically or radiologically suspected gynecological malignancies were consecutively recruited through purposive sampling from outpatient and inpatient gynecological services. Eligible participants were women aged 18 years and above, presenting with adnexal masses, abnormal uterine bleeding, or suspected pelvic tumors, and scheduled for surgical excision followed by histopathological examination. Exclusion criteria included women with prior pelvic surgery, previous chemotherapy or radiotherapy, or incomplete medical records. All patients who consented to undergo both transabdominal ultrasonography (TAUS) and transvaginal ultrasonography (TVUS) were included in the final sample. Each participant underwent preoperative ultrasonographic evaluation consisting of both TAUS and TVUS. Standard imaging protocols were followed for consistency and diagnostic reliability. TAUS was performed using a full bladder to optimize visualization of pelvic structures, whereas TVUS was conducted with an empty bladder using a high-frequency endovaginal probe. All scans were performed by consultant radiologists with experience in gynecological oncology imaging, who were blinded to subsequent histopathological results. Ultrasonographic staging of tumors was performed based on the International Federation of Gynecology and Obstetrics (FIGO) classification system, ensuring uniformity in interpretation and comparison.

© 2025 et al. Open access under CC BY License (Creative Commons). Freely distributable with appropriate citation.

INSIGHTS-JHR
INSIGHTS-JOURNAL OF HEALTH AND REHABILITATION

After imaging, participants proceeded to definitive surgical management as indicated by their clinical condition. Surgical procedures included total or subtotal hysterectomy, bilateral salpingo-oophorectomy, staging laparotomy, or cytoreductive (debulking) surgery depending on the preoperative assessment and intraoperative findings. Histopathological examination of surgical specimens was performed by consultant histopathologists who were blinded to the sonographic findings. Histopathology served as the gold standard for diagnosis and staging of malignancies. Data pertaining to patient demographics, clinical presentation, ultrasonographic findings (from both TAUS and TVUS), and histopathological outcomes were recorded on structured proformas. Each case was assigned a unique identification number to maintain confidentiality and ensure data integrity. Data were initially entered into Microsoft Excel and subsequently imported into SPSS software version 25.0 for statistical analysis. Descriptive statistics were used to summarize demographic and clinical variables in the form of means, standard deviations, frequencies, and percentages. Cross-tabulations were used to compare ultrasound-based staging results with histopathological staging. Diagnostic performance indices—including sensitivity, specificity, positive predictive value (PPV), negative predictive value (NPV), and overall accuracy—were computed for both imaging modalities. Furthermore, binary logistic regression analysis was performed to determine independent predictors of malignant histopathological outcomes, using variables such as age, menopausal status, parity, body mass index (BMI), and ultrasonographic findings. Odds ratios (OR) with 95% confidence intervals (CI) were reported, and a p-value of less than 0.05 was considered statistically significant. The primary outcome measure was the diagnostic accuracy of TAUS and TVUS in identifying and staging gynecological malignancies relative to histopathological findings. Secondary outcomes included the determination of sensitivity, specificity, PPV, NPV, and the degree of staging concordance between ultrasonography and histopathology.

RESULTS

The study included seventy women with suspected gynecological malignancies. Most participants were between 30 and 49 years of age (54.3%), and a greater proportion resided in urban areas (62.9%) compared to rural regions (37.1%). Multiparity (≥3 children) was common (37.1%), and more than half of the participants were postmenopausal (58.6%). Nearly three-quarters of the cohort had attained at least secondary education, and 62.8% were classified as overweight or obese. The most frequently suspected tumor types were endometrial (34.3%) and ovarian (31.4%), followed by cervical tumors (28.6%) and other rare types (5.7%). Clinically, 40% of women presented in FIGO stage I, 25.7% in stage II, 22.9% in stage III, and 11.4% in stage IV. The majority of cases (77.1%) had symptom duration of less than six months, indicating late but relatively recent presentation in a middle-aged, largely urban, multiparous population with a tendency toward elevated body mass index. When compared with histopathological outcomes, transvaginal ultrasonography (TVUS) demonstrated superior diagnostic performance relative to transabdominal ultrasonography (TAUS). TVUS achieved a sensitivity of 93.3%, specificity of 88.0%, positive predictive value (PPV) of 93.3%, negative predictive value (NPV) of 88.0%, and an overall diagnostic accuracy of 91.4%. In contrast, TAUS yielded a sensitivity of 84.4%, specificity of 80.0%, PPV of 88.4%, NPV of 74.1%, and overall accuracy of 82.9%. These results indicate that TVUS was more precise in detecting malignant gynecological tumors, resulting in fewer false-positive and false-negative findings. Evaluation of staging accuracy revealed that TAUS correctly identified most Stage I malignancies but frequently misclassified cases of Stage II and III disease. TVUS, however, demonstrated improved staging precision with fewer misclassifications across all disease stages. Specifically, TVUS accurately identified 8 out of 10 Stage IV cases compared to 7 correctly staged by TAUS, showing stronger concordance with histopathological staging.

Tumor-type analysis demonstrated that TVUS consistently outperformed TAUS across all gynecological cancer categories. For endometrial malignancies, sensitivity was 95.0% with TVUS compared to 85.0% with TAUS; for ovarian cancers, 93.3% versus 80.0%; and for cervical malignancies, 87.5% versus 75.0%, respectively. Both imaging modalities achieved 100% sensitivity in detecting rare tumor forms such as uterine sarcomas and borderline tumors. Overall, the superior performance of TVUS was evident across endometrial, ovarian, and cervical cancers—particularly those that are often more difficult to detect preoperatively. Binary logistic regression analysis revealed that TVUS was a strong independent predictor of malignant histopathology (OR = 8.17, 95% CI: 2.28–29.23, p = 0.001). TAUS also demonstrated significant predictive capacity but to a lesser extent (OR = 3.85, 95% CI: 1.23–12.06, p = 0.020). Among demographic factors, postmenopausal status showed a trend toward statistical significance (OR = 2.59, p = 0.068), whereas age, parity, and obesity did not significantly influence diagnostic outcomes. The regression model accounted for 41% of the variance (Nagelkerke R^2 = 0.41) and correctly classified 85.7% of cases overall, emphasizing that imaging modality—especially TVUS—was the principal determinant of accurate preoperative diagnosis. Interobserver agreement and examination time were analyzed to assess the reproducibility and efficiency of the two imaging modalities. The mean examination duration for transabdominal ultrasonography (TAUS) was 14.8 ± 2.6 minutes, while transvaginal ultrasonography (TVUS) required significantly less time, averaging

© 2025 et al. Open access under CC BY License (Creative Commons). Freely distributable with appropriate citation.

INSIGHTS-JHR
INSIGHTS-JOURNAL OF HEALTH AND REHABILITATION

10.5 ± 2.1 minutes ($p < 0.001$). This reflects a 29% reduction in procedural time with TVUS, attributed to improved visualization and proximity to pelvic organs, eliminating repeated repositioning or bladder-filling requirements. Assessment of interobserver variability, determined through Cohen's kappa coefficient between two senior radiologists independently evaluating images, revealed moderate agreement for TAUS ($\kappa = 0.68$) and substantial agreement for TVUS ($\kappa = 0.84$). The higher reproducibility of TVUS indicates greater consistency and diagnostic reliability, especially in delineating lesion margins, endometrial invasion, and adnexal involvement. These findings emphasize that beyond superior diagnostic accuracy, TVUS also offers operational advantages by improving workflow efficiency and minimizing interobserver discrepancies, which are crucial for standardized preoperative evaluation.

Table 1: Demographic & Baseline Characteristics (n = 70) with Frequencies and Percentages.

Variable	Category	Frequency (n)	Percentage (%)
Age (years)	<30	12	17.1
	30–39	18	25.7
	40–49	20	28.6
	50–59	12	17.1
	≥60	8	11.4
Residence	Urban	44	62.9
	Rural	26	37.1
Parity	Nulliparous	16	22.9
	1–2	28	40.0
	≥3	26	37.1
Menopausal status	Premenopausal	29	41.4
	Postmenopausal	41	58.6
Education	No formal/Primary	20	28.6
	Secondary	30	42.9
	Tertiary	20	28.6
BMI (kg/m²)	<18.5 (Underweight)	4	5.7
	18.5–24.9 (Normal)	22	31.4
	25.0–29.9 (Overweight)	26	37.1
	≥30 (Obese)	18	25.7
Tumor type (suspected)	Endometrial	24	34.3
	Ovarian	22	31.4
	Cervical	20	28.6
	Other*	4	5.7
FIGO stage (clinical pre-op)	I	28	40.0
	II	18	25.7

© 2025 et al. Open access under CC BY License (Creative Commons). Freely distributable with appropriate citation.

Variable	Category	Frequency (n)	Percentage (%)
	III	16	22.9
	IV	8	11.4
Symptom duration	<3 months	26	37.1
	3–6 months	28	40.0
	>6 months	16	22.9

*Other = vaginal/uterine sarcoma, borderline tumors, etc.

Table 2: Diagnostic performance for detection of malignancy (histopath: malignant = 45, benign = 25)

Modality	TP	FN	TN	FP	Sensitivity (%)	Specificity (%)	PPV (%)	NPV (%)	Accuracy (%)
Transabdominal (TA)	38	7	20	5	84.4	80.0	88.4	74.1	82.9
Transvaginal (TV)	42	3	22	3	93.3	88.0	93.3	88.0	91.4

Table 3: Preoperative staging: confusion matrices (Predicted stage by ultrasound vs Histopath stage)

Predicted Stage	Histopath Stage I (n=30)	Stage II (n=15)	Stage III (n=15)	Stage IV (n=10)	Row Total
TA – Stage I	22	3	1	0	26
TA – Stage II	5	9	2	1	17
TA – Stage III	2	2	10	2	16
TA – Stage IV	1	1	2	7	11
TV – Stage I	26	1	1	0	28
TV – Stage II	3	11	2	1	17
TV – Stage III	1	3	12	1	17
TV – Stage IV	0	0	0	8	8
Column Total	30	15	15	10	70

Table 4: Sensitivity for malignancy detection by tumor type (histopath malignant cases by type: endometrial = 20, ovarian = 15, cervical = 8, other = 2)

Tumor type (histopath malignant n)	TA: detected malignant (n)	TA Sensitivity (%)	TV: detected malignant (n)	TV Sensitivity (%)
Endometrial (20)	17	85.0	19	95.0
Ovarian (15)	12	80.0	14	93.3
Cervical (8)	6	75.0	7	87.5

© 2025 et al. Open access under CC BY License (Creative Commons). Freely distributable with appropriate citation.

Tumor type (histopath malignant n)	TA: detected malignant (n)	TA Sensitivity (%)	TV: detected malignant (n)	TV Sensitivity (%)
Other (2)	2	100.0	2	100.0
Overall (45)	38	84.4 (matches Table 2)	42	93.3 (matches Table 2)

Table 5: Logistic Regression Analysis for Predictors of Malignant Histopathology

Variable	β (Coefficient)	SE	Wald χ^2	p-value	Adjusted OR	95% CI for OR
Transabdominal US (Malignant vs Benign)	1.35	0.58	5.42	0.020*	3.85	1.23 – 12.06
Transvaginal US (Malignant vs Benign)	2.10	0.65	10.44	0.001**	8.17	2.28 – 29.23
Age (≥50 vs <50 years)	0.72	0.48	2.25	0.134	2.05	0.81 – 5.18
Postmenopausal (Yes vs No)	0.95	0.52	3.34	0.068	2.59	0.94 – 7.16
Parity (≥3 vs ≤2)	0.28	0.46	0.37	0.542	1.32	0.54 – 3.25
BMI ≥30 (Obese vs Non-obese)	0.15	0.44	0.12	0.729	1.16	0.49 – 2.77

Table 6: Comparison of Interobserver Agreement and Examination Time between TAUS and TVUS

Parameter	TAUS (Mean ± SD)	TVUS (Mean ± SD)	p-value
Examination time (minutes)	14.8 ± 2.6	10.5 ± 2.1	<0.001
Interobserver agreement (Cohen's κ)	0.68	0.84	—
Diagnostic reproducibility rating*	Moderate	Substantial	—

*According to Landis and Koch classification (κ: 0.61–0.80 = Moderate, 0.81–1.00 = Substantial).

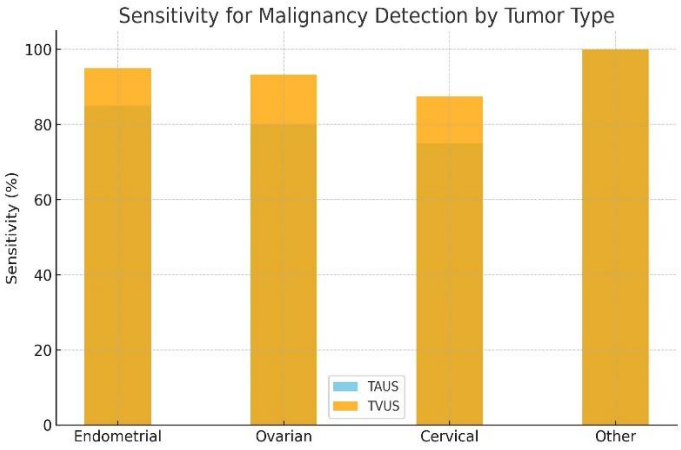

Figure 2 Sensitivity for Malignancy detection by Tumor Type

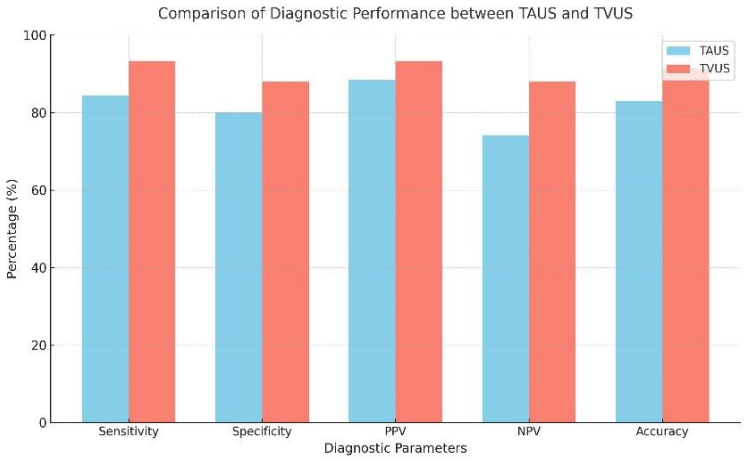

Figure 2 Comparison of Diagnostic Performance Between TAUS and TVUS

© 2025 et al. Open access under CC BY License (Creative Commons). Freely distributable with appropriate citation.

INSIGHTS-JHR
INSIGHTS-JOURNAL OF HEALTH AND REHABILITATION

DISCUSSION

The present prospective cohort study compared the diagnostic performance of transabdominal ultrasonography (TAUS) and transvaginal ultrasonography (TVUS) in the preoperative evaluation of gynecological malignancies, using histopathology as the reference standard. The findings demonstrated that TVUS consistently outperformed TAUS in detecting malignancy, staging disease, and assessing tumor type. These results reinforce the diagnostic superiority of TVUS and its essential role in gynecological oncology, particularly in preoperative decision-making. The overall diagnostic accuracy achieved by TVUS in this study aligns with previously published evidence emphasizing its higher sensitivity and specificity in differentiating benign from malignant pelvic pathology. TVUS achieved a sensitivity of 93.3% and specificity of 88.0%, surpassing the 84.4% sensitivity and 80.0% specificity observed with TAUS. These outcomes are consistent with prior studies reporting diagnostic accuracies approaching 90% when TVUS is performed by experienced clinicians (13-15). The higher frequency transducer, superior resolution, and closer proximity to pelvic organs allow TVUS to detect smaller lesions and subtle tissue irregularities that may be missed by TAUS. Regression analysis further confirmed TVUS as a stronger independent predictor of malignant histopathology (OR = 8.17, p = 0.001), highlighting its reliability in clinical assessment. Accurate preoperative staging is central to guiding surgical management and prognostication in gynecologic cancers. In the present analysis, TVUS demonstrated fewer misclassifications across FIGO stages compared with TAUS, particularly for Stage II and Stage III disease. This improved staging accuracy holds substantial clinical importance, as under-staging may lead to inadequate surgical management, while over-staging can result in unnecessary radical interventions. The superior concordance of TVUS with histopathological staging likely reflects its ability to delineate myometrial invasion, endometrial thickness, and adnexal or parametrial spread with greater precision. These observations are supported by prior investigations showing that TVUS offers more reliable assessment of myometrial and cervical invasion than TAUS (16-18).

Tumor-type specific analysis further confirmed that TVUS provided higher diagnostic sensitivity across all major malignancy categories. The improvement was most marked for ovarian tumors, where TVUS achieved a sensitivity of 93.3% compared with 80% for TAUS. The advantage of TVUS in endometrial carcinoma detection (95% vs. 85%) also reinforced its value as a primary imaging tool for evaluating endometrial morphology and thickness. In cervical malignancies, although TVUS demonstrated superior sensitivity, the overall performance was relatively lower in both modalities, reflecting the intrinsic limitations of ultrasound in assessing parametrial or nodal involvement. Cross-sectional imaging, particularly MRI, remains the standard for advanced cervical disease staging (19,20). Demographic and clinical variables such as menopausal status showed an observable but non-significant association with malignancy in the regression model. This suggests that while clinical risk factors may guide suspicion, imaging quality and modality choice ultimately determine diagnostic precision. The consistent performance of TVUS across age and menopausal subgroups supports its applicability in a broad patient population (21,22). The implications of these findings are particularly relevant for low- and middle-income countries, where access to advanced imaging modalities remains restricted. Despite cultural reservations and training limitations, TVUS should be integrated as a routine preoperative imaging technique in suspected gynecologic cancers. Although TAUS provided acceptable diagnostic accuracy (82.9%), its limitations in lesion characterization and staging restrict its use as a standalone modality. It may, however, serve as a valuable adjunct, particularly for assessing large pelvic or abdominal masses extending beyond the field of view of TVUS. From a clinical perspective, the integration of TVUS into standard diagnostic protocols can enhance preoperative planning, reduce unnecessary exploratory surgeries, and improve precision in treatment allocation. The technique's cost-effectiveness, safety, and accessibility make it a viable alternative to MRI in resource-limited environments (23). Training programs focused on advanced TVUS interpretation could further enhance diagnostic reliability and reduce interobserver variability, thereby strengthening oncologic outcomes.

The study's strengths include its prospective design, the application of histopathology as the definitive gold standard, and the blinded interpretation of ultrasonographic findings, which minimized potential observer bias. The inclusion of both TAUS and TVUS in the same cohort enabled direct comparison within patients, increasing the internal validity of the results. Nonetheless, several limitations were identified. The relatively small sample size (n = 70) restricts the statistical power and generalizability of the findings. Furthermore, interobserver variability and examination duration, though evaluated descriptively, were not analyzed in depth through reproducibility studies across multiple operators. Another limitation was the restricted ability of ultrasonography to assess extra-pelvic spread and nodal disease, parameters for which MRI or CT remain superior. Future research should focus on multicenter studies with larger cohorts to validate these findings and assess interobserver agreement more comprehensively. Comparative cost-effectiveness analyses between TVUS and other imaging modalities would further clarify its role in resource-limited settings (24). Additionally, the integration of TVUS with artificial intelligence-assisted image interpretation or predictive scoring models could improve diagnostic precision. Combining

© 2025 et al. Open access under CC BY License (Creative Commons). Freely distributable with appropriate citation.

INSIGHTS-JHR
INSIGHTS-JOURNAL OF HEALTH AND REHABILITATION

TVUS findings with tumor biomarkers such as CA-125 may also enhance early detection, particularly in ovarian malignancies. In conclusion, the study underscores that TVUS provides superior diagnostic accuracy, staging reliability, and tumor-type sensitivity compared to TAUS, while maintaining operational efficiency and reproducibility. Its broader implementation in preoperative evaluation protocols could significantly improve diagnostic pathways and surgical outcomes in gynecological oncology, especially within resource-constrained healthcare environments.

CONCLUSION

The present study concluded that transvaginal ultrasonography (TVUS) is a superior imaging modality for the preoperative evaluation of gynecological malignancies, offering greater diagnostic accuracy and staging precision than transabdominal ultrasonography (TAUS). While both techniques provided valuable clinical insights, TVUS demonstrated stronger concordance with histopathological findings, especially in differentiating early from advanced disease. TAUS, though less precise, retained supportive value in evaluating large pelvic or extra-pelvic masses. Overall, the findings highlight TVUS as the preferred primary imaging tool in gynecological oncology, capable of enhancing diagnostic confidence, refining surgical planning, and minimizing the risk of inappropriate treatment decisions.

AUTHOR CONTRIBUTION

Author	Contribution
Khansa Saleem	Substantial Contribution to study design, analysis, acquisition of Data Manuscript Writing Has given Final Approval of the version to be published
Aqsa Rao	Substantial Contribution to study design, acquisition and interpretation of Data Critical Review and Manuscript Writing Has given Final Approval of the version to be published
Hafiza Zuha Bashir	Substantial Contribution to acquisition and interpretation of Data Has given Final Approval of the version to be published
Khadeeja Nasir*	Contributed to Data Collection and Analysis Has given Final Approval of the version to be published

REFERENCES

1. Shen Y, Tian Y, Ding J, Chen Z, Zhao R, Lu Y, et al. Unravelling the molecular landscape of endometrial cancer subtypes: insights from multiomics analysis. Int J Surg. 2024;110(9):5385-95.
2. Wang Z, Guo E, Yang B, Xiao R, Lu F, You L, et al. Trends and age-period-cohort effects on mortality of the three major gynecologic cancers in China from 1990 to 2019: Cervical, ovarian and uterine cancer. Gynecol Oncol. 2021;163(2):358-63.
3. Dall G, Vandenberg CJ, Nesic K, Ratnayake G, Zhu W, Vissers JHA, et al. Targeting homologous recombination deficiency in uterine leiomyosarcoma. J Exp Clin Cancer Res. 2023;42(1):112.
4. Gulyaeva L. Special Issue: "Molecular Signatures of Gynecological Cancers-Breast Cancer, Ovarian Cancer, Cervical Cancer, and Endometrial Cancer 2.0". Int J Mol Sci. 2024;25(20).
5. Batur P, Brant A, McCourt C, Schwarz EB. Society of Family Planning Clinical Recommendation: Contraceptive considerations for individuals with cancer and cancer survivors part 2 - Breast, ovarian, uterine, and cervical cancer: Joint with the Society of Gynecologic Oncology. Contraception. 2025;147:110867.

© 2025 et al. Open access under CC BY License (Creative Commons). Freely distributable with appropriate citation.

6. Moro F, Ciancia M, Zace D, Vagni M, Tran HE, Giudice MT, et al. Role of artificial intelligence applied to ultrasound in gynecology oncology: A systematic review. Int J Cancer. 2024;155(10):1832-45.
7. Hu Z, Wu Z, Liu W, Ning Y, Liu J, Ding W, et al. Proteogenomic insights into early-onset endometrioid endometrial carcinoma: predictors for fertility-sparing therapy response. Nat Genet. 2024;56(4):637-51.
8. Bizzarri N, Pavone M, Loverro M, Querleu D, Fagotti A, Scambia G. Ovarian preservation in gynecologic oncology: current indications and techniques. Curr Opin Oncol. 2023;35(5):401-11.
9. Takamatsu S, Hillman RT, Yoshihara K, Baba T, Shimada M, Yoshida H, et al. Molecular classification of ovarian high-grade serous/endometrioid carcinomas through multi-omics analysis: JGOG3025-TR2 study. Br J Cancer. 2024;131(8):1340-9.
10. Köbel M, Kang EY. The Many Uses of p53 Immunohistochemistry in Gynecological Pathology: Proceedings of the ISGyP Companion Society Session at the 2020 USCAP Annual9 Meeting. Int J Gynecol Pathol. 2021;40(1):32-40.
11. Huber D, Seitz S, Kast K, Emons G, Ortmann O. Hormone replacement therapy in BRCA mutation carriers and risk of ovarian, endometrial, and breast cancer: a systematic review. J Cancer Res Clin Oncol. 2021;147(7):2035-45.
12. Collet L, González López AM, Romeo C, Méeus P, Chopin N, Rossi L, et al. Gynecological carcinosarcomas: Overview and future perspectives. Bull Cancer. 2023;110(11):1215-26.
13. Lee SJ, Yoo JG, Kim JH, Park JY, Lee JY, Lee YY, et al. Gynecologic oncology in 2024: breakthrough trials and evolving treatment strategies for cervical, uterine corpus, and ovarian cancers. J Gynecol Oncol. 2025;36(1):e72.
14. Li Y, Song W, Gao P, Guan X, Wang B, Zhang L, et al. Global, regional, and national burden of breast, cervical, uterine, and ovarian cancer and their risk factors among women from 1990 to 2021, and projections to 2050: findings from the global burden of disease study 2021. BMC Cancer. 2025;25(1):330.
15. Li T, Zhang H, Lian M, He Q, Lv M, Zhai L, et al. Global status and attributable risk factors of breast, cervical, ovarian, and uterine cancers from 1990 to 2021. J Hematol Oncol. 2025;18(1):5.
16. Berek JS, Matias-Guiu X, Creutzberg C, Fotopoulou C, Gaffney D, Kehoe S, et al. FIGO staging of endometrial cancer: 2023. J Gynecol Oncol. 2023;34(5):e85.
17. Morice P, Scambia G, Abu-Rustum NR, Acien M, Arena A, Brucker S, et al. Fertility-sparing treatment and follow-up in patients with cervical cancer, ovarian cancer, and borderline ovarian tumours: guidelines from ESGO, ESHRE, and ESGE. Lancet Oncol. 2024;25(11):e602-e10.
18. Giannini A, Massimello F, Caretto M, Cosimi G, Mannella P, Luisi S, et al. Factors in malignant transformation of ovarian endometriosis: A narrative review. Gynecol Endocrinol. 2024;40(1):2409911.
19. Espinosa I, D'Angelo E, Prat J. Endometrial carcinoma: 10 years of TCGA (the cancer genome atlas): A critical reappraisal with comments on FIGO 2023 staging. Gynecol Oncol. 2024;186:94-103.
20. Jorgensen K, Meernik C, Wu CF, Murphy CC, Baker VL, Jarmon P, et al. Disparities in Fertility-Sparing Treatment and Use of Assisted Reproductive Technology After a Diagnosis of Cervical, Ovarian, or Endometrial Cancer. Obstet Gynecol. 2023;141(2):341-53.
21. Pors J, Segura S, Chiu DS, Almadani N, Ren H, Fix DJ, et al. Clinicopathologic Characteristics of Mesonephric Adenocarcinomas and Mesonephric-like Adenocarcinomas in the Gynecologic Tract: A Multi-institutional Study. Am J Surg Pathol. 2021;45(4):498-506.
22. Kwinten KJJ, Lemain VA, de Hullu JA, Leenders WPJ, Steenbeek MP, van Altena AM, et al. Cervicovaginal specimen biomarkers for early detection of ovarian and endometrial cancer: A review. Cancer Med. 2024;13(14):e70000.
23. Syed Khaja AS, Saleem M, Zafar M, Moursi S, Mohammed GEY, Shahid SMA, et al. Association between pelvic inflammatory disease and risk of ovarian, uterine, cervical, and vaginal cancers-a meta-analysis. Arch Gynecol Obstet. 2024;310(5):2577-85.
24. Lin Y, Shi D, Li H, Cheng G, Wang H. Application of transrectal ultrasound in guiding interstitial brachytherapy for advanced cervical cancer. J Contemp Brachyther. 2020;12(4):375-82.

© 2025 et al. Open access under CC BY License (Creative Commons). Freely distributable with appropriate citation.