INSIGHTS-JOURNAL OF
HEALTH AND REHABILITATION

INSIGHTS-JHR
INSIGHTS-JOURNAL OF HEALTH AND REHABILITATION

FUNCTIONAL AND RADIOLOGICAL OUTCOME OF PROXIMAL HUMERUS FRACTURE TREATED WITH PROXIMAL HUMERAL INTERLOCKING SYSTEM (PHILOS) PLATE

Original Research

Ali Ekram[1]*, Adeel Ahmed Siddiqui[2], Sunil Kumar[3], Syed Muhammad Khalid Karim[4], Muhammad Noman[4], Mairajuddin[1], Muhammad Taha Tariq[1]
[1]Postgraduate Trainee, Dow University of Health Sciences, Karachi, Pakistan.
[2]Professor, Orthopedic Unit-II, Dow University of Health Sciences, Karachi, Pakistan.
[3]Associate Professor, Department of Orthopedics, Dow University of Health Sciences, Karachi, Pakistan.
[4]Assistant Professor, Orthopedic Unit-II, Dow University of Health Sciences, Karachi, Pakistan.
Corresponding Author: Ali Ekram, Postgraduate Trainee, Dow University of Health Sciences, Karachi, Pakistan, alimallick931@gmail.com
Acknowledgement: The authors sincerely thank the Department of Orthopedics, Civil Hospital Karachi, for their support throughout the study.

Conflict of Interest: None
Grant Support & Financial Support: None

ABSTRACT

Background: Proximal humerus fractures are among the most common upper limb injuries, particularly in middle-aged and elderly populations, with their incidence rising due to high-energy trauma in younger individuals and osteoporosis in older adults. These fractures account for 4–10% of all fractures and are associated with significant morbidity when inadequately managed. Surgical fixation has evolved from K-wiring and tension band wiring to locking plate fixation, with the PHILOS plate gaining attention for its angular stability, early mobilization potential, and improved functional recovery.

Objective: The study aimed to evaluate the functional and radiological outcomes of proximal humerus fractures managed surgically using the proximal humeral internal locking system (PHILOS) plate.

Methods: This prospective descriptive study was conducted from December 2023 to November 2024 and included 88 patients aged above 18 years with displaced proximal humerus fractures meeting Neer's operative criteria. Patients underwent open reduction and internal fixation with a PHILOS plate using a standard deltopectoral approach. Postoperative follow-up was performed at 3, 6, and 9 months. Functional outcomes were assessed using Neer's scoring system, while radiological outcomes were evaluated through serial radiographs for fracture healing. Statistical analyses included paired t-tests, McNemar's test, and marginal homogeneity tests, with significance set at $p < 0.05$.

Results: The mean age of patients was 37.93 ± 12.63 years, with 61 males (69.32%) and 27 females (30.68%). The mean Neer score improved from 68.64 ± 8.65 at 3 months to 78.49 ± 4.85 at 6 months ($p = 0.0005$), and further to 85.24 ± 9.53 at 9 months ($p = 0.0005$). Favorable functional outcomes (excellent and satisfactory) were achieved in 86.36% of patients at 9 months. Radiological healing improved from 29.55% at 3 months to 76.14% at 6 months ($p = 0.0005$) and 86.36% at 9 months ($p = 0.004$). Complications included surgical site infection (13.6%), avascular necrosis (5.7%), screw back-out (2.3%), and shoulder stiffness (6.8%).

Conclusion: The PHILOS plate demonstrated effective fracture stabilization, early functional recovery, and satisfactory radiological outcomes in patients with proximal humerus fractures. Nevertheless, awareness of potential complications and careful patient selection remain essential for optimizing outcomes.

Keywords: Avascular necrosis, Bone plates, Humeral fractures, Internal fixation, Osteosynthesis, Shoulder joint, Surgical wound infection.

© 2025 et al. Open access under CC BY License (Creative Commons). Freely distributable with appropriate citation.



INTRODUCTION

Proximal humerus fracture (PHF) is a common injury that occurs near the shoulder joint and represents one of the most significant challenges in orthopedic practice. It accounts for approximately 4–10% of all fractures and is recognized as the third most frequent fracture in the elderly population, following hip and distal radius fractures (1,2). The rising prevalence of PHF, estimated at 90–105 cases per 100,000 individuals annually, is strongly associated with the aging demographic and the increasing burden of osteoporosis, with reported annual incidence rates climbing by nearly 13.7% (3,4). These fractures typically result from low-energy falls on an outstretched hand among the elderly, while high-energy mechanisms such as road traffic accidents and sports injuries are more common in younger patients (5,6). The management of PHF is complex and continues to provoke debate regarding the optimal treatment strategy. Non-operative measures are often reserved for stable, minimally displaced fractures, whereas surgical treatment is indicated for displaced, unstable, or fracture dislocations, particularly those caused by high-energy trauma (7,8). The overarching goal of intervention is to restore functional mobility, alleviate pain, and prevent long-term disability. However, the literature highlights persistent challenges, including postoperative stiffness, malunion, nonunion, implant-related complications, osteonecrosis, and residual rotator cuff weakness, regardless of the chosen method of fixation (9). This underscores the need for refinement in surgical approaches to improve patient satisfaction and functional recovery.

In recent years, the proximal humeral internal locking system (PHILOS) has emerged as an advanced surgical option designed to provide rigid fixation with angular stability. This next-generation locking plate functions as an internal-external fixator, enhancing the resistance of screws to pullout and facilitating early rehabilitation through stable fixation (10-13). Clinical studies have reported favorable outcomes with PHILOS plates, with a study documenting satisfactory to excellent functional recovery in most patients, albeit with a small proportion experiencing complications (14). Likewise, another study observed that the majority of patients treated with PHILOS achieved excellent or satisfactory results as assessed by Neer's criteria (8). These findings suggest that PHILOS plating may offer a distinct advantage over conventional techniques, potentially improving both shoulder function and overall quality of life. Despite growing evidence, controversy persists regarding the consistency of outcomes and the risk of complications associated with PHILOS fixation. Therefore, this study aims to analyze the functional and radiological outcomes of proximal humerus fractures treated with PHILOS plates, with the objective of determining whether this technique offers superior clinical results and enhanced patient independence compared to conventional fixation methods.

METHODS

This prospective descriptive study was conducted in the Department of Orthopedics at Civil Hospital Karachi, Pakistan, over a one-year period from December 1, 2023, to November 30, 2024. Ethical approval was obtained from the Research Evaluation Unit, College of Physicians and Surgeons Pakistan (CPSP), under approval number CPSP/REU/OSG-2023-183-2913, and the study adhered to the principles of the Declaration of Helsinki. All participants were fully informed about the study protocol, and written informed consent was obtained prior to enrollment. The study population included patients aged above 18 years who presented with proximal humerus fractures confirmed on plain radiographs and fulfilling Neer's criteria for operative displacement. Exclusion criteria included patients with undisplaced fractures, open fractures, associated neurovascular or head injuries, uncontrolled diabetes, or those who were deemed medically unfit for surgery. Eligible participants were recruited through the Emergency Department, ensuring a representative sample of acute fracture presentations. Preoperative evaluation included documentation of demographic characteristics such as age, gender, height, weight, and body mass index (BMI), as well as the mechanism of injury. Imaging assessment comprised standard anteroposterior, lateral, and axillary views of the affected shoulder. Neer's classification system was used to categorize fractures, and computed tomography (CT) scans were obtained in selected cases to clarify complex articular involvement. All findings were systematically recorded on a structured proforma by the primary researcher to maintain data uniformity and reliability.

All surgical procedures were performed by a consultant orthopedic surgeon with more than five years of post-fellowship experience. The standard deltopectoral approach was used under general anesthesia with patients positioned in the beach-chair position. A longitudinal incision was made along the deltopectoral groove, with careful preservation of the cephalic vein. The deltoid and pectoralis

© 2025 et al. Open access under CC BY License (Creative Commons). Freely distributable with appropriate citation.

INSIGHTS-JHR
INSIGHTS-JOURNAL OF HEALTH AND REHABILITATION

major were retracted to expose the fracture site. Direct visualization enabled accurate reduction, which was temporarily maintained with Kirschner wires when required. Definitive fixation was achieved using a proximal humeral internal locking system (PHILOS) plate positioned laterally and secured with locking screws under fluoroscopic guidance. Hemostasis was ensured, and the wound was closed in layers over a suction drain. Postoperatively, all patients were immobilized in an arm sling, and passive mobilization was initiated according to individual pain tolerance. A structured physiotherapy program was prescribed for all participants to support progressive restoration of range of motion and function. Outcomes were assessed both functionally and radiologically at 3, 6, and 9 months postoperatively. Functional outcomes were evaluated using Neer's scoring system, which assesses pain, range of motion, and functional ability, with scores ranging from 0 to 100. Scores were categorized as excellent, satisfactory, unsatisfactory, or failure, and for analytical purposes, excellent and satisfactory outcomes were considered favorable. Radiological assessment involved anteroposterior and lateral radiographs to evaluate fracture healing, defined by callus formation and/or disappearance of fracture lines. Radiological outcomes were recorded as "good" or "poor."

Sample size calculation was based on findings of a study which reported 65% excellent and 20% satisfactory outcomes following PHILOS fixation (2). Using these values, a total of 88 patients were required to estimate favorable outcomes within a 10% margin of error at a 95% confidence interval, ensuring sufficient statistical power. Statistical analysis was conducted using SPSS version 19.0 (SPSS Inc., Chicago, IL, USA). Continuous variables such as age, height, weight, BMI, and operative time were presented as mean ± standard deviation (SD). Categorical variables, including gender, side of involvement, mechanism of injury, and outcome categories, were presented as frequencies and percentages. The paired t-test was applied to compare mean Neer scores across follow-up intervals (3 vs. 6 months, and 6 vs. 9 months). McNemar's test and marginal homogeneity tests were used to compare repeated categorical outcome measures. A p-value of less than 0.05 was considered statistically significant.

RESULTS

A total of 88 patients with surgically treated proximal humerus fractures using PHILOS plates were analyzed. The mean age of the cohort was 37.93 ± 12.63 years, with a predominance of males (69.32%) compared to females (30.68%). The mean weight was 72.87 ± 16.91 kg, mean height 160.34 ± 9.56 cm, and mean BMI 28.38 ± 6.68 kg/m². The average duration of surgery was 151.82 ± 50.59 minutes. Road traffic accidents were the leading cause of injury, accounting for 69.32% of cases, followed by falls in 18.18% and sports-related injuries in 12.50%. The right shoulder was more frequently affected (65.90%) compared to the left (34.10%). According to Neer's classification, one-part fractures represented 52.30% of cases, two-part fractures 45.50%, and three-part fractures 2.30%, with no four-part fractures observed. Functional outcomes demonstrated progressive and statistically significant improvement throughout follow-up. The mean NEER score at 3 months was 68.64 ± 8.65, which increased to 78.49 ± 4.85 at 6 months ($p = 0.0005$), and further improved to 85.24 ± 9.53 at 9 months ($p = 0.0005$). When categorized, functional outcomes at the final follow-up revealed that 47.73% of patients achieved excellent recovery, 38.64% had satisfactory outcomes, 9.09% showed unsatisfactory results, and 4.55% were classified as failures. The proportion of favorable outcomes (excellent or satisfactory) significantly increased over time. Radiological assessment also demonstrated marked improvement with fracture healing. At 3 months, only 29.55% of patients achieved good radiological outcomes, which increased to 76.14% at 6 months ($p = 0.0005$) and further to 86.36% at 9 months ($p = 0.004$). Postoperative complications were recorded in a minority of patients. Surgical site infections occurred in 13.6% of cases, avascular necrosis in 5.7%, screw back-out in 2.3%, and postoperative shoulder stiffness in 6.8%. Despite these complications, the majority of patients progressed toward functional and radiological recovery.

Table 1: Baseline Demographic, Injury, and Surgical Characteristics of the Study Population (n = 88)

Variable	Value
Age (years)	37.93 ± 2.63
Weight (kg)	72.87 ± 16.91
Height (cm)	160.34 ± 9.56
BMI (kg/m²)	28.38 ± 6.68
Duration of Surgery (minutes)	151.82 ± 50.59
Gender	
Male	61 (69.32%)

© 2025 et al. Open access under CC BY License (Creative Commons). Freely distributable with appropriate citation.

Variable	Value
Female	27 (30.68%)
Mode of Injury	
Road Traffic Accident (RTA)	61 (69.32%)
Fall	16 (18.18%)
Sport	11 (12.50%)
Fracture Side	
Right	58 (65.90%)
Left	30 (34.10%)
NEER Classification	
1-Part	46 (52.30%)
2-Part	40 (45.50%)
3-Part	2 (2.30%)
4-Part	0 (0.00%)

Table 2: Comparison of Functional Outcomes at 3rd, 6th, and 9th Month Postoperative Follow-Up

Functional Outcome	3rd Month	6th Month	9th Month	P-value (3rd vs. 6th)	P-value (6th vs. 9th)
Excellent	0 (0.00%)	0 (0.00%)	42 (47.73%)	0.0005	0.0005
Satisfactory	6 (6.82%)	64 (72.73%)	34 (38.64%)		
Unsatisfactory	67 (76.14%)	20 (22.73%)	8 (9.09%)		
Failure	15 (17.05%)	4 (4.55%)	4 (4.55%)		

Table 3: Postoperative Complications Observed

Complication	Patients (n)	Percentage (%)
Surgical Site Infection	12	13.60%
Avascular Necrosis	5	5.70%
Screw Back Out	2	2.30%
Stiffness of Shoulder	6	6.80%

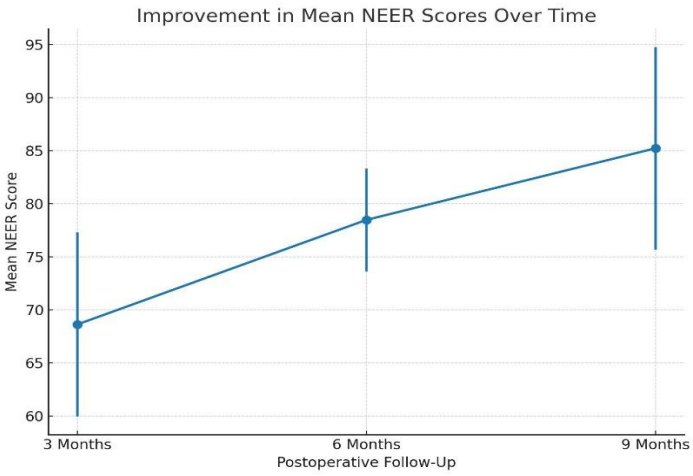

Figure 2 Improvement in Mean MEER Scores Over Time

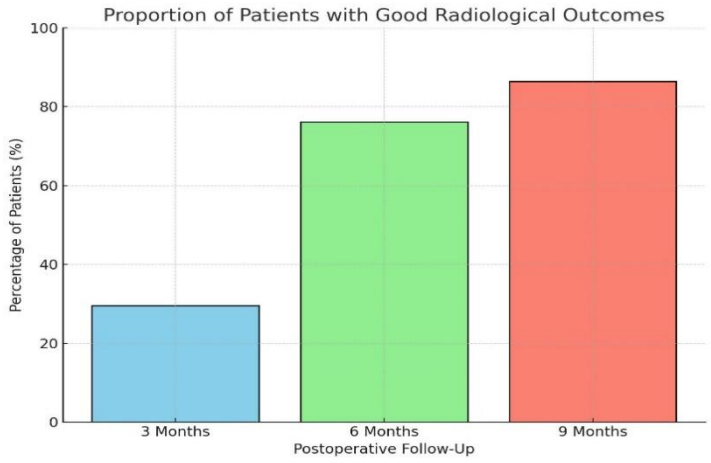

Figure 2 Proportion of Patients with Good Radiological Outcomes

© 2025 et al. Open access under CC BY License (Creative Commons). Freely distributable with appropriate citation.

INSIGHTS-JHR
INSIGHTS-JOURNAL OF HEALTH AND REHABILITATION

DISCUSSION

The management of proximal humerus fractures has undergone significant evolution over the years, transitioning from conservative methods and K-wire fixation to more advanced techniques such as open reduction and internal fixation with locking plates and prosthetic replacements. Among these, the PHILOS plate has emerged as a widely adopted fixation method due to its ability to provide angular stability, promote primary fracture healing, and allow for early mobilization, which are critical factors in achieving functional recovery (15–17). In the present study, the majority of patients were relatively young adults, with a mean age in the late 30s, and road traffic accidents were identified as the leading cause of injury. This finding differs from several studies conducted in Western populations, where proximal humerus fractures are more common in elderly patients with osteoporosis. The predominance of young males and high-energy trauma in this series highlights the burden of motor vehicle accidents in developing countries and its impact on fracture epidemiology. The right shoulder was more frequently involved, and one- and two-part fractures were the most prevalent patterns, which is consistent with reports in similar regional studies (16). Functional outcomes demonstrated steady improvement over time, with 86.36% of patients achieving excellent or satisfactory results at nine months of follow-up. These findings are in line with earlier clinical investigations that reported favorable outcomes with PHILOS fixation, where most patients regained satisfactory shoulder function and independence within the first postoperative year (17,18). Radiological outcomes mirrored the functional improvements, with more than 85% of patients achieving good fracture healing by the ninth month, indicating effective restoration of anatomic alignment and stability.

Despite these encouraging results, complications were not negligible. Surgical site infection was observed in approximately 13.6% of patients, a rate that is higher than reported in many international series. Other complications such as avascular necrosis (5.7%), screw back-out (2.3%), and postoperative stiffness (6.8%) were documented, which are comparable to previously published complication rates. Literature reviews and multicenter analyses have described screw penetration or cut-out rates ranging from 7% to 13% and avascular necrosis rates that vary widely, from as low as 0% to as high as 68% depending on fracture complexity and surgical technique (19-21). These findings emphasize the inherent risks associated with surgical fixation of proximal humerus fractures, particularly in cases involving medial hinge disruption or dorsomedial comminution (20,22). A notable strength of this study was its prospective design and standardized surgical technique, performed by experienced surgeons, which contributed to consistency in operative management. Additionally, structured follow-up at three, six, and nine months allowed for the assessment of both short- and mid-term functional and radiological outcomes. The findings provide further evidence supporting the use of PHILOS plates as a reliable fixation method for displaced proximal humerus fractures.

However, certain limitations must be acknowledged. The relatively small sample size of 88 patients and the single-center setting limit the generalizability of the results. The follow-up duration of nine months, while adequate for initial healing and functional assessment, does not fully capture long-term outcomes such as late-onset avascular necrosis or implant-related complications, which may develop years after surgery. Furthermore, subgroup analyses according to fracture type, mechanism of injury, or patient comorbidities were not performed, which could have provided additional insights into predictors of functional success or failure. The absence of a comparative group managed with alternative fixation methods or conservative treatment also restricts the ability to evaluate the relative advantages of PHILOS fixation. Overall, the results reaffirm the effectiveness of PHILOS plates in restoring function and achieving reliable fracture healing in proximal humerus fractures, particularly in younger patients with high-energy injuries. Nevertheless, the occurrence of complications underscores the need for meticulous surgical technique, vigilant postoperative monitoring, and structured rehabilitation protocols. Future research should focus on long-term multicenter studies with larger cohorts, stratified analyses by fracture type and patient profile, and direct comparisons with other fixation techniques or prosthetic replacements. Such studies would provide a more comprehensive understanding of the durability, safety, and overall clinical value of PHILOS fixation in different patient populations.

CONCLUSION

The findings of this study demonstrate that the PHILOS plate is an effective option for the surgical management of proximal humerus fractures, providing reliable stability, encouraging fracture healing, and supporting the restoration of functional outcomes. While its use offers significant benefits in terms of mobility and independence, the potential for complications highlights the importance of careful surgical execution, comprehensive postoperative care, and individualized treatment planning. Overall, the PHILOS plate represents a valuable tool in modern orthopedic practice, with the capacity to improve quality of life and functional recovery when applied with precision and patient-centered consideration.

© 2025 et al. Open access under CC BY License (Creative Commons). Freely distributable with appropriate citation.

INSIGHTS-JHR
INSIGHTS-JOURNAL OF HEALTH AND REHABILITATION

AUTHOR CONTRIBUTION

Author	Contribution
Ali Ekram*	Substantial Contribution to study design, analysis, acquisition of Data Manuscript Writing Has given Final Approval of the version to be published
Adeel Ahmed Siddiqui	Substantial Contribution to study design, acquisition and interpretation of Data Critical Review and Manuscript Writing Has given Final Approval of the version to be published
Sunil Kumar	Substantial Contribution to acquisition and interpretation of Data Has given Final Approval of the version to be published
Syed Muhammad Khalid Karim	Contributed to Data Collection and Analysis Has given Final Approval of the version to be published
Muhammad Noman	Contributed to Data Collection and Analysis Has given Final Approval of the version to be published
Mairajuddin	Substantial Contribution to study design and Data Analysis Has given Final Approval of the version to be published
Muhammad Taha Tariq	Contributed to study concept and Data collection Has given Final Approval of the version to be published

REFERENCES

1. Fell I, Tashjian RZ, Schroeder NS. Shoulder Injuries. Orthopaedic Rotations Survival Guide. 2023 Jun 19.
2. Rudran B, Little C, Duff A, Poon H, Tang Q. Proximal humerus fractures: anatomy, diagnosis and management. British J Hosp Med. 2022 Jul 2;83(7):1-0.
3. Brooker-Thompson C, Mohan H, Chotai N, Baring T. Clinical outcomes of a novel 'all-suture'fixation for valgus-impacted proximal humeral fractures. Shoulder & Elbow. 2023 Jun 26:17585732231184208.
4. Davey MS, Hurley ET, Anil U, Condren S, Kearney J, O'Tuile C, et al. Management options for proximal humerus fractures–A systematic review & network meta-analysis of randomized control trials. Injury. 2022 Feb 1;53(2):244-9.
5. Iglesias-Rodríguez S, Domínguez-Prado DM, García-Reza A, Fernández-Fernández D, Pérez-Alfonso E, García-Piñeiro J, et al. Epidemiology of proximal humerus fractures. J Orthop Surg Res. 2021 Dec;16(1):402.
6. Kulkarni R. A study of functional and radiological outcome of complex fracutre dislocation of proximal humerus treated with proximal humeral internal locking system (Philos) plate. Int J Orthop. 2020;6(4):623-8.
7. Poelmann J, Kloen P. Modified use of the proximal humeral internal locking system (PHILOS) plate for distal femoral nonunions. Eur J Orthop Surg Traumatol. 2023 Feb;33(2):425-33.
8. Patel YC, Majumdar S, Shah S, Lathiya H, Bhadani A. Study of outcome of proximal humerus fracture treated with proximal humerus internal locking system (Philos) plating. Inter J Orthop. 2023;9(2):117-26

© 2025 et al. Open access under CC BY License (Creative Commons). Freely distributable with appropriate citation.

9. Gurnani S, Pisal T, Phalak MO, Chaudhari T, Patel S, Yadav P, Mizanur SK. Assessment of surgical outcome in three-and four-part proximal humerus fracture treated with Proximal Humerus Internal Locking System (PHILOS) plate versus Neer's prosthesis in elderly patients. Cureus. 2022 Feb 3;14(2).
10. Oldrini LM, Feltri P, Albanese J, Marbach F, Filardo G, Candrian C. PHILOS synthesis for proximal humerus fractures has high complications and reintervention rates: a systematic review and metaanalysis. Life. 2022;12(2):311.
11. Roy MK, Islam MS, Hossain MZ, Alauddin M, Alam MT, Sarkar TK, et al. Clinical Outcome in Intra Articular Distal Humerus Fractures in Adults Treated with Different Hardware in a Tertiary Level Hospital of Bangladesh. Mymensingh Med J. 2021;30(1):73-8.
12. Boyer P, Couffignal C, Bahman M, Mylle G, Rousseau MA, Dukan R. Displaced three and four part proximal humeral fractures: prospective controlled randomized open-label two-arm study comparing intramedullary nailing and locking plate. Int Orthop. 2021;45(11):2917-26.
13. Den Hartog D, Van Bergen SH, Mahabier KC, Verhofstad MHJ, Van Lieshout EMM. Functional and clinical outcome after operative versus nonoperative treatment of a humeral shaft fracture (HUMMER): results of a multicenter prospective cohort study. Eur J Trauma Emerg Surg. 2022;48(4):3265-77.
14. Den Hartog D, Mahabier KC, Van Bergen SH, Verhofstad MHJ, Van Lieshout EMM. Functional and Clinical Outcomes After Plate Osteosynthesis Versus Intramedullary Nailing of a Humeral Shaft Fracture: The Results of the HUMMER Multicenter, Prospective Cohort Study. J Bone Joint Surg Am. 2023;105(14):1101-11.
15. Oliver WM, Bell KR, Carter TH, Graham C, White TO, Clement ND, et al. Operative vs Nonoperative Management of Fractures of the Humeral Diaphysis: The Humeral Shaft Fracture Fixation Randomized Clinical Trial. JAMA Surg. 2025;160(5):508-16.
16. Bue M, Bright E, Thillemann TM, Mosegaard SB, Hansen TB, Klebe T, et al. Osteoporosis does not affect bone mineral density change in the proximal humerus or the functional outcome after open reduction and internal fixation of unilateral displaced 3- or 4-part fractures at 12-month follow-up. J Shoulder Elbow Surg. 2023;32(2):292-301.
17. Attala D, Primavera M, Di Marcantonio A, Broccolo L, Oliverio FP, Zoccali C, et al. The role of minimally invasive plate osteosynthesis (MIPO) technique for treating 3- and 4-part proximal humerus fractures in the elderly - a case study. Acta Biomed. 2021;92(4):e2021251.
18. Lemsanni M, Chafik R, Madhar M, Elhaoury H, Najeb Y. [Sub- and intercondylar fractures of the distal humerus in adults]. Pan Afr Med J. 2020;36:346.
19. Gupta R, Jung J, Johnston TR, Wright DJ, Uong J, Lim PK, et al. Surgeon-specific factors have a larger impact on decision-making for the management of proximal humerus fractures than patient-specific factors: a prospective cohort study. J Shoulder Elbow Surg. 2023;32(8):1701-9.
20. Cosic F, Kirzner N, Edwards E, Page R, Kimmel L, Gabbe B. The Translated Proximal Humerus Fracture: A Comparison of Operative and Nonoperative Management. J Orthop Trauma. 2023;37(9):e341-e8.
21. Kim BS, Jung KJ, Kim KB, Park SS. Treating AO Type C2-3 Distal Humerus Fractures With the Anconeus Flap Transolecranon Approach. Orthopedics. 2022;45(6):e326-e34.
22. Pavone V, Vescio A, Denaro R, Costa D, Condorelli G, Caruso VF, et al. Use of different devices for surgical treatment of proximal humerus fractures in adults: a systematic review. Acta Biomed. 2021;92(4):e2021198.

© 2025 et al. Open access under CC BY License (Creative Commons). Freely distributable with appropriate citation.