INSIGHTS-JOURNAL OF
HEALTH AND REHABILITATION

INSIGHTS-JHR
INSIGHTS-JOURNAL OF HEALTH AND REHABILITATION

SONOGRAPHIC COMPARISON OF RENAL SEGMENTAL ARTERY TO AORTIC PEAK SYSTOLIC VELOCITY RATIO IN NORMAL AND CHRONIC RENAL PARENCHYMAL DISEASE

Original Research

Kaynat Mustafa[1]*, Iqra Manzoor[2], Raham Bacha[1], Mehreen Fatima[3], Hafiza Maria Fawad[4], Javeria Afzal[1], Sana Kundi[5]
[1]Sonologist, Gillani Ultrasound Center, Chungi Lahore, Pakistan.
[2]Lecturer, University of Lahore, Pakistan.
[3]Associate Professor, University of Lahore, Pakistan.
[4]Green international University, Lahore, Pakistan.
[5]Senior Consultant, Pakistan Kidney and Liver Institute, Lahore (PKLI), Pakistan.
Corresponding Author: Kaynat Mustafa, Sonologist, Gillani Ultrasound Center, Chungi Lahore, Pakistan, mariafawad05@gmail.com
Acknowledgement: The authors gratefully acknowledge the support of the Department of Radiology, PKLI&RC Lahore, for facilitating this study.

Conflict of Interest: None
Grant Support & Financial Support: None

ABSTRACT

Background: Chronic renal parenchymal disease is a progressive condition characterized by the gradual loss of kidney function. It contributes significantly to global morbidity and mortality. According to the Global Burden of Disease study, chronic kidney disease ranked 27th among causes of global deaths in 1990, rising to 18th by 2010, with an age-standardized death rate of 16.3 per 100,000. Early detection through non-invasive imaging can play a pivotal role in slowing disease progression and preventing complications.

Objective: To assess the sonographic comparison of the renal segmental artery to aortic peak systolic velocity (PSV) ratio in healthy individuals and patients with chronic renal parenchymal disease using Doppler ultrasound.

Methods: This cross-sectional study was conducted over five months, from September 2019 to January 2020, at the Department of Radiology, Pakistan Kidney and Liver Institute & Research Center (PKLI&RC), Lahore. A total of 168 patients were enrolled using convenient sampling, including 84 patients diagnosed with chronic renal parenchymal disease and 84 with normal renal function. All participants underwent grayscale and Doppler ultrasonography using Toshiba Aloka Prosound SSD-3500SX with 3.5 MHz curvilinear and 7.5 MHz linear probes. Renal segmental artery and aortic PSV measurements were recorded and compared.

Results: Among 168 participants, the mean age was 42.08 ± 14.52 years in the disease group and 45.36 ± 10.02 years in the normal group. The mean renal segmental artery to aortic PSV ratio was 0.4583 ± 0.19789 in patients with chronic renal parenchymal disease and 0.6206 ± 0.23015 in normal subjects. Of the diseased group, 64.6% were male and 36.0% female. Comorbid conditions included hypertension (69.0%), diabetes mellitus (64.3%), edema (38.1%), anemia (21.4%), pain (14.3%), and fever (14.3%).

Conclusion: Sonographic assessment, particularly Doppler-based evaluation of renal segmental artery to aortic PSV ratio, offers a reliable, non-invasive method for detecting and monitoring chronic renal parenchymal disease. It aids in early diagnosis, potentially preventing further renal deterioration and associated complications.

Keywords: Aorta, Chronic Kidney Disease, Color Doppler Ultrasonography, Kidney Failure, Peak Systolic Velocity, Renal Artery, Renal Parenchymal Disease.

© 2025 et al. Open access under CC BY License (Creative Commons). Freely distributable with appropriate citation.

INTRODUCTION

Renal parenchymal disease represents a chronic, progressive deterioration in kidney function, typically characterized by a decline in glomerular filtration rate (GFR), increased urinary albumin excretion, or both. The kidneys play a central role in maintaining homeostasis by filtering toxins and excess fluid from the blood, excreting them through urine (1). Anatomically, each kidney is composed of a cortex and medulla, which function in unison to ensure the excretion of metabolic waste. When these organs fail to operate efficiently, nitrogenous wastes and excess fluids accumulate in the bloodstream, precipitating a cascade of systemic complications (2). Often, the initial stages of chronic kidney disease (CKD) progress silently, delaying diagnosis until renal impairment becomes significant. Early detection, therefore, is critical in slowing the progression of the disease and minimizing associated risks, particularly those related to cardiovascular morbidity and mortality (3,4). Global health data underscore the growing burden of CKD. The Global Burden of Disease Study ranked CKD as the 27th leading cause of mortality worldwide in 1990, rising to 18th by 2010, with an age-standardized death rate increasing from 15.7 to 16.3 per 100,000 people annually (5). Among the leading contributors to this rise were HIV/AIDS and diabetes mellitus, with CKD being one of the most significant causes of premature mortality. Notably, studies in the United States and Australia revealed that many patients who succumbed to diabetes-related complications had undiagnosed renal failure, suggesting an underestimation of CKD-related mortality in national records (6,7). CKD is now recognized as a global public health crisis, with a steadily rising incidence of end-stage renal disease (ESRD) and associated complications. Despite the disease's silent onset, its progression is not inevitable. With appropriate screening strategies and early therapeutic interventions, many of its complications can be prevented (8).

Public health policies emphasizing early diagnosis, particularly in patients with comorbidities such as diabetes and hypertension, have shown promise in curbing its impact. In India, the estimated prevalence of CKD is about 150–200 cases per 800 per million population, with diabetes and hypertension as the leading etiological factors (9). Similarly, in Japan, CKD affects an estimated 6–13 million individuals, and its progression to ESRD and cardiovascular disease places a considerable burden on healthcare systems. Proactive measures focusing on early intervention, lifestyle modifications, and routine nephrological evaluations are being advocated to mitigate this trend (10). Sonographic assessment has emerged as a non-invasive, valuable diagnostic modality for evaluating renal morphology and hemodynamics in patients with CKD. Key ultrasound parameters such as renal length, parenchymal thickness, cortical thickness, and cortical echogenicity provide insights into the extent of renal damage (11). Moreover, the measurement of segmental renal artery velocities and their ratios relative to aortic peak systolic velocity offers a promising avenue for differentiating between normal and diseased renal states. These indices reflect renal vascular resistance and perfusion status and may serve as early indicators of renal impairment even before overt changes in serum creatinine or GFR become apparent. Given the escalating burden of CKD and the limitations of conventional markers in detecting early disease, there is a pressing need to explore and validate newer diagnostic approaches. In this context, the present study aims to assess the sonographic comparison of renal segmental artery to aortic peak systolic velocity ratio in healthy individuals and patients with chronic renal parenchymal disease through Doppler ultrasonography, with the objective of enhancing early diagnostic accuracy and guiding timely therapeutic interventions.

METHODS

The present study was conducted in the Department of Radiology at Pakistan Kidney and Liver Institute & Research Center (PKLI&RC), Lahore, over a duration of five months, following the approval of the research synopsis. Employing a cross-sectional study design, the sampling technique used was non-probability convenience sampling. A total of 168 adult patients were enrolled, equally divided into two groups: one comprising 84 individuals with normal renal parenchyma and the other comprising 84 patients diagnosed with chronic renal parenchymal disease (CRPD). Among those with normal sonographic findings, 55 were female and 29 were male, while in the CRPD group, 31 were female and 53 were male. All participants underwent standardized sonographic evaluation using a Toshiba Aloka ProSound SSD-3500SX ultrasound machine. Imaging was performed using two probes: a curvilinear transducer with a frequency of 3.5 MHz for deeper abdominal imaging and a high-frequency linear probe of 7.5 MHz for cortical assessment and vascular structures. Grayscale sonography was used to evaluate renal length (measured in the sagittal plane from upper to lower pole), parenchymal thickness (measured from the renal hilum to the outer boundary), and cortical thickness (measured from the base of the medullary pyramid to the

© 2025 et al. Open access under CC BY License (Creative Commons). Freely distributable with appropriate citation.

INSIGHTS-JHR
INSIGHTS-JOURNAL OF HEALTH AND REHABILITATION

renal capsule). Cortical echogenicity was assessed relative to the liver and medulla, and corticomedullary differentiation was graded into five levels based on standard sonographic criteria.

Doppler ultrasonography was used to assess renal vascularity. Peak systolic velocity (PSV) of the renal segmental artery was measured and compared with the aortic PSV to calculate the renal segmental artery to aortic PSV ratio. These hemodynamic parameters were used to evaluate renal perfusion differences between the normal and CRPD groups. Inclusion criteria included adults aged 18 to 85 years who provided informed written consent and had no contraindications to sonographic examination. Patients were excluded if they had a solitary kidney, congenital anomalies, obstructive uropathy, renal masses, or previously diagnosed renal artery stenosis, as such conditions could distort the anatomical and vascular assessment of the kidneys (12-14). Ethical approval for the study was obtained from the Institutional Ethics Committee of PKLI&RC, ensuring compliance with research ethics and participant safety. Informed consent was obtained from all participants prior to inclusion in the study. Data was anonymized, and confidentiality was strictly maintained, with access restricted to the research team.

RESULTS

The study included 168 patients, evenly divided into two groups: 84 individuals with chronic renal parenchymal disease and 84 with normal renal function. Among the disease group, there were 53 males and 31 females, whereas the normal group comprised 29 males and 55 females. The age range of participants was 25 to 85 years. The mean age of patients with chronic renal parenchymal disease was 42.08 years with a standard deviation of 14.52, while the mean age among those with normal kidneys was 45.36 years with a standard deviation of 10.02. The primary variable of interest, the renal segmental artery to aortic peak systolic velocity (PSV) ratio, demonstrated a clear distinction between the two groups. In patients with chronic renal parenchymal disease, the mean ratio was 0.4583 with a standard deviation of 0.19789. In contrast, patients with normal renal parenchyma had a significantly higher mean ratio of 0.6206 with a standard deviation of 0.23015. Regarding associated clinical features observed on ultrasound, hypertension was reported in 69.0% of patients, followed by diabetes mellitus in 64.3%. Edema was noted in 38.1% of patients, anemia in 21.4%, while fever and pain were each reported in 14.3% of cases. These findings indicate that hypertension and diabetes were the most common comorbidities in individuals with abnormal renal parenchymal findings. The comparison of the renal segmental artery to aortic peak systolic velocity (PSV) ratio between patients with and without chronic renal parenchymal disease revealed a statistically significant difference. An independent samples t-test was performed to evaluate the difference in mean PSV ratios between the two groups. The test yielded a p-value of <0.001 ($p = 3.46 \times 10^{-10}$), indicating that the lower mean PSV ratio observed in the chronic renal parenchymal disease group (mean = 0.4583, SD = 0.19789) compared to the normal group (mean = 0.6206, SD = 0.23015) was statistically significant. This significant difference supports the diagnostic utility of the renal segmental artery to aortic PSV ratio as a potential non-invasive marker for evaluating chronic renal parenchymal disease.

Table 1: Gender Distribution in Study Groups

Gender	Chronic Renal Parenchymal Disease (n = 84)	Normal Renal Function (n = 84)	Total (N = 168)
Male	53	29	82
Female	31	55	86

Table 2: Age Statistics in Study Groups

Group	Mean Age (years)	Standard Deviation	Minimum Age	Maximum Age
Chronic Renal Parenchymal Disease	42.08	14.52	25	85
Normal Renal Function	45.36	10.02	25	85

Table 3: Renal Segmental Artery to Aortic PSV Ratio Comparison

	Disease	N	Mean	Std. Deviation	Std. Error Mean
Renal segmental artery to Aortic PSV ratio	Disease	84	.4583	.19789	.02159
	Normal	84	.6206	.23015	.02511

© 2025 et al. Open access under CC BY License (Creative Commons). Freely distributable with appropriate citation.

Table 4: Frequency of Associated Sonographic Clinical Findings

Sonographic findings	Frequency	Percent
Hypertension	58	69.0
Diabetes	54	64.3
Fever	12	14.3
Edema	32	38.1
Anemia	18	21.4
Pain	12	14.3

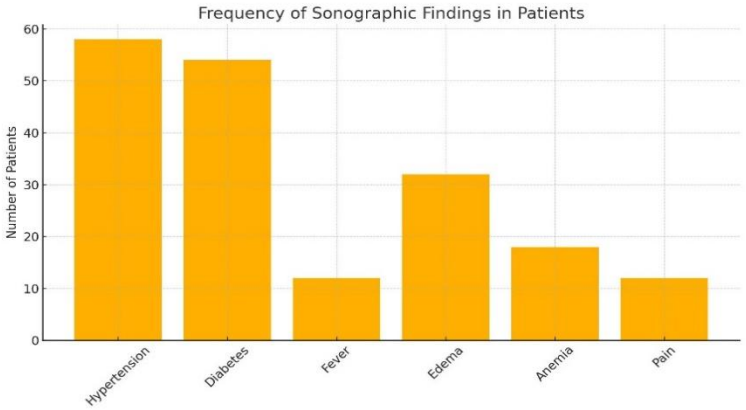

Figure 1 Frequency of Sonographic Findings in Patients

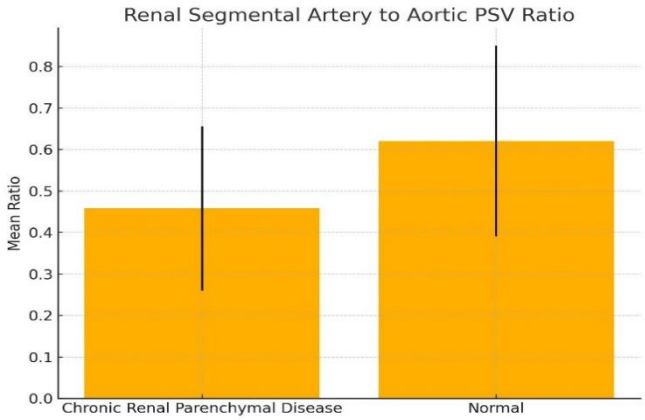

Figure 2 Renal Segmental Aortic PSV Ratio

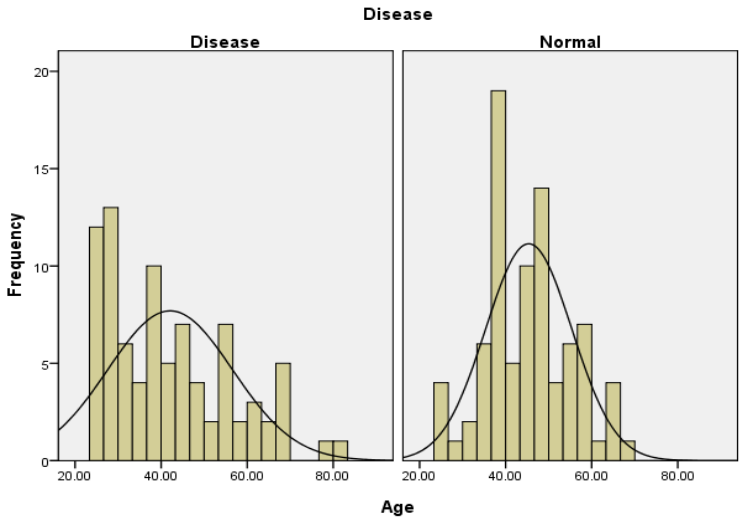

Figure 3 Graphical presentation of age in diseased and normal patients

DISCUSSION

This study aimed to evaluate the sonographic comparison of the renal segmental artery to aortic peak systolic velocity (PSV) ratio in individuals with and without chronic renal parenchymal disease. The findings revealed that patients with chronic renal parenchymal disease demonstrated significantly lower PSV ratios compared to individuals with normal renal function, suggesting that this Doppler

© 2025 et al. Open access under CC BY License (Creative Commons). Freely distributable with appropriate citation.

INSIGHTS-JHR
INSIGHTS-JOURNAL OF HEALTH AND REHABILITATION

parameter could serve as a valuable non-invasive indicator of renal impairment. The results were statistically significant, reinforcing the utility of sonographic vascular indices in the early detection of chronic kidney pathology. In terms of demographic distribution, the study found a higher prevalence of chronic renal parenchymal disease in males (64.6%) compared to females (36.0%). This pattern aligned with some regional studies that reported male predominance; however, it differed from other research that suggested higher prevalence rates in females (15,16). Such discrepancies may stem from differences in muscle mass influencing serum creatinine levels, population-based lifestyle factors, or healthcare-seeking behaviors. Notably, other researchers have observed that while chronic kidney disease is often more prevalent in females, disease progression and the severity of end-stage renal disease tend to be more pronounced in males (17,18). The age distribution in this study showed that most cases of chronic renal parenchymal disease occurred between 30 and 40 years of age. This contrasted with studies that reported peak prevalence in older populations, particularly those aged 60 and above, as well as reports of early onset in young adults between 20 and 30 years in certain geographical settings (19,20). These findings highlight potential regional and socioeconomic differences in disease onset and underscore the need for early screening strategies, especially in high-risk populations.

Clinically, hypertension and diabetes mellitus were the most frequently associated comorbidities in patients with chronic renal parenchymal disease, affecting 69.0% and 64.3% of the cases, respectively. This supports previous findings indicating that hypertension and diabetes are not only highly prevalent among chronic kidney disease patients but also major contributors to disease progression and end-stage renal disease. Literature widely acknowledges the bidirectional relationship between chronic kidney disease and hypertension, where each condition accelerates the other (11,21). Likewise, diabetes mellitus, especially type 2, has been consistently implicated in the pathogenesis of diabetic nephropathy and is considered a primary risk factor for the progression to end-stage renal failure (15,22). In terms of presenting symptoms, only 14.3% of patients in the disease group reported pain, indicating the predominantly asymptomatic nature of early to moderate chronic renal parenchymal disease. However, other reports have shown a higher prevalence of moderate to severe pain among chronic kidney disease patients, often due to poor pain management or coexisting conditions (23). The variation in symptom presentation further emphasizes the importance of routine imaging and laboratory evaluation, as reliance on clinical symptoms alone may delay diagnosis.

The strength of this study lies in its use of a standardized sonographic protocol to assess both anatomical and hemodynamic parameters of renal function. The inclusion of Doppler indices such as the renal segmental artery to aortic PSV ratio offers a reproducible, non-invasive diagnostic approach that can complement biochemical testing, particularly in settings with limited access to advanced renal function assays. Nonetheless, the study has certain limitations. The sampling was non-probabilistic and limited to a single tertiary care center, which may restrict generalizability. The cross-sectional design also limits causal inference. In addition, potential confounding factors such as medication use, duration of comorbidities, and body mass index were not accounted for in the analysis. Future studies should incorporate a multicenter design with longitudinal follow-up, stratify disease severity, and explore the influence of additional clinical variables on Doppler findings. In conclusion, this study reinforces the clinical value of Doppler ultrasound in detecting chronic renal parenchymal disease and underscores the significance of comorbid hypertension and diabetes as major contributing factors. Integrating sonographic assessments with routine screening in at-risk populations may enhance early detection and timely intervention, ultimately reducing the burden of renal morbidity and mortality.

CONCLUSION

Ultrasonography, particularly with the use of Doppler imaging, serves as a vital non-invasive tool in the initial evaluation and ongoing monitoring of patients with chronic renal parenchymal disease. This study highlights the significance of measuring the renal segmental artery to aortic peak systolic velocity ratio as a reliable sonographic parameter in distinguishing diseased from normal renal parenchyma. The ability to detect early vascular changes through Doppler assessment offers a meaningful opportunity to guide timely clinical interventions, potentially preventing further renal deterioration and associated complications. These findings support the integration of sonographic evaluation into routine diagnostic protocols for high-risk patients, emphasizing its practical value in the prevention and management of chronic kidney disease.

© 2025 et al. Open access under CC BY License (Creative Commons). Freely distributable with appropriate citation.

INSIGHTS-JHR
INSIGHTS-JOURNAL OF HEALTH AND REHABILITATION

AUTHOR CONTRIBUTION

Author	Contribution
Kaynat Mustafa*	Substantial Contribution to study design, analysis, acquisition of Data Manuscript Writing Has given Final Approval of the version to be published
Iqra Manzoor	Substantial Contribution to study design, acquisition and interpretation of Data Critical Review and Manuscript Writing Has given Final Approval of the version to be published
Raham Bacha	Substantial Contribution to acquisition and interpretation of Data Has given Final Approval of the version to be published
Mehreen Fatima	Contributed to Data Collection and Analysis Has given Final Approval of the version to be published
Hafiza Maria Fawad	Contributed to Data Collection and Analysis Has given Final Approval of the version to be published
Javeria Afzal	Substantial Contribution to study design and Data Analysis Has given Final Approval of the version to be published
Sana Kundi	Contributed to study concept and Data collection Has given Final Approval of the version to be published

REFERENCES

1. Fujioka H, Yamazaki H, Imamura T, Koike T, Arisawa Y, Murai S, et al. Arterioureteral fistula and refractory fatal pseudo-aneurysm in a patient receiving kidney transplantation. CEN Case Rep. 2025;14(1):16-23.
2. Wen TC, Lin KH, Chiu PF, Lin KS, Lee CW, Chan CP. Bilateral spontaneous massive renal hemorrhage in a peritoneal dialysis patient: A case report. Medicine (Baltimore). 2021;100(44):e27549.
3. Ewing EC, Edwards AR. Cardiovascular Disease Assessment Prior to Kidney Transplantation. Methodist Debakey Cardiovasc J. 2022;18(4):50-61.
4. Lu S, Robyak K, Zhu Y. The CKD-EPI 2021 Equation and Other Creatinine-Based Race-Independent eGFR Equations in Chronic Kidney Disease Diagnosis and Staging. J Appl Lab Med. 2023;8(5):952-61.
5. Spanos K, Nana P, Brotis AG, Kouvelos G, Behrendt CA, Tsilimparis N, et al. Clinical effect of accessory renal artery coverage after endovascular repair of aneurysms in abdominal and thoracoabdominal aorta. J Vasc Surg. 2021;74(6):2104-13.e7.
6. Favero M, Quintella DC, Fernandes NC. Dermatosis in dialytic chronic kidney failure. J Bras Nefrol. 2022;44(4):585-6.
7. de Freminville JB, Vernier LM, Roumy J, Patat F, Gatault P, Sautenet B, et al. Early changes in renal resistive index and mortality in diabetic and nondiabetic kidney transplant recipients: a cohort study. BMC Nephrol. 2021;22(1):62.
8. Ruiz-Carmona C, Mateos Torres E. Early Kidney Transplant Dysfunction with Renal Artery Torsion: A Surgical Emergency. Eur J Vasc Endovasc Surg. 2020;60(5):686.
9. Marin-Castro P, Waisberg DR, Rocha-Santos V, Pinheiro RS, Martino RB, Ducatti L, et al. En Bloc Simultaneous Liver-Kidney Transplantation Compared to the Traditional Technique: Results From a Single Center. Transplant Proc. 2024;56(5):1104-9.
10. Martin-Taboada M, Vila-Bedmar R, Medina-Gómez G. From Obesity to Chronic Kidney Disease: How Can Adipose Tissue Affect Renal Function? Nephron. 2021;145(6):609-13.

© 2025 et al. Open access under CC BY License (Creative Commons). Freely distributable with appropriate citation.

11. Nguefouet Momo RE, Donato P, Ugolini G, Nacchia F, Mezzetto L, Veraldi GF, et al. Kidney transplantation from living donor with monolateral renal artery fibromuscular dysplasia using a cryopreserved iliac graft for arterial reconstruction: a case report and review of the literature. BMC Nephrol. 2020;21(1):451.
12. Stafforini NA, Czerwonko ME, Singh N, Quiroga E, Starnes BW. Management of an Aortoenteric Fistula in a Patient with End Stage Renal and Liver Disease, Prior Endovascular Aortic Repair With Type II Endoleak. Vasc Endovascular Surg. 2021;55(7):752-5.
13. Li H, Lin YC, Kao CC, Chiang PJ, Chou MH, Ting HK, et al. A Novel Hybrid Approach to Manage Mycotic Pseudoaneurysm Post-Renal Transplantation: Successful Graft Preservation. Medicina (Kaunas). 2025;61(3).
14. Sun X, O'Neill S, Noble H, Zeng J, Tuan SC, McKeaveney C. Outcomes of kidney replacement therapies after kidney transplant failure: A systematic review and meta-analysis. Transplant Rev (Orlando). 2024;38(4):100883.
15. Janse RJ, van Diepen M, Ramspek CL. Predicting Kidney Failure With the Kidney Failure Risk Equation: Time to Rethink Probabilities. Am J Kidney Dis. 2023;82(4):381-3.
16. Oktan MA, Sarioglu O, Heybeli C, Ozdemir E, Atay I, Korucu B, et al. Predictors of kidney disease progression after renal artery stenting. BMC Nephrol. 2025;26(1):175.
17. Lee HJ, Son YJ. Prevalence and Associated Factors of Frailty and Mortality in Patients with End-Stage Renal Disease Undergoing Hemodialysis: A Systematic Review and Meta-Analysis. Int J Environ Res Public Health. 2021;18(7).
18. Boudhabhay I, Delestre F, Coutance G, Gnemmi V, Quemeneur T, Vandenbussche C, et al. Reappraisal of Renal Arteritis in ANCA-associated Vasculitis: Clinical Characteristics, Pathology, and Outcome. J Am Soc Nephrol. 2021;32(9):2362-74.
19. Bikauskaitė S, Počepavičiūtė K, Velička L, Jankauskas A, Trumbeckas D, Šuopytė E. Reconstruction of a Lower Polar Artery for Kidney Transplantation Using Donor Ovarian Vein: Case Report with Literature Review. Medicina (Kaunas). 2021;57(11).
20. Morimoto K, Matsui M, Samejima K, Kanki T, Nishimoto M, Tanabe K, et al. Renal arteriolar hyalinosis, not intimal thickening in large arteries, is associated with cardiovascular events in people with biopsy-proven diabetic nephropathy. Diabet Med. 2020;37(12):2143-52.
21. Thakare DR, Mishra P, Rathore U, Singh K, Dixit J, Qamar T, et al. Renal artery involvement is associated with increased morbidity but not mortality in Takayasu arteritis: a matched cohort study of 215 patients. Clin Rheumatol. 2024;43(1):67-80.
22. Nerli RB, Patil MV, Kadeli V, Bokare A, Setya N, Saldanha R, et al. Renal Transplant in a Child With the Donor Kidney Having 2 Renal Arteries. Exp Clin Transplant. 2024;22(8):647-9.
23. Montali F, Panarese A, Binda B, Lancione L, Pisani F. Transplant Renal Artery Stenosis: A Case Report of Functional Recovery Six Months After Angioplasty. Transplant Proc. 2021;53(4):1272-4.

© 2025 et al. Open access under CC BY License (Creative Commons). Freely distributable with appropriate citation.